

## Evaluation of Distraction Osteogenesis by Ilizarov Ring Fixator for Hypertrophic Nonunion of Tibia with Shortening and Deformity

Arifuzzaman M<sup>1\*</sup>, Mostafa DG<sup>2</sup>, Haque MM<sup>3</sup>, Rahman MM<sup>4</sup>, Maula MJ<sup>5</sup>, Islam MR<sup>6</sup>

<sup>1</sup>Dr. Md. Arifuzzaman, Junior Consultant (Orthopaedics), Kushtia Medical College Hospital, Kushtia, Bangladesh

<sup>2</sup>Dr. Abu Daud Md. Golam Mostafa, Senior Consultant (Orthopaedics), District Hospital, Gaibandha, Bangladesh

<sup>3</sup>Dr. Md. Mahafil Haque, Assistant Professor, Department of Orthopaedics, M. Abdur Rahim Medical College, Dinajpur, Bangladesh

<sup>4</sup>Dr. Md. Mahbubur Rahman, Residential Surgeon (Orthopaedics), M. Abdur Rahim Medical College Hospital, Dinajpur, Bangladesh

<sup>5</sup>Dr. Mustari Jahan Maula, Anaesthesiologist, Rangpur Medical College Hospital, Rangpur, Bangladesh

<sup>6</sup>Dr. Md. Rabiul Islam, Junior Consultant (Orthopaedics), Rangpur Medical College Hospital, Rangpur, Bangladesh

DOI: [10.36347/sasjs.2021.v07i06.009](https://doi.org/10.36347/sasjs.2021.v07i06.009)

| Received: 22.04.2021 | Accepted: 30.05.2021 | Published: 17.06.2021

\*Corresponding author: Dr. Md. Arifuzzaman

### Abstract

### Original Research Article

**Background:** Hypertrophic nonunion often develops due to improper fracture immobilization or failed internal fixation. Gross mobility at the fracture site interferes with the normal healing process with the formation of fibrocartilage, which fails to mature into solid callus. **Aim of the study:** The aim of this study was to evaluate distraction osteogenesis by ilizarov ring fixator for hypertrophic nonunion of tibia with deformity and shortening. **Methods:** This was a quasi-experimental study conducted at National Institute of Traumatology & Orthopaedic Rehabilitation (NITOR), Dhaka, Bangladesh in the period from June 2011 to December 2012. Study population were all the patients with hypertrophic nonunion of tibia with shortening and deformity, attending out-patient department in NITOR. A total of 10 patients were included for evaluation from which 8 patients were selected using purposive sampling method. Surgery was with detailed preoperative x-ray analysis and measurement of magnitude of deformity and LLD. Other necessary investigations were done if clinically indicated and to prepare the patient for anesthesia. Statistical analysis of the results was obtained by using window-based computer software devised with Statistical Packages for Social Sciences (SPSS-22). **Results:** The mean age of patients was 32.62 years and the lowest and the highest ages were 14 and 55 years respectively. Type of deformity out of 08 patients, 07 patients had only angulation deformity and 01 had angulation translation deformity. Distribution of patients with the Plane of deformity reflects that 2 patients had sagittal plane and 6 had oblique plane. **Conclusion:** As the outcome evaluation was done 5-11 months after operation, changes in outcome beyond 3-11 months like Knee, ankle arthritis and symptom status, recurrence of deformity, collapse of lengthen segment could not be ascertained.

**Keywords:** Hypertrophic, Nonunion, Tibia, Ilizarov Ring Fixator.

Copyright © 2021 The Author(s): This is an open-access article distributed under the terms of the Creative Commons Attribution 4.0 International License (CC BY-NC 4.0) which permits unrestricted use, distribution, and reproduction in any medium for non-commercial use provided the original author and source are credited.

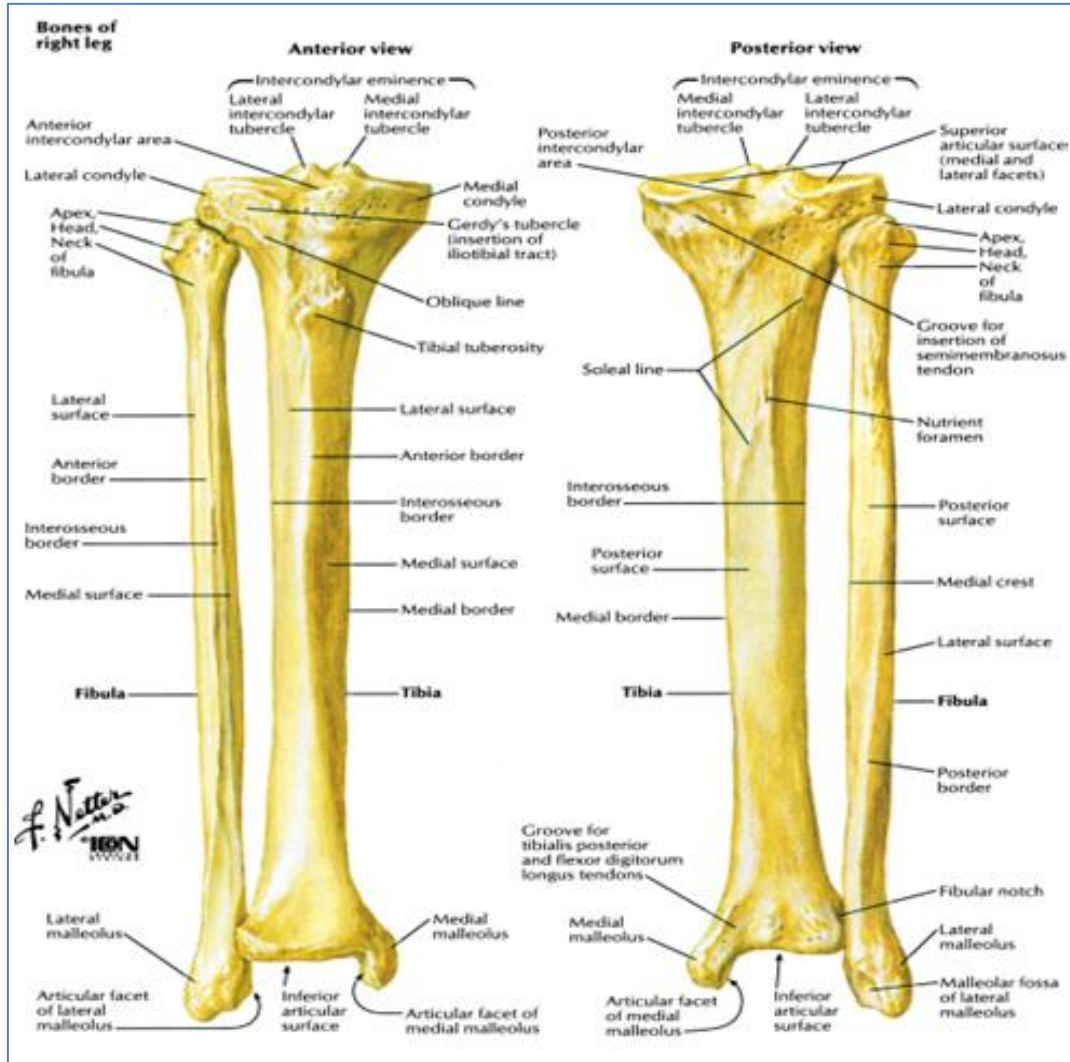
## INTRODUCTION

Fracture of the long bones can now be treated successfully in majority of patients, yet nonunion are not uncommon. They may result in significant morbidity, require numerous operative procedures to treat and leave the patient functional deficit. Nonunion is estimated to occur after 2% to 15% of all tibia fractures. The development of a tibia nonunion is closely related to the type and severity of the injury, but other factors may play a role, such as degree of fracture comminution, open fracture, degree of soft-tissue injury, medical comorbidities, and patient lifestyle (tobacco use, nutritional status, medications). Subsequent complications, such as infection or compartment syndrome, also may affect healing of the

fracture. Compared to other alternatives such as the Ilizarov method requires only one surgical procedure and appears to have fewer complications. Additionally, the Ilizarov procedure allows for simultaneous correction of multiple deformities, early movement of adjacent joints, as well as early weight bearing [1]. Distraction osteosynthesis refers to a technique in which a limb is gradually lengthened at a controlled rate across the osteotomy site. The original limb lengthening procedure was first described in the English orthopedic literature by Codvilla [2]. In the 1960s, the Wagner method (limb lengthening with cancellous bone grafting and plating of the distraction gap) was introduced into North America, and became the mainstay of limb lengthening in the United States for many years. The

distraction rate is traditionally set at 1.5 to 2 mm per day. Following attainment of the desired distraction length, iliac crest cancellous bone is grafted into the diastasis in a second operation. The affected bone is plated, and the external distractor is removed. The operated limb does not bear weight for an extended

period of time to allow for incorporation of the graft. In a third operation, the plate is removed, and the subject is put on protective weight bearing [3, 4] The Ilizarov device can address every aspect of a stiff hypertrophic nonunion, including shortening and deformity.



**Fig-I: Osteology of tibia, fibula**

Hypertrophic nonunion usually result from insufficient fracture stabilization. The nonunion tissue and the environment are well vascularized, but the biologic process to union is inhibited by lack of stability. Numerous options to treat nonunion. But everyone is associated with complication. Intramedullary devices give stability but operative procedure can damage the most favorable vascular environment that is at nonunion site. Furthermore, it cannot address the entire problem like shortening and deformity. The magnitude of acute deformity correction that can be tolerated by neurovascular structures is not a set amount. The amount of stretch that the nerve undergoes after angular correction increase linearly with the radial distance from the angular correction axis. Angulation less than 30 deg. is usually considering

safe for acute correction. The same statement is applicable for other type of internal fixation. Furthermore, rate of union, infection can be another frustrating episode for patient and surgeon. Treatment like BMP, various purified factors not yet well established and cannot address all therapeutic need in hypertrophic nonunion. Ilizarov ring fixator in all sense is versatile and effective as it does not disturb the vascular environment at nonunion site. Missing component of healing that is stability is provided adequately by ilizarov ring fixator and can address deformity and shortening. Distraction in hypertrophic nonunion removes need of corticotomy for addressing shortening and gives an excellent relieve from further procedure even from chances of complications.

## OBJECTIVES

The aim of this study was to evaluate outcome of Distraction osteogenesis by ilizarov ring fixator for hypertrophic nonunion of tibia with deformity and shortening.

## METHODS

This was a quasi-experimental study conducted at National Institute of Traumatology & Orthopaedic Rehabilitation (NITOR), Dhaka, Bangladesh in the period from June 2011 to December 2012. Study population were all the patients with hypertrophic nonunion of tibia with shortening and deformity, attending out-patient department in NITOR. A total of 10 patients were included for evaluation from which 8 patients were selected using purposive sampling method. Surgery was with detailed preoperative x-ray analysis and measurement of magnitude of deformity and LLD. Inclusion criteria were: established stiff hypertrophic nonunion (< 5 Deg. Motion) more than 12 months' old, Deformity and shortening, Radiology shows broad bone end and Immobile nonunion in clinical examination. Patients with gap nonunion, Pathological fracture, Fracture nonunion with implant in situ, Hypertrophic nonunion with joint mal orientation and Fracture with discharging sinus were excluded. Other necessary investigations were done if clinically indicated and to prepare the patient for anesthesia. Statistical analysis of the results was obtained by using window-based computer software devised with Statistical Packages for Social Sciences (SPSS-22).

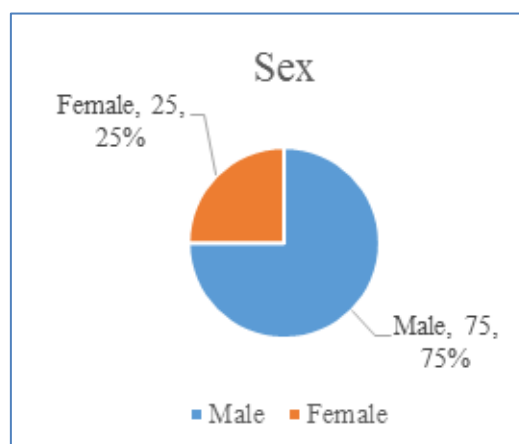
## RESULTS

Table I shows the mean age of patients was 32.62 years and the lowest and the highest ages were 14 and 55 years respectively. Out of total patients 75% were male and 25% were female (Figure II). The occupation status of the studied patients. Three (3) patients were construction worker, and the rest 5 patient's occupation was day laborer, student, garment worker, electrician and retired service holder (Table II). Patient's type of fracture shows half (50%) of the patients had closed fracture, 25% had open and the rest 25% were not classified (Table III). Type of deformity shows (Table IV) out of 08 patients, 07 patients had only angulation deformity and 01 had angulation translation deformity. Distribution of patients with the Plane of deformity shown in Table IV reflects that 2 patients had sagittal plane and 6 had oblique plane. Distribution of patients Duration of nonunion is shown in Figure III. Distribution magnitude of angulation in oblique plane (Table V) showed 7 cases had 16 mm translation in oblique plane. Again in Table VI it is shown that, 7 cases had translation in oblique plane and which was corrected to acceptable limit. In terms of complication (Figure IV), 1 (6.66%) of the patients Pin track infection noticed and 3 patients (20%) developed breakage of wire/ wire fixation bolt. Final clinical outcome (Figure V) shows 87.55% had satisfactory

(Excellent + Good) result and 12.55% had unsatisfactory (Fair + Poor) result.

**Table-I: Demonstration and distribution of the study according to Age (n=08).**

Age	n=8	%
11 years to 20 years	1	12.5
21 years to 30 years	3	37.5
31 years to 40 years	2	25.0
41 years to 50 years	1	12.5
51 years to 60 years	1	12.5
Mean age	32.62 years	
Range	15-55 years	



**Fig-I: Sex distribution of the patients (n=08)**

**Table II: Occupation of the patients (n=08)**

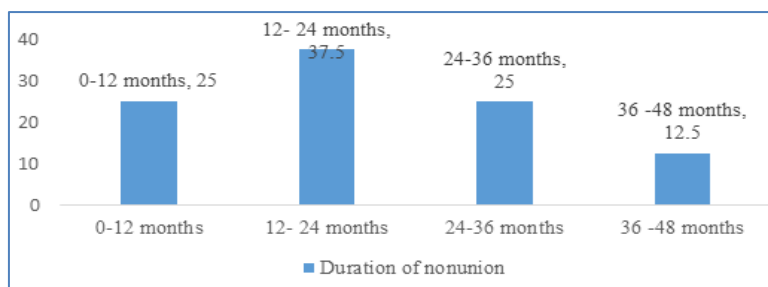
Occupation	Number of patients	Percentage
Day laborer	01	12.5
Student	01	12.5
Garments worker	01	12.5
Construction worker	03	37.5
Electrician	01	12.5
Retired service holder	01	12.5

**Table-III: Distribution of patient's type of fracture**

Type of fracture	Frequency	Percentage
Closed	04	50
Open	02	25
Not classified	02	25

**Table-IV: Distribution of patients with the type and plan of deformity (n=08)**

Type of deformity	n=8	%
Angulation	07	87.5
Angulation-translation	01	12.5
Angulation- rotation	00	00
<b>Plane of deformity</b>		
Sagittal plane (Antecurvation / recurvation)	2	25
Oblique plane	6	75




**Fig-II: Distribution of the patients Duration of nonunion**

**Table-V: Distribution magnitude of angulation in oblique plane**

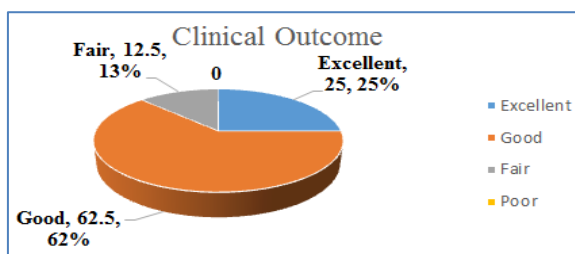
Case no.	Sagittal plane angulation	Sagittal plane angulation range	Sagittal plane angulation mean	Frontal plane angulation	Frontal plane Angulation range	Frontal plane Angulation mean	Oblique plane angulation	Oblique plane angulation range	Oblique plane angulation mean
1	26	21-32	26.66	21	16-27	24.66	33.42	32-46	36.81
2	29			25			38.28		
5	27			37			45.80		
6	21			28			35		
7	25			21			32.64		
8	32			16			35.77		

**Table-VI: Distribution of Post-Operative Magnitude of angulation (deg.) at final follows up**

Case no.	Sagittal plane angulation	Sagittal plane angulation range	Sagittal plane angulation mean	Frontal plane angulation	Frontal plane Angulation range	Frontal plane Angulation mean	Oblique plane angulation	Oblique plane angulation range	Oblique plane angulation mean
1	09	7.66	05-09	04	04-09	5.5	9.84	8-11	9.59
2	08			05			9.43		
5	08			05			9.43		
6	06			09			10.82		
7	08			05			9.43		
8	07			05			8.60		



**Fig-III: Frequency of Incidence of Complications**



**Fig-IV: Final Clinical Outcome**

**DISCUSSION**

Hypertrophic changes at the nonunion site indicate that it has a callus forming capacity and an adequate mechanical environment is needed to allow maturation of the Fibrocartilage and solid callus

formation.<sup>5-10</sup> Traditional treatment methods have focused on achieving rigid fixation of the nonunion for consolidation of the nonunion to occur. Different internal fixation methods have been employed; this included intramedullary nail and plate fixation through open or percutaneous techniques [10-13]. This current study consists of non-randomized clinical trial of 06 male and 02 female patients treated for stiff hypertrophic nonunion with the Ilizarov distraction device at NITOR. The average age of the patients was 32.6 years (range 15–55 years). In a study [14] on 10 male and 6 female patients treated for stiff hypertrophic nonunion with the Ilizarov distraction method, the average age of the patients was 42.3 years (range 15–69 years). Though lacking of proper medical document, it is found in our study that most of the patient treated previously by open reduction internal fixation several times even external fixation. In our study 02 cases had sagittal plane deformity and 06 cases had oblique plane deformity. Pre-operative magnitude of sagittal plane deformity was average 23 deg. And mean pre-operative oblique plane deformity was 36.81 deg and post-operative mean oblique plane deformity was 9.59 deg and average angulation corrected in oblique plane 27.22 deg. In all the cases deformity was corrected within acceptable criteria. Post-operative magnitude of sagittal

plane deformity was average 03 deg. and 05 deg., which were within acceptable limit and mean oblique plane deformity was 9.59 deg. In one case of our study had translation deformity 16mm and it was corrected to acceptable? The previous study [14] observed that 3 patients had a deformity in one plane, and 13 had a deformity in two planes. In our study, the nonunion time ranged from 9 months to 43 months, mean duration of non-union was 21 months. Study<sup>14</sup> also showed that the nonunion time ranged from 8–48 months. All nonunion healed at an average follow-up of 38.1 months (range 24–95 months).

The average time spent in the external fixator was 7.1 months (range 5–10 months). In the present study, the final follow-up all the nonunion are united. Stable union was achieved in all patients in another study as well [16]. In a different study [9] it was reported that distraction osteogenesis can be used to treat hypertrophic nonunion associated with angular deformity and shortening after Coventry style high tibial osteotomy in Five consecutive patients. Union was achieved by the time of fixator removal, which averaged 4.4 months. In the present study follow up ranged from 7-12 months, mean 10 months. Another previous study [15] reported that, the mean treatment time was 6.4 months (4 to 10). The mean follow up period was 64 months (24-120). A different report [14] showed all nonunion healed at an average follow-up of 38.1 months (range 24–95 months). The average time spent in the external fixator was 7.1 months (range 5–10 months). Again, in another [16] series of study showed follow-up time ranged from three to 11 years. Author in a different report [17] presented a series of ten hypertrophic nonunion in which the mean length gained was 3.5 cm (1 to 6) and the mean angular correction was 13.5° (0 to 40). The mean treatment time was 10.2 months (3 to 15) and mean follow-up was 40 months (6 to 71). The current series, all patients fit Paley's description of stiff hypertrophic nonunion. In our study 1 (6.66%) of the patients had pin track infection noticed and 3 patients (20%) developed breakage of wire/wire fixation bolt. In a previous study [14], complications included minor pin tract infections one case and hardware problems in two cases; which were managed by simple measure like antibiotic and realignment. No cases of nerve injury are encountered.

### Limitations of the study

This study has several limitations. The study sample was small (08), duration of study was one year and there was lack of adequate facilities, difficulties in follow up. The sample size was too low to generalize the findings of the present study to reference population.

### CONCLUSION

In this study short term follow up showed satisfactory result of hypertrophic nonunion of tibia with shortening and deformity. All the aspects of

problem with this type of nonunion is addressed, union is achieved without further complications. As the outcome evaluation was done 5-11 months after operation, changes in outcome beyond 3-11 months like Knee, ankle arthritis and symptom status, recurrence of deformity, collapse of lengthen segment could not be ascertained.

### RECOMMENDATIONS

This study can serve as a pilot to a much larger research involving multiple centers that can provide a nationwide picture, validate regression models proposed in this study for future use and emphasize points to ensure better management and adherence.

### REFERENCES

1. Simard, S., Marchant, M., & Mencia, G. (1992). The Ilizarov procedure: limb lengthening and its implications. *Physical therapy*, 72(1), 25-34.
2. Codivilla, A. (1905). On the means of lengthening, in the lower limbs, the muscles and tissues which are shortened through deformity. *JBJS*, 2(4), 353-369.
3. Wagner, H. (1978). Operative lengthening of the femur. *Clin Orthop*, 136; 125–142
4. Hood, R. W., & Riseborough, E. J. (1981). Lengthening of the lower extremity by the Wagner method. A review of the Boston Children's Hospital Experience. *The Journal of bone and joint surgery. American volume*, 63(7), 1122-1131.
5. Catagni, M. A., Guerreschi, F., Holman, J. A., & Cattaneo, R. (1994). Distraction osteogenesis in the treatment of stiff hypertrophic nonunions using the Ilizarov apparatus. *Clinical orthopaedics and related research*, (301), 159-163.
6. Gordon, J. E., Jani, M., Dobbs, M., Luhmann, S. J., Szymanski, D. A., & Schoenecker, P. L. (2002). Treatment of rigid hypertrophic posttraumatic pseudarthrosis of the tibia in children using distraction osteogenesis. *Journal of Pediatric Orthopaedics*, 22(4), 419-423.
7. IizaTOW, G. A. (1989). ThetemSion-Stressefecton the genesisand growth oftissues; Part I. Theinfluence of Stability offixation and Soft tissue preServation. *Cit Orhop*, 238, 249-281.
8. Kocaoglu, M., Eralp, L., Sen, C., Cakmak, M., Dincyürek, H., & Göksan, S. B. (2003). Management of stiff hypertrophic nonunions by distraction osteogenesis: a report of 16 cases. *Journal of orthopaedic trauma*, 17(8), 543-548.
9. Rozbruch, S. R., Herzenberg, J. E., Tetsworth, K., Tuten, H. R., & Paley, D. (2002). Distraction osteogenesis for nonunion after high tibial osteotomy. *Clinical Orthopaedics and Related Research*, 394, 227-235.
10. Wu, C. C., & Shih, C. H. (1994). Comparison of dynamic compression plating and reamed intramedullary nailing in the treatment of aseptic

- tibial shaft nonunions. Contemporary orthopaedics, 28(1), 28-33.
11. Court-Brown, C. M., Keating, J. F., Christie, J., & McQueen, M. M. (1995). Exchange intramedullary nailing. Its use in aseptic tibial nonunion. The Journal of bone and joint surgery. British volume, 77(3), 407-411.
  12. Helfet, D. L., Jupiter, J. B., & Gasser, S. (1992). Indirect reduction and tension-band plating of tibial non-union with deformity. The Journal of bone and joint surgery. American volume, 74(9), 1286-1297.
  13. Richmond, J., Collieran, K., Borens, O., Kloen, P., & Helfet, D. L. (2004). Nonunions of the distal tibia treated by reamed intramedullary nailing. Journal of orthopaedic trauma, 18(9), 603-610.
  14. Kocaoglu, M., Eralp, L., Sen, C., Cakmak, M., Dincyürek, H., & Göksan, S. B. (2003). Management of stiff hypertrophic nonunions by distraction osteogenesis: a report of 16 cases. Journal of orthopaedic trauma, 17(8), 543-548.
  15. Patwa, J.J., & Pithwa, A., & Shah, Y. (2001). Distraction osteosynthesis for hypertrophic nonunion of tibia. Indian Journal of Orthopaedics, 35(2); 37-9.
  16. Heiple, K.G., Herndon, C.H. (1965). The pathologic physiology of nonunion. Clin Orthop, 43; 11–21.
  17. Saleh, M. (1992). Non-union surgery: Part I. basic principles of management. Int J Orthop Trauma, 2; 4-18.