

Gerota Liposarcoma: A Case Report

Keita MM*, Azarg A, Errai A, Dahami D, Asarf I

Urology Department, Mohammed VI University Hospital BP2360 Principal, Avenue Ibn Sina, Marrakech, Morocco

DOI: [10.36347/sasjs.2021.v07i08.018](https://doi.org/10.36347/sasjs.2021.v07i08.018)

| Received: 11.06.2021 | Accepted: 13.07.2021 | Published: 30.08.2021

*Corresponding author: Keita MM

Abstract

Case Report

We report an observation of a giant retroperitoneal liposarcoma encompassing the kidney. The patient was operated on by midline incision laparotomy. In light of this observation, the symptomatology, diagnosis and treatment options are discussed.

Keywords: Retroperitoneal mass, Liposarcoma, Gerota, Laparotomy.

Copyright © 2021 The Author(s): This is an open-access article distributed under the terms of the Creative Commons Attribution 4.0 International License (CC BY-NC 4.0) which permits unrestricted use, distribution, and reproduction in any medium for non-commercial use provided the original author and source are credited.

INTRODUCTION

Retroperitoneal liposarcomas are rare mesenchymal tumors; they represent 7.5 to 25% of all soft tissue sarcomas and 1 to 2% of urogenital malignancies [1, 2]. They are primitive and independent of the organs of the retro peritoneal space. Their diagnosis has greatly benefited from advances in imaging, however, they continue to experience diagnostic, therapeutic and above all evolutionary difficulties [1]. We report an observation of a giant retroperitoneal liposarcoma encompassing the kidney.

OBSERVATION

A 74-year-old woman, with a history of type 2 diabetes and high blood pressure, who consulted for right lumbar pain progressing for 11 years, with pain in the hypogastrium and tenesmus associated with urinary incontinence with onset 4 years before the consultation of a median thoracic swelling, all developing in a context of unstated weight loss.

The clinical examination found a distended abdomen due to a mass occupying the entire right part of the abdomen of soft consistency, not painful, fixed, measuring approximately 15cm, the rest of the clinical examination did not find any particularity in particular no hematuria or endocrine syndrome.

Abdomino-pelvic CT revealed a large right retro peritoneal mass encompassing the right kidney measuring 19x12x14cm with a double fatty and tissue component, encompassing the right renal pedicle.

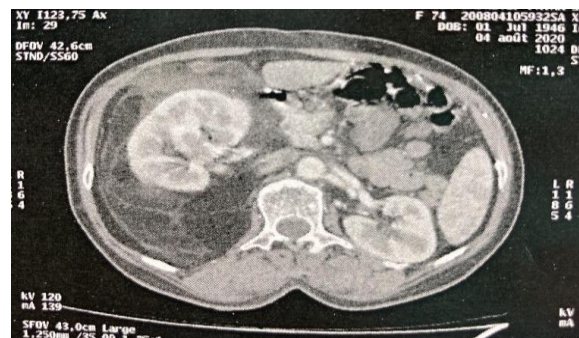


Fig-1: Abdominal CT scan with injection showing a heterogeneous mass encompassing the right kidney

The patient was operated. A midline incision was made, with colo parietal detachment, allowing a single-piece resection of the mass carrying the 22x15x16cm right kidney and weighing 2101.8g (Figure 2). It was a well-limited body fat, encapsulated with planes of sharp cleavages entirely encompassing the right kidney.

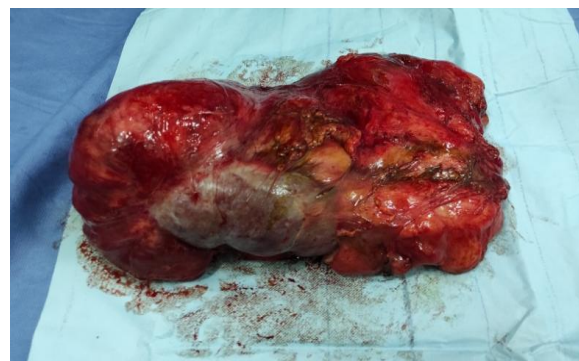

Fig-2: Macroscopic aspect of the operative part after complete resection

The postoperative consequences were simple, the patient was declared discharged on postoperative day 5 after removal of the Redon drain.

The histopathological examination of the part concluded with a grade II pleomorphic liposarcoma according to the FNCLCC with surgical excision limits which pass into healthy tissue.

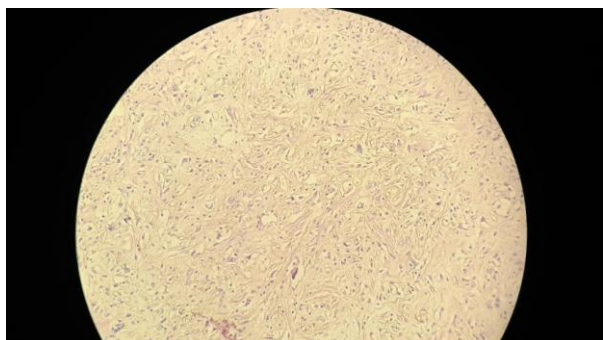


Fig-3: Microscopic appearance of liposarcoma type Pleomorphic

CT checks for 3 and 6 months confirmed that the patient was in complete remission without locoregional recurrences or distant metastases after a follow-up of 6 months.

DISCUSSION

Primary retroperitoneal sarcomas are defined as tumors independent of the retroperitoneal organs, these tumors arise from the connective, nervous and vestigial structures of the retroperitoneal space [3,4]. Dominated by liposarcomas which present 40 to 50% of retroperitoneal sarcomas [5].

Retroperitoneal liposarcomas mainly affect adults after 40 years with a slight female predominance [1]. The evolution of these tumors depends essentially on the histological classification [6-8]: the forms with round and pleomorphic cells are generally metastasal quite quickly [9], conversely, the myxoid and adult forms give few localizations visceral secondary, but are characterized by their tendency to local recurrence [9].

The pathogenesis of liposarcomas is still unclear, several hypotheses have been put forward, in particular the role of trauma, ionizing radiation, an oncogenic virus, certain chemicals and, finally, the occurrence of liposarcoma in a lipoma [3, 4].

The clinical symptomatology is insidious, characterized by latency of functional signs. Indeed, the increase in tumor size and the complacency of the retroperitoneal space explain the asymptomatic character and the large dimensions of these tumors [10]. As a result, the diagnosis is made late in the face of a palpable abdominal mass, gravity-type abdominal pain or signs of compression of neighboring organs [3, 10].

The abdominal mass and the signs of compression such as low back pain and hypogastric pain and tenesmus were the main symptoms that prompted our patient to consult.

The diagnosis is based on thoraco-abdominal computed tomography with 3D reconstruction. The tumor appears as a retroperitoneal tissue mass that pushes back the neighboring viscera without invading them. Fat density is characteristic of a differentiated liposarcoma, but may be absent if it is a dedifferentiated liposarcoma or another histological variety [11].

The standard treatment for liposarcomas is surgery. Its objective is a resection in healthy margins (R0 resection). It is immediately conceivable in 2/3 of patients [12]. Tumor characteristics govern surgical principles [11]. The first approach of choice is the median laparotomy which can be, if necessary, supplemented by transverse splits. External radiotherapy, brachytherapy and chemotherapy are ineffective as monotherapy [13]. Surgery is also the standard treatment for local recurrence [13].

The radiotherapy / surgery combination has been shown to be effective in the local control of sarcomas of the extremities [14]. Retroperitoneal localization complicates irradiation due to the width of the fields and / or the proximity of radiosensitive structures [15]. However, some studies suggest a gain in local control, especially when the tumor is of high grade or when the surgical margins are positive [14 16]. On the other hand, radiotherapy seems to lose its interest when it comes to low-grade liposarcoma and it is resected in healthy margins. The irradiation technique is not standardized. It can be delivered pre, per and / or post-operative. Chemotherapy is indicated in a metastatic situation when the lesions are not resectable.

The local relapse rate after appropriate surgical treatment is 13% at 1 year, 37% at 3 years and 50% at 5 years [17]. The rate of metastatic patients at follow-up is 14%, 29% and 34% at 1, 3 and 5 years [17]. Monitoring is based on physical examination, abdominopelvic computed tomography and chest x-ray. The frequency of examinations may vary depending on the risk of relapse. It can be offered every 3 to 6 months for 3 years, then every 6 months for 2 years, then every year beyond 5 years.

CONCLUSION

Liposarcoma is one of the most frequent retroperitoneal tumors, latent for a long time; it is often only discovered at the abdominal mass stage. Its treatment remains essentially surgical and its evolution is marked by a recurrence. The quality of the first surgery determines the survival without recurrence and the overall survival.

Conflicts of interest

The authors declare no conflict of interest

REFERENCES

1. Benchekroun A., Chikhani O., Ghadouane M., Alami. Farih MH, FAIK M. Retroperitoneal liposarcomas. About three cases. *Prog. Urol.*, 2000; 10: 446-449.
2. Touiti, D., Zrara, I., Ameer, A., Beddouch, A., Oukheira, H., & Benomar, S. (2001). Myxoid liposarcoma of the spermatic cord. *Progres en Urologie: Journal de L'association Francaise D'urologie et de la Societe Francaise D'urologie*, 11(6), 1302-1305.
3. Mounadif, M., Krati, K., Bellabah, A., Alaoui, R., Jamil, D., & CHERKAOUI, A. (1997). Le liposarcome rétro-péritonéal. *Médecine du Maghreb*, 62, 13-16.
4. Ameer, A., Lezrek, M., Mansari, O. E., Touiti, D., & Beddouch, A. (2003, October). Retroperitoneal sarcoma: therapeutic and prognostic characteristics, report of 6 cases. In *Annales d'urologie* (Vol. 37, No. 5, pp. 258-263).
5. Stoeckle, E., Coindre, J. M., Bonvalot, S., Kantor, G., Terrier, P., Bonichon, F., & Nguyen Bui, B. (2001). Prognostic factors in retroperitoneal sarcoma: a multivariate analysis of a series of 165 patients of the French Cancer Center Federation Sarcoma Group. *Cancer: Interdisciplinary International Journal of the American Cancer Society*, 92(2), 359-368.
6. Laqbaqbi, A., Lehn, E., Levasseur, J. C., Fontaine, P., Mourad, H., & Roche, J. Y. (1987). Retroperitoneal liposarcoma. Clinical, prognosis and therapeutic aspects apropos of 4 cases. *Journal de chirurgie*, 124(5), 331-336.
7. Erešué, J., Philippe, J. C., Casenave, P., Laurent, F., Grenier, N., Simon, J. M., & Tavernier, J. (1984). Computed x-ray tomography of abdominal lipoma and liposarcoma in adults. Apropos of 9 cases. *Journal de radiologie*, 65(3), 145-149.
8. Springfield, D. (1993). Liposarcoma. *Clin. Orthop. Related Res*, 289; 50-57.
9. Carbonne, B., Flam, T., Desligneres, S., Zerbib, M., Steg, A., & Debré, B. (1991). Conservative treatment of a recurring retroperitoneal liposarcoma. Apropos of a case followed over 27 years. *Journal d'urologie*, 97(2), 103-105.
10. Hassouna, J.B., Slimane, M., Damak, T. (2008). Retroperitoneal sarcomas: experience of a center. *Cancer-Radiotherapy*, 12; 331-335.
11. Avancès, C., Rigaud, J, Bui, B., Camparo, P., Culine, S., Durand, X., Sèbe, P., M. (2010). Soulié and the members of the CCAFU: Sarcomas of the retroperitoneum: Contribution of the CCAFU to the INCa Progress reference system in Urology, 4, S290 – S297
12. Mendenhall, W. M., Zlotecki, R. A., Hochwald, S. N., Hemming, A. W., Grobmyer, S. R., & Cance, W. G. (2005). Retroperitoneal soft tissue sarcoma. *Cancer*, 104(4), 669-675.
13. Benchekroun, A., Chikhani, O., Ghadouane, M., Alami, M., Farih, M.H., Faik, M. (2007). Retroperitoneal sarcomas *Prog Urol*, 1151
14. Yang, J. C., Chang, A. E., Baker, A. R., Sindelar, W. F., Danforth, D. N., Topalian, S. L., ... & Rosenberg, S. A. (1998). Randomized prospective study of the benefit of adjuvant radiation therapy in the treatment of soft tissue sarcomas of the extremity. *Journal of clinical oncology*, 16(1), 197-203.
15. Harrison, L. C. (2000). Adjuvant radiation therapy of retroperitoneal sarcoma: the role of intraoperative radiotherapy (IORT). *Sarcoma*, 4(1-2), 11-16.
16. Pawlik, T. M., Pisters, P. W., Mikula, L., Feig, B. W., Hunt, K. K., Cormier, J. N., ... & Swallow, C. J. (2006). Long-term results of two prospective trials of preoperative external beam radiotherapy for localized intermediate-or high-grade retroperitoneal soft tissue sarcoma. *Annals of surgical oncology*, 13(4), 508-517.
17. Bonvalot, S., Rivoire, M., Castaing, M., Stoeckle, E., Le Cesne, A., Blay, J. Y., & Laplanche, A. (2009). Primary retroperitoneal sarcomas: a multivariate analysis of surgical factors associated with local control. *Journal of Clinical Oncology*, 27(1), 31-37.