

Fistulized Retroperitoneal Mass with Skin Suggestive of Retroperitoneal Tuberculosis

Dahbi Skali Laila^{1*}, Moufid Abdellah¹, Azzouz Lotfi¹, Benamar Said¹, Mdaghri Jalil¹, Mssrouri Rahal¹, Settaf Abdellatif¹

¹Surgery Department B, Ibn Sina University Hospital Center, Rabat, Morocco

DOI: [10.36347/sasjs.2022.v08i08.010](https://doi.org/10.36347/sasjs.2022.v08i08.010)

| Received: 09.07.2022 | Accepted: 16.08.2022 | Published: 19.08.2022

*Corresponding author: Dahbi Skali Laila

Surgery Department B, Ibn Sina University Hospital Center, Rabat, Morocco

Abstract

Case Report

Extra-pulmonary tuberculosis is becoming more and more frequent, especially in endemic countries such as Morocco, it is manifested by very variable and non-specific clinical pictures which can be the cause of a diagnostic and therapeutic delay. We report the case of a 31-year-old woman, in whom a laparotomy was indicated for a retroperitoneal mass fistulized to the skin, allowing the diagnosis of tuberculosis.

Keywords: Retroperitoneal mass, tuberculosis, surgery.

Copyright © 2022 The Author(s): This is an open-access article distributed under the terms of the Creative Commons Attribution 4.0 International License (CC BY-NC 4.0) which permits unrestricted use, distribution, and reproduction in any medium for non-commercial use provided the original author and source are credited.

INTRODUCTION

Tuberculosis is a major public health problem in Morocco and in the world due to its frequency and severity. The extra-pulmonary form represents almost a third of the cases of tuberculosis declared in Morocco [1]. The abdominal location is relatively frequent and represents 5 to 10% of all locations [2]. It can be manifested by atypical and misleading clinical pictures confusing with a inflammatory or neoplastic pathology, hence the importance of evoking tuberculosis in front of a suggestive epidemiological context, concomitant pulmonary involvement, or history of tuberculosis. If the diagnosis is made early with adequate management, anti-bacillary treatment is often effective with a good clinical and radiological evolution [3].

OBSERVATION

This is a 31-year-old patient, with no particular pathological history, who consulted for abdominal pain in the right iliac fossa evolving for 6 months from her admission, complicated 15 days later by the appearance of a mass in the right iliac fossa, all evolving in a context of apyrexia and conservation of general condition. Somatic examination found an afebrile patient, hemodynamically and respiratory stable. Abdominal examination revealed a 10 cm mass, painful, tense in the right iliac fossa with adjacent signs of inflammation, associated with tenderness in the left iliac fossa. An abdominal ultrasound was requested and showed bilateral latero-uterine tubular formations, with thin walls, containing some parietal fringes, with anechoic content realizing the aspect in fishing net,

measuring 72*61 mm on the right and 70*59 on the left, making evoke a bilateral pyosalpinx. Faced with the diagnostic uncertainty, abdominal-pelvic magnetic resonance imaging was requested, showing bilateral confluent collections of the iliopsoas muscles with an enhanced wall after injection of contrast product containing a few more marked air bubbles on the left, most voluminous measuring 70*82 mm. It was associated with irregularity and erosion of the vertebral endplates at the L4-S1 level with a small prevertebral collection suggestive of spondylodiscite. A chest x-ray was requested, was normal. Biologically, we noted a slight increase in CRP to 53, 32 mg/l with the rest of the biological assessment which returned to normal. The search for Koch's bacillus in the sputum was negative.

In view of the bilaterality of the retroperitoneal abscess, one of which is fistulized to the skin, the indication for surgery was raised. The patient was operated by a mini-laparotomy under the umbilical allowing on the one hand, the exploration of the peritoneal cavity as well as the uterus and its annexes which were of normal aspect and on the other hand the drainage of the abscesses of the two sides. A sample of pus and the abscess shell were sent to the bacteriology and anatomo-pathology laboratory, which suggested a granulomatous inflammatory reaction with caseous necrosis in favor of caseofollicular tuberculosis. The post-operative follow-up was simple, the patient was put on anti-bacillary treatment on leaving the hospital and was transferred to the neurosurgery department for the management of her tuberculous spondylodiscitis.

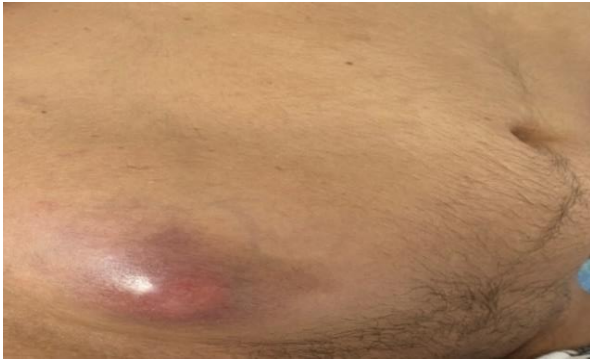

Figure 1: Image showing the right iliac fossa mass at the pre-skin fistulization phase

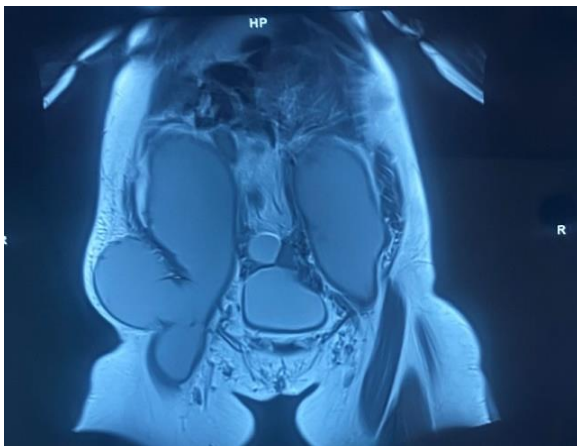

Figure 2: Abdomino-pelvic MRI showing bilateral iliopsoas muscle collections

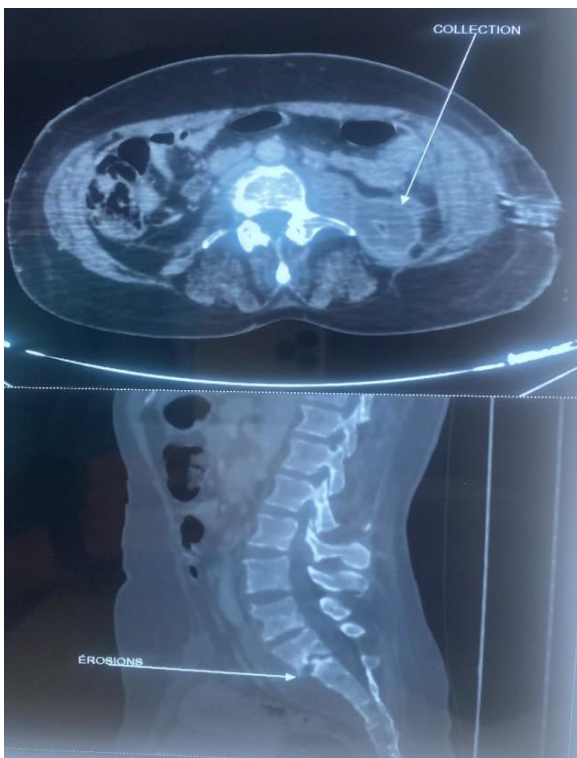


Figure 3: Erosions of the vertebral plates of L4-S1 with a prevertebral collection in favor of a spondylodiscite

DISCUSSION

Tuberculosis is a transmissible and non-immunizing infectious disease, caused by *Mycobacterium Tuberculosis* whose reservoir is human and transmission is airborne. The pulmonary localization is the most frequent but the bacillus of Koch can reach several organs realizing the extra-pulmonary tuberculosis. Abdominal involvement occupies the 3rd place of interest to 5% to 10% of all locations [2].

Apart from peritoneal tuberculosis, the most affected abdominal viscera are the small intestine (44%), the cecum (35%) and the ileocecum (16%) [4]. Liver damage is very rare estimated at 1%. Splenic involvement is often associated with liver damage. Pancreatic involvement is exceptional. Renal involvement in the context of uro-genital involvement represents 3% [5].

Bone damage (tuberculous spondylodiscitis or Pott's disease, osteoarthritis) can cause spinal cord compression from a retroperitoneal mass or psoas abscess [6].

Diagnosis of extra-pulmonary forms is often difficult, especially outside TB-endemic countries where the diagnosis is rarely suspected initially. On the diagnostic level, the absence of specificity of the signs of calls, and the great polymorphism of the disease explaining the diagnostic delay [7-9].

Retroperitoneal tuberculosis can manifest itself most often by abdominal pain [10, 11], or more rarely by a palpable mass [12-14], which can simulate an inflammatory or neoplastic pathology, especially if an alteration in the general state is associated. It can involve the retroperitoneal organs (nothing, adrenal glands) responsible for a clinical picture consisting of macroscopic hematuria or low back pain [15]. Somatic examination must be carried out systematically in search of other tuberculous localization, in particular pleuropulmonary and lymph nodes.

Like the clinic, biology is not specific. Biological examinations often show an inflammatory syndrome of varying intensity. This sign is of little interest for the diagnosis.

Ultrasound, computed tomography (CT) and nuclear magnetic (MRI) signs are not specific, revealing a psoas abscess, retroperitoneal lymphadenopathy or a mass at the expense of the retroperitoneal organs without being able to confirm the tuberculous nature [16, 17]. Thus, the great polymorphism of the radio-clinical picture, the limits of biological and bacteriological examinations combined with the ambiguity of imaging, explain the use of exploratory surgery in the face of a suspicious mass of undetermined origin [18].

Surgical treatment therefore retains its place in the event of complications such as an abscess, a compressive or fistulized mass, as is the case in our patient [3,19]. The anti bacillary treatment is always indicated whether it is in first or in 2th intention in addition to surgery.

CONCLUSION

Retroperitoneal tuberculosis presents a clinical and radiological polymorphism that can delay the diagnosis until the stage of complications, hence the interest of evoking it in the face of any retroperitoneal mass, especially in endemic countries. The treatment surgery retains its place in the event of complications, making it possible to establish the diagnosis of certainty and subsequently to initiate antibacillary treatment until recovery.

REFERENCES

1. Ismaïli, Z., Amraoui, M., Mansouri, F., Essamri, W., Benazzouz, M., & Essaid, E. (2006). Pseudo-tumoral colonic tuberculosis with dual localization. *Maghreb Medicine*, 142, 5-8.
2. Romand, F., Gaudin, J., Bobichon, R., & Souquet, J. (1997). Abdominal tuberculosis with pseudo-tumor appearance. *The medical press*, 26(36), 1717-1721.
3. Hablani, N., Mhiri, M. S., Graies, K. T., Gharbi, H. J., Abdallah, S., & Hamida, R. B. H. (2005). Pseudo-tumoral abdominal tuberculosis: Apropos of 4 cases. *Journal of Radiology*, 86(9), 1021-1025.
4. Barber, J. P. (1975). Intestinal tuberculosis. *Encycl Med Chir (Elsevier, Paris) Stomach-intestinal*, 9060, A10.
5. WHO:
<http://www.who.int/mediacentre/factsheets/fs104/fr/>
6. Seth, A., Ansari, M. S., TRIKHA, V., & MITTAL, R. (2001). Retroperitoneal fibrosis: a rare complication of Pott's disease. *The Journal of urology*, 166(2), 622-623.
7. Pr L Kacemi, R Dafiri: Department of Radiology, Children's Hospital – Maternity, Rabat, Morocco.
8. Chattopadhyay, A., Bhatnagar, V., Agarwala, S., & Mitra, D. K. (1997). Genitourinary tuberculosis in pediatric surgical practice. *Journal of pediatric surgery*, 32(9), 1283-1286.
9. Dworkin, G., Reisman, L., Ben-Zvi, Z., & Lieberman, K. V. (1991). Association of hematuria and mycobacterial infection. *Child nephrology and urology*, 11(1), 44-46.
10. Tanrikulu, A. C., Aldemir, M., Gurkan, F., Suner, A., Dagli, C. E., & Ece, A. (2005). Clinical review of tuberculous peritonitis in 39 patients in Diyarbakir, Turkey. *Journal of gastroenterology and hepatology*, 20(6), 906-909.
11. Thoreau, N., Fain, O., Babinet, P., Lortholary, O., Robineau, M., Valeyre, D., ... & Thomas, M. (2002). Peritoneal tuberculosis: 27 cases in the suburbs of northeastern Paris. *The International Journal of Tuberculosis and Lung Disease: the Official Journal of the International Union Against Tuberculosis and Lung Disease*, 6(3), 253-258.
12. Bouraoui, S. (2003). Extra pulmonary tuberculosis in Tunisia. About 830 cases. *Experience of the Pathological Anatomy Laboratory of the Rabat Tunisia Medical Hospital*, 81(8), 529-534.
13. Dafiri, R., & Imani, F. (2001). Abdominal tuberculosis. *Medico-Surgical Encyclopedia. Radiodiagnosis-Digestive Apparatus*, 33-010-A-30.
14. Jarboui, L. (2006). Imaging of the normal and pathological peritoneum Thesis for the doctoral degree in medicine Sfax.
15. Gow, J. G. (1998). Genitourinary tuberculosis. In: *Campbell's Urology*, 7th Edition. Walsh PC, Retik AB, Stamey TA, Vaughan ED. Jr. Eds. *Philadelphia, Saunders WB. Co*, 807-836.
16. Thoreau, N., Fain, O., Babinet, P., Lortholary, O., Robineau, M., Valeyre, D., ... & Thomas, M. (2002). Peritoneal tuberculosis: 27 cases in the suburbs of northeastern Paris. *The International Journal of Tuberculosis and Lung Disease: the Official Journal of the International Union Against Tuberculosis and Lung Disease*, 6(3), 253-258.
17. Sanai, F. M., & Bzeizi, K. I. (2005). Systematic review: tuberculous peritonitis—presenting features, diagnostic strategies and treatment. *Alimentary pharmacology & therapeutics*, 22(8), 685-700.
18. Volpi, E., Calgaro, M., Ferrero, A., & Viganò, L. (2004). Genital and peritoneal tuberculosis: potential role of laparoscopy in diagnosis and management. *The Journal of the American Association of Gynecologic Laparoscopists*, 11(2), 269-272.
19. El Barni, R., Lahkim, M., & Achour, A. (2013). Pseudo-tumor abdominal tuberculosis. *Pan African Medical Journal*, 13(1).