

## Surgical Treatment of Caroli Disease Unilobar: 8 Cases and Review of Literature

Doctor Abdellah Moufid<sup>1,2\*</sup>, Mustapha Traoré<sup>1,2</sup>, Settaf Abdellatif<sup>1,2</sup>

<sup>1</sup>Digestive Surgical Department B, Ibn Sina University Hospital, Rabat, Morocco

<sup>2</sup>Faculty of Medicine and Pharmacy, Mohammed V University in Rabat, Morocco

DOI: [10.36347/sajs.2023.v09i04.009](https://doi.org/10.36347/sajs.2023.v09i04.009)

| Received: 07.03.2023 | Accepted: 14.04.2023 | Published: 18.04.2023

\*Corresponding author: Doctor Abdellah Moufid

Digestive Surgical Department C, Ibn Sina University Hospital, Rabat, Morocco

### Abstract

### Original Research Article

**Introduction:** Caroli disease is rare congenital disorder characterized by segmental intrahepatic bile duct ectasia always communicating with the bile ducts. **Methods:** The aim of this study for 08 cases of Caroli disease is to assess the role of surgery in the treatment of Caroli disease unilobar, focusing on epidemiological, clinical, anatomopathological and surgical aspects. **Results:** The middle age was 52,24 years with (4H/4F), this disease was located on the left in 7 cases and on the right in one case. It was manifested by abdominal pain (100%), cholangitis (25%), jaundice (25%) and fever (12,5). It was complicated by intrahepatic lithiasis (75%), liver abscess (27,5%) and cholangiocarcinoma (25%). Hepatic cholestasis was found in 3 cases. Imaging evoked the diagnosis by showing cystic dilatation of the intrahepatic bile ducts communicating with the biliary tree. Hepatic resection was the treatment of choice for 7 patients with bilio-digestive anastomosis on Y in 2 patients and a lateral-lateral choledoco-duodenal bypass in 2 patients. Histology confirmed the diagnosis in all cases. Two patients died 1 month after the procedure. Only one patient was lost to follow-up and the evolution was favorable for the other patients with a mean follow-up of 6 years. **Conclusions:** It seems evident that premature treatment followed by regular supervision makes it possible to detect and treat complications.

**Keywords:** Caroli disease, congenital disorder, surgical aspects, diagnosis.

Copyright © 2023 The Author(s): This is an open-access article distributed under the terms of the Creative Commons Attribution 4.0 International License (CC BY-NC 4.0) which permits unrestricted use, distribution, and reproduction in any medium for non-commercial use provided the original author and source are credited.

## INTRODUCTION

Caroli's disease is a rare congenital malformation of the intrahepatic bile ducts characterized by duct ectasia and dilation, which may involve the biliary tract in a focal or multifocal manner [1].

It's included in group V of the Todani classification of biliary tract cystic diseases and was first described by the French gastroenterologists, Jacques Caroli *et al.*, in 1958 [2, 3].

Two types of CD were later recognized. Type I, or simple CD, consists of pure cystic dilatations of the intrahepatic bile ducts, whereas type II, or complex CD, also known as Caroli's syndrome (i.e. CD with congenital hepatic fibrosis), is associated with hepatic fibrosis, or even cirrhosis, portal hypertension and oesophageal varices [4]. Type II CD may be accompanied by cholangiocarcinoma, calculi of the

intrahepatic duct, cholangitis pancreatic cyst, renal cystic disease or medullary sponge kidney [6].

Caroli's disease is less common than Caroli's syndrome, and both are extremely rare with an approximate prevalence of less than one in 1,000,000 inhabitants [5].

It usually affects the entire liver but can occasionally involve only one lobe, commonly the left. This study is about 8 cases of monolobar Caroli's disease in the department of surgery B in Avicenne Hospital Rabat with a review of the literature.

## METHODS

It's about a retrospective study of 8 cases of unilobar Caroli's disease in the department of surgery B in Avicenne Hospital Rabat with a review of the literature.

In order to determine the list of patients whose entry or exit diagnosis was that of a pathology concerning monobar Caroli disease, we used:

The registers of patients hospitalized in the B Avicenne surgery department. Medical records and Surgical reports.

We noted the various epidemiological, clinical, para-clinical, therapeutic and evolutionary data on a data sheet filled in for each patient.

**The variables to be studied:** Age, sex, personal and family history, clinical examination and para-clinical examinations carried out, diagnosis retained, therapeutic management and finally the evolution of the patient's condition.

## RESULTS

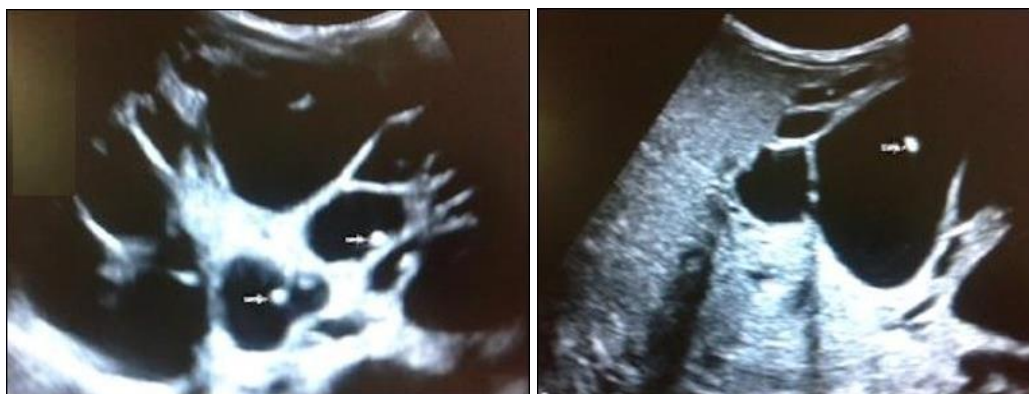The presentation, management, and outcome are summarized in Table 1 .The average age of our patients was 52.25 years with age extremes ranging from 17 to 76 years Our series includes 8 patients, divided into 4 men or 50% of cases and 4 women 50% of cases, with a sex – ratio equal to 1 with (4H/4F), this disease was located on the left in 7 cases and on the

right in one case. It was manifested by the isolated or associated clinical signs leading to the discovery of Caroli's disease were:

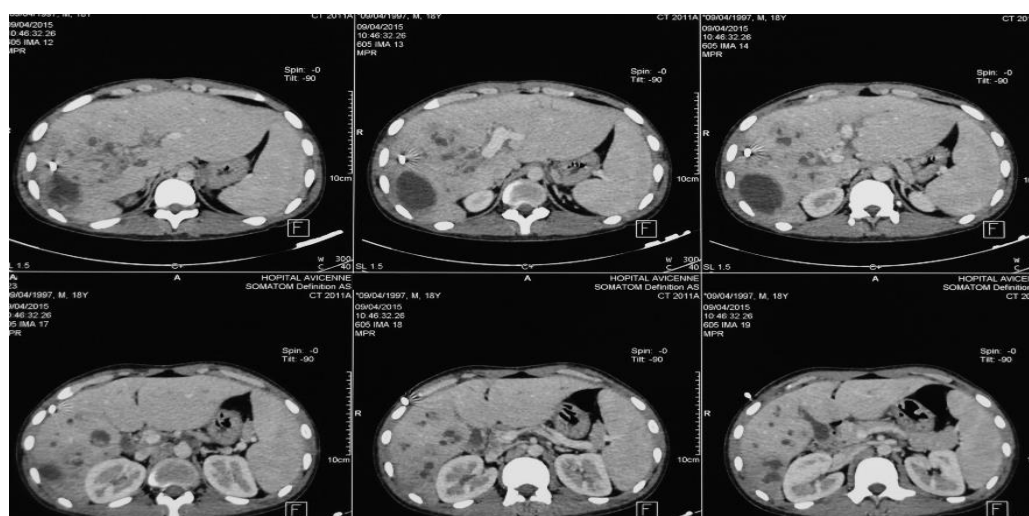
Abdominal pain such as hepatic colic in 6 patients of (75%), acute cholangitis was present in 2 patients 25%, Cholestatic jaundice was present in 2 (25%), Fever was observed in one (12.5%) case.. It was complicated by intrahepatic lithiasis in (75%) of cases, liver abscess (27,5%) in of cases and cholangiocarcinoma (25%) in cases.

Hepatic cholestasis was found in 3 cases as well as the increase in hepatic cytolysis enzymes in 3 patients and The level of tumor markers was high in one case (the sixth case): ACE =10xN and CA 19-9 =1368xN.

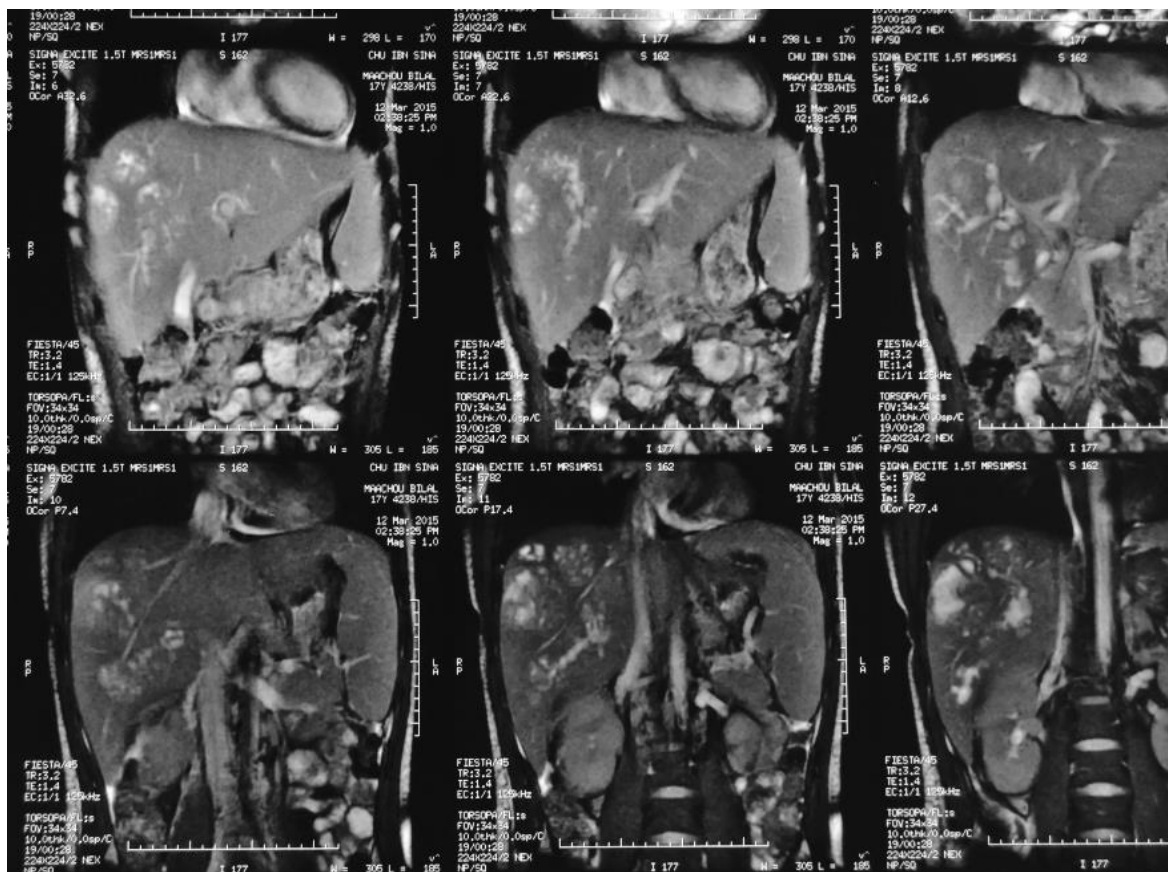
Imaging evoked the diagnosis by showing cystic dilatation of the intrahepatic bile ducts communicating with the biliary tree. We realized an abdominal ultrasound to all patients (fig. 1). A CT in 5 cases (fig. 2) Bili-MRI in 5 cases (fig. 3) and Intraoperative cholangiography to 3 patients (fig. 4).



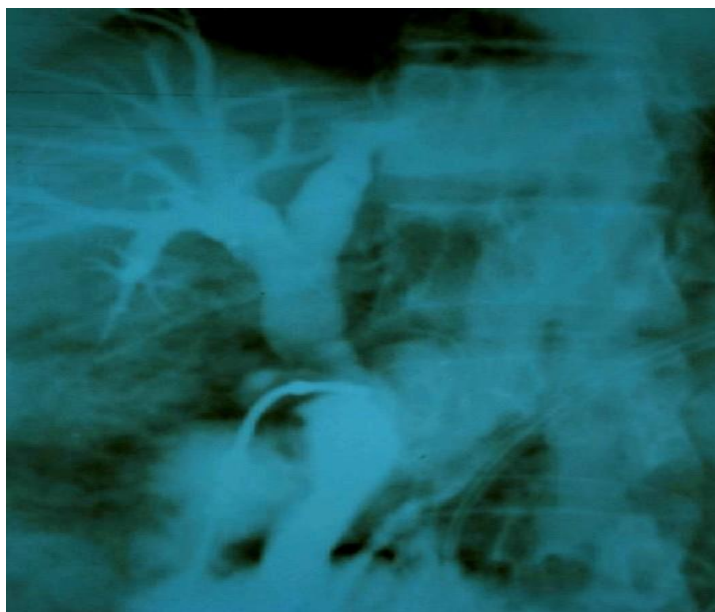
**Fig. 1:** A US showing multiple intra-hepatic cystic formations diffused throughout the hepatic parenchyma but predominantly on the left



**Fig. 2:** Computed tomography scan demonstration right lobe biliary dilatations



**Fig. 3: Magnetic resonance cholangiopancreatography shows the secular ectasias of biliary tract**

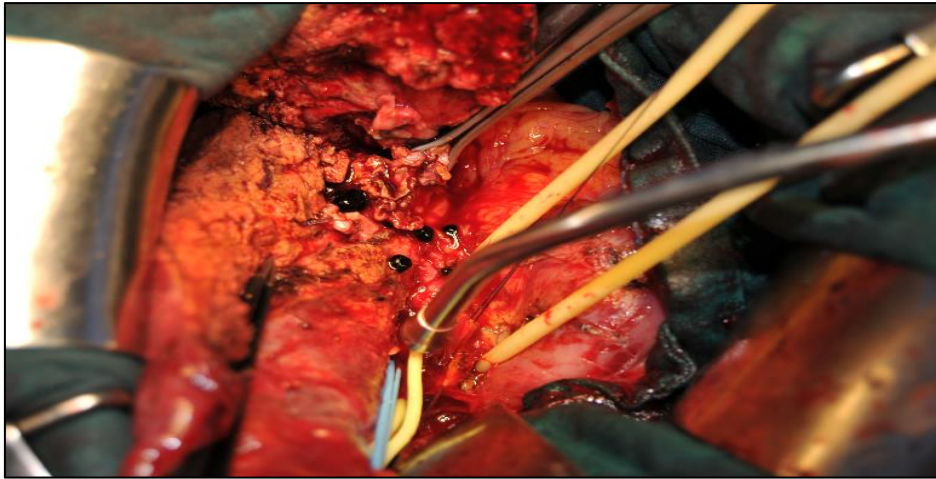


**Fig. 4: Intraoperative cholangiography: left bile ducts and CBD full of stones**

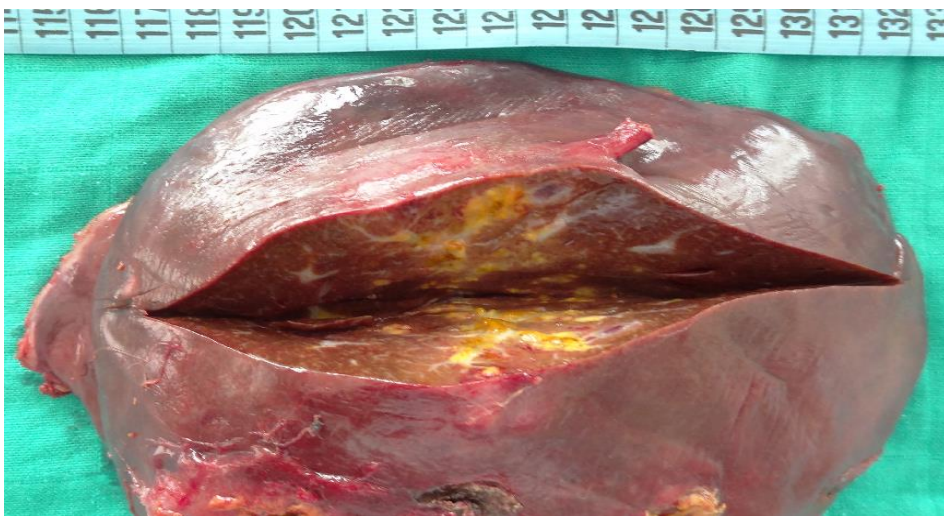
Resection was the treatment of choice for 7 patients; the treatment consisted in 3 left lobectomies, 3 left hepatectomies (fig. 5) and one right hepatectomy (fig. 6). With bilio-digestive anastomosis on Y for 2 patients and a lateral-lateral choledoco-duodenal bypass in 2 cases. Laprotomy in the eighth patient with unresectable cholangiocarcinoma (fig. 7).

Histology confirmed the diagnosis in all cases. Two patients died 1 month after the procedure. Only one patient was lost to follow-up and the evolution was favorable for the other patients with a mean follow-up of 6 years.

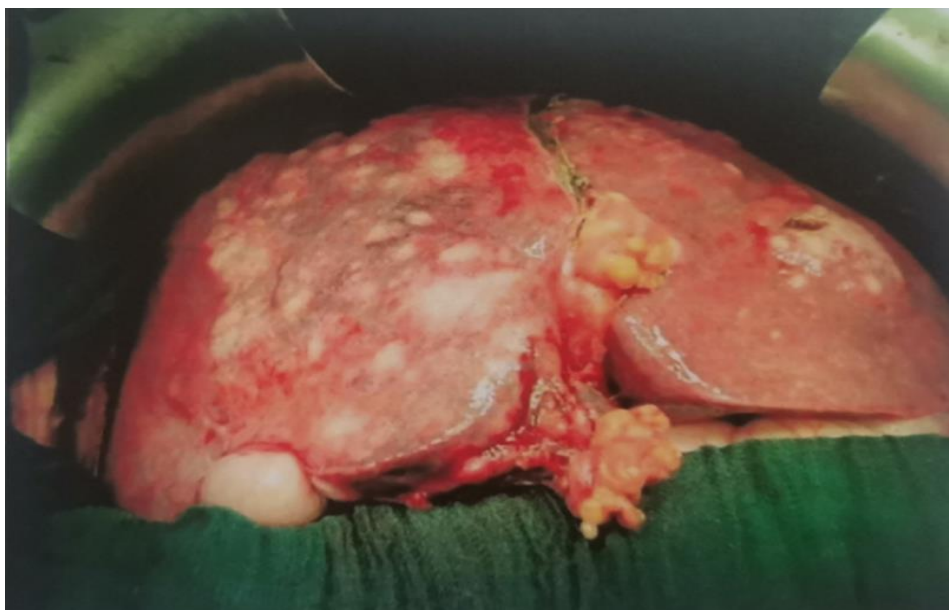



**Fig. 5:** intraoperative image (left hepatectomy) showing lithiasis inside the bile ducts



**Fig. 6:** Open right hepatectomy specimen showing dilated bile ducts containing stones



**Fig. 7:** Intraoperative image showing an unresectable cholangiocarcinoma on Caroli's disease

**Table 1: Management and outcome of our study (in French)**

	Cas 1	Cas 2	Cas3	Cas4	Cas5	Cas 6	Cas7	Cas8
<b>AGE</b>	17	58	54	40	42	60	76	71
<b>SEXE</b>	M	F	M	M	F	F	F	M
<b>CLINIQUE</b>	Coliques hépatiques + fièvre	Coliques hépatiques	Angiocholite + poussées récurrentes	Coliques hépatiques + ictère cholestatique	Angiocholite	Coliques hépatiques + ictère cholestatique	Coliques hépatiques	Coliques hépatiques
<b>BIOLOGIE</b>	Cholestase hépatique + Cytolyse hépatique	Cholestase hépatique		Hyper-bilirubinémie + Cytolyse hépatique		Cholestase hépatique + Cytolyse+ ACE et CA 19-9 élevés	Bilan hépatique normal	Bilan hépatique normal
<b>ECHOGRAPHIE ABDOMINALE</b>	Dilatation des VBIH du foie droit	Une dilatation localisée des VBIH au sein de laquelle on a noté la présence de 2 micro-lithiases	Une dilatation des VBIH et extra-hépatiques au-dessus- d'un obstacle lithiasique, présence de calculs au niveau de la VBO, des canaux hépatiques droits et gauches et des VBIH gauches	Empiement lithiasique chronique de la VBP avec hydrocholécyste lithiasique et légère dilatation des VBIH	Une voie biliaire dilatée et des cavités anéchogènes au niveau du segment I communiquant probablement avec les voies biliaires	Dilatation des VBIH au niveau du foie gauche et des signes d'aérobilie	Lobe gauche était le siège d'une petite dilatation des VBIH et de petit calcul, vésicule biliaire lithiasique à paroi fine	Dilatation des VBIH gauches
<b>TDM ABDOMINALE</b>	Abcès hépatiques des segments VI et VII VBIH droites légèrement dilatées avec présence d'un lot sign			Masse hépatique au niveau du segment IV, dilatation des VBIH gauches	Images hypodenses du segment I communiquant avec les voies biliaires intra-hépatiques	Une dilatation des VBIH et de la VBP à 20 mm en amaont d'une probable obstruction du bas cholédoque non individualisable		Un abcès au niveau du segment IV du foie en voie d'organisation
<b>BILI-IRM</b>	Abcès du foie droit, dilatation des VBIH droites et thrombose de la veine portale droite	Une dilatation des VBIHG avec multiples micro-lithiases et sténose du canal biliaire gauche				Une dilatation des VBIH et de la VBP sur cholangite sclérosante avec sludge de la vésicule biliaire et de la VBP	Une dilatation pseudo kystique des VBIH gauches compliquée de lithiase endocanalaire	multiples lithiases résiduelles au niveau du cholédoque Dilatation de la VBP et DBIH gauches Hypotrophie du foie gauche

EVOLUTION	INTERVENTION	COMPLICATION	LOCALISATION	DELAI AVANT LE DIAGNOSTIC	CHOLANGIO-GRAPHIE PER-OPERATOIRE
Favorable	Hépatectomie droite	Lithiase intra-hépatique Abcès hépatique	Droite	20 JOURS	
Décès	Hépatectomie gauche avec résection du segment I	Lithiase intra-hépatique	Gauche	24 ANS	
Favorable	Hépatectomie gauche avec dérivation bilio-digestive	Lithiase intra-hépatique	Gauche	1 ANS	Les canaux biliaires gauches bourrées de calculs ainsi que le canal du segment V la VBP dilatée et lithiasique
Favorable	Hépatectomie gauche	Lithiase intra-hépatique	Gauche	4 ANS	Un arrêt complet du produit de contraste au niveau du canal gauche sans visualisation de lithiase.
Favorable	*Lobectomie gauche avec anastomose cholédoco-duodénale latéro-latéral *Segmentectomie I et anastomose hépatico-jéjunale	Lithiase intra-hépatique	Gauche	20 MOIS	Les VBHI normales, l'opérateur ne vérifia pas l'état du lobe de Spiegel
Perdue de vue	Cholécystéctomie et cholédoctomie avec une anastomose cholédoco-duodénale latéro-latérale. Lobectomie gauche	Abcès hépatique cholangiocarcinome	Gauche	6 MOIS	
Décès	Chirurgie exploratrice avec niopsie du grand épiploon et biopsie de la masse hépatique	Cholangio-carcinome	Laparotomie exploratrice	-	
Favorable	Lobectomie gauche	Lithiase intra-hépatique Abcès hépatique	Gauche	5 ANS	

## DISCUSSION

Caroli's disease is rare, its prevalence is 1 case / 1,000,000 people [7].

The onset of Caroli's disease can occur at any age, it is often diagnosed during childhood or adolescence but can be diagnosed in adulthood [8] and reveals itself before the age of 30 years in 80% of cases [7].

It affects men and women equally with a sex ratio equal to 1 [7].

It is diffuse in 80% of cases and localized in 20% of cases (in the left lobe in 92% of cases and 8% on the right) [6].

The anatomopathological study confirms the diagnosis, looks for an associated lesion, in particular congenital hepatic fibrosis, and detects neoplasia [9].

Clinically Caroli's disease has no specific symptoms or signs which make diagnosis difficult.

Patients may remain asymptomatic throughout life or rarely express symptoms [8].

The clinical symptoms of this pathology vary depending on whether it is Caroli's disease or Caroli's syndrome.

In the 1st case, the clinical symptoms are related to cholangitis due to biliary obstruction, the formation of stones and possibly the development of liver abscesses.

In Caroli syndrome, the manifestations are essentially linked to congenital hepatic fibrosis and portal hypertension: splenomegaly, hepatomegaly, esophageal varices and digestive hemorrhages [10].

Degeneration into cholangiocarcinoma which is a rare intrahepatic tumor, developed from the epithelial cells of the intrahepatic bile ducts [15].

The risk of cancerization would be higher in unilobar Caroli diseases compared to diffuse Caroli diseases [16].

Patients with Caroli's disease have a risk of developing cholangiocarcinoma 100 times greater than that of the general population and the association with a hepatic tumor is found in 7–24% of cases [17].

In the literature, the liver biological tests are normal, with the exception of a moderate increase in the activity of alkaline phosphatase and gamma-glutamyl-transferase [11].

The diagnosis of Caroli's disease can be suggested by imaging techniques (ultrasound, computed tomography, cholangiopancreatography by MRI or CPRM) which detect cystic dilation of the intrahepatic bile ducts.

After injection of contrast product, CT and CPRM can highlight the central sign of the point, characterized by the enhancement of a vessel in the

center of the cystic dilatations, radiological evidence of the malformation of the ductal plate [12].

In addition to the cystic dilatations, the CPRM, although inconstantly, can identify the communications between the dilatations and the rest of the bile ducts, which make it possible to confirm the diagnosis of Caroli's disease [13].

The demonstration of stones in the dilated bile ducts is also an important argument in favor of the diagnosis [14].

Invasive investigations of the bile ducts should be avoided [11].

The goal of treatment is to reduce the mortality and morbidity associated with recurrent cholangitis, liver abscess and cholangiocarcinoma.

Abstention and simple monitoring: may be indicated for asymptomatic patient and it is done regularly on an outpatient basis to detect any deterioration or malignant degeneration as early as possible [18].

Administration of antibiotics based on ampicillin and gentamicin in case of cholangitis. Urodeoxycholic/Deoxycholic acid may be effective in the prevention and treatment of intrahepatic stones [19].

Several authors have reported a favorable outcome after complete endoscopic treatment [20-22] comprising endoscopic sphincterotomy, sweeping of the main bile duct and placement of a stent ensuring the evacuation of intrahepatic stones and dilation of strictures [21, 23].

Extracorporeal or intrabiliary lithotripsy represents a success in terms of complete clearance of stones and allows the prevention of acute cholangitis flare-ups [20].

This treatment is demanding requiring iterative endoscopies, replacement of the stent and the prescription of deoxycholic acid or urso-deoxy-cholic acid in the long term [20].

Surgical management A localized Caroli's disease does not pose a therapeutic problem. Partial hepatectomy should be proposed for unilobar forms, even certain bilobar lesions, without underlying hepatic or renal lesions [24].

Hepatectomy is indicated either in isolation, when it alone can solve the therapeutic problem, or in a multidisciplinary treatment program in association with endoscopic interventional methods.

It allows a permanent cure of the disease [16].



Patients with left monolobar Caroli disease require left lobectomy sometimes extended to resection of segment IV in the event of damage to the bile duct of this segment.

In case of localization of the lesions on the right, the importance of the hepatic resection depends on the segmental anatomical distribution of the biliary ectasias.

In the case of a diffuse form, liver transplantation is the intervention of choice [24].

It is discussed according to the patient's age, the duration of disease progression, the frequency of cholangitis and the existence of associated portal hypertension [25].

This liver transplant must be performed before the appearance of cholangiocarcinoma for most teams [26, 27].

However, Tanaka transplanted a young woman with diffuse degenerated Caroli's disease from a living donor. Two and a half years after the operation, no recurrence has been reported.

For this team, liver transplantation is the intervention of choice for diffuse Caroli disease, even in the presence of localized degeneration in the liver [28].

**Post-operative follow-up:** Long-term clinical, biological and radiological monitoring of patients is advised because of the possibility of occurrence of malignant degeneration.

## CONCLUSION

Caroli's disease is a rare congenital condition characterized by non-obstructive dilation of the intrahepatic bile ducts. The reference treatment for localized forms is segmental or lobar hepatic resection, while diffuse forms may justify liver transplantation. Furthermore, early surgical treatment is a prophylactic treatment for neoplasia.

## Data Availability Statement

The data that support the findings of this article are available from the corresponding author upon reasonable request.

## Competing Interests

The authors have no conflicts of interest and source of funding. The subject of the article had no commercial interest, no financial or material support.

## Ethics Statement

Drs Abdellah Moufid, Settaf Abdellatif, Mustapha Traoré declare no conflict of interest.

## REFERENCES

- Desmet, V. (1992). Congenital diseases of intrahepatic bile ducts: variations on the theme "ductal plate malformation". *Hepatology*, 16, 1069–1083.
- Caroli, J., & Couinaud, C. (1958). Une affection nouvelle, sans doute congénitale, des voies biliaires: la dilatation kystique uni-lobaire des canaux hépatiques [Article in French]. *La Sem des Hop*, 34, 496–502.
- Todani, T., & Watanabe, Y. (1977). Congenital bile duct cysts: classification, operative procedures, and review of thirty-seven cases including cancer arising from choledochal cyst. *Am J Surg.*, 134, 263–269.
- Caroli, J. (1973). Diseases of the intrahepatic biliary tree. *Clin Gastroenterol*, 2, 147–161.
- Millwala, F., Segev, D. L., & Thuluvath, P. J. (2008). Caroli's disease and outcomes after liver transplantation. *Liver Transplant*, 14, 11–17.
- Karim, A. S. (2004). Caroli's disease. *Indian Pediatr*, 41, 848–850.
- Jarry, J., Leblanc, F., & Saric, J. (2010). Maladie de Caroli monolobaire. *La Presse médicale (1983)*, 39(7-8), 847-848.
- Wang, Z. X., Li, Y. G., Wang, R. L., Li, Y. W., Li, Z. Y., Wang, L. F., ... & Xiao, X. H. (2015). Clinical classification of Caroli's disease: an analysis of 30 patients. *HPB*, 17(3), 278-283.
- El Alami, Y., Benamr, S., Mouslik, R., Massrouri, R., Essadel, E., M'daghri, J., ... & Chad, B. (2010). Role of surgery in monolobar Caroli disease. *African Journal of Hepato-Gastroenterology*, 4(3), 152-155.
- Abdellaoui, M., & Dafiri, R. (2014). Distension abdominale chez un nourrisson. *Feuillets de Radiologie*, 54(4), 267.
- Dhumeaux, D. (2005). Lésions kystiques congénitales des voies biliaires intra et extra-hépatiques. *Gastroentérologie clinique et biologique*, 29(8-9), 878-882.
- Desmet, V. J. (2005). Maladies kystiques du foie : de l'embryologie aux malformations. *Gastroenterol Clin Biol*, 8-9, 852-4.
- Luciani, A., Kobeiter, H., Zegai, B., Anglade, M. C., Deux, J. F., Malhaire, C., & Rahmouni, A. (2005). Maladies fibro-kystiques congénitales du foie: aspects radiologiques. *Gastroentérologie clinique et biologique*, 29(8-9), 870-874.
- Krausé, D., Cercueil, J. P., Dransart, M., Cognet, F., Piard, F., & Hillon, P. (2002). MRI for evaluating congenital bile duct abnormalities. *Journal of computer assisted tomography*, 26(4), 541-552.
- Metairie, S., Lucidi, V., & Castaing, D. (2004). Le cholangiocarcinome intra-hépatique. *Journal de Chirurgie*, 141(5), 315-321.
- Gillet, M., Favre, S., Fontolliet, C., Halkic, N., Manton, G., & Heyd, B. (1999). Monolobar Caroli disease. About 12 cases. *Surgery*, 124 (1), 13-19.



17. AL BOUZIDI, A., LEZREK, M., KABIRI, H., ZRAZA, I., BOUMDIN, H., RIMANI, M., ... & BENOMAR, S. (1997). MALADIE DE CAROLI A PROPOS D'UN CAS LOCALISÉ AU LOBE GAUCHE AVEC REVUE DE LA LITTÉRATURE. *Médecine du Maghreb*, 65.
18. Bockhorn, M., Malagó, M., Lang, H., Nadalin, S., Paul, A., Saner, F., ... & Broelsch, C. E. (2006). The role of surgery in Caroli's disease. *Journal of the American College of Surgeons*, 202(6), 928-932.
19. Ros, E., Navarro, S., Bru, C., Gilabert, R., Bianchi, L., & Bruguera, M. (1993). Ursodeoxycholic acid treatment of primary hepatolithiasis in Caroli's syndrome. *The Lancet*, 342(8868), 404-406.
20. Caroli-Bosc, F. X., Demarquay, J. F., Conio, M., Peten, E. P., Buckley, M. J. M., Paolini, O., ... & Dumas, R. (1998). The role of therapeutic endoscopy associated with extracorporeal shock-wave lithotripsy and bile acid treatment in the management of Caroli's disease. *Endoscopy*, 30(06), 559-563.
21. Ciambotti, G. F., Ravi, J., Abrol, R. P., & Arya, V. (1994). Right-sided monolobar Caroli's disease with intrahepatic stones: nonsurgical management with ERCP. *Gastrointestinal endoscopy*, 40(6), 761-764.
22. McCarthy, J. H., Miller, G. L., & Laurence, B. H. (1990). Cannulation of the biliary tree, cystic duct and gallbladder using a hydrophilic polymer-coated steerable guide wire. *Gastrointestinal endoscopy*, 36(4), 386-389.
23. Ulrich, F., Steinmüller, T., Settmacher, U., Müller, A. R., Jonas, S., Tullius, S. G., & Neuhaus, P. (2002, September). Therapy of Caroli's disease by orthotopic liver transplantation. In *Transplantation proceedings* (Vol. 34, No. 6, pp. 2279-2280).
24. Mabrut, J. Y., Partensky, C., Jaeck, D., Oussoultzoglou, E., Baulieux, J., Boillot, O., ... & Gigot, J. F. (2007). Congenital intrahepatic bile duct dilatation is a potentially curable disease: long-term results of a multi-institutional study. *Annals of surgery*, 246(2), 236-46.
25. Mannai, S., Kraiem, T., Gharbi, L., Haoues, N., Mestiri, H., & Khalfallah, MT (2006, July). Congenital cystic dilations of the bile ducts. In *Annals of Surgery* (Vol. 131, No. 6-7, pp. 369-374). Elsevier Masson.
26. Ammori, B. J., Jenkins, B. L., Lim, P. C., Prasad, K. R., Pollard, S. G., & Lodge, J. P. A. (2002). Surgical strategy for cystic diseases of the liver in a western hepatobiliary center. *World journal of surgery*, 26, 462-469.
27. Waechter, F. L., Sampaio, J. A., Pinto, R. D., Alvares-da-Silva, M. R., Cardoso, F. G., Francisconi, C., & Pereira-Lima, L. (2001). The role of liver transplantation in patients with Caroli's disease. *Hepato-gastroenterology*, 48(39), 672-674.
28. Takatsuki, M., Uemoto, S., Inomata, Y., Egawa, H., Kiuchi, T., Hayashi, M., ... & Tanaka, K. (2001). Living-donor liver transplantation for Caroli's disease with intrahepatic adenocarcinoma. *Journal of Hepato-Biliary-Pancreatic Surgery*, 8(3), 284-286.