

## Bar Attachment Retained Mandibular Complete Denture

Wadii Bembli<sup>1\*</sup>, Narjes Hssan<sup>1</sup>, Najla Taktak<sup>1</sup><sup>1</sup>University Hospital Farhat Hached, Sousse, TunisiaDOI: [10.36347/sasjs.2023.v09i04.027](https://doi.org/10.36347/sasjs.2023.v09i04.027)

| Received: 14.03.2023 | Accepted: 25.04.2023 | Published: 29.04.2023

**\*Corresponding author:** Wadi Bembli

University Hospital Farhat Hached, Sousse, Tunisia

**Abstract****Case Report**

The complete mandibular prosthesis constitutes a challenge for the practitioner. Unfavorable anatomic-physiological factors, including the small bearing surface and the extent of resorption, often compromise prosthetic retention. The exploitation of residual roots as a support for the conjunction bar constitutes an excellent additional mechanical means of retention. This prosthetic alternative considerably improves the comfort and masticatory coefficient of the patient on condition that the imperatives of root conservation as well as the clinical and laboratory implementation techniques are respected.

**Keywords:** overdenture, residual roots, connective bar.

Copyright © 2023 The Author(s): This is an open-access article distributed under the terms of the Creative Commons Attribution 4.0 International License (CC BY-NC 4.0) which permits unrestricted use, distribution, and reproduction in any medium for non-commercial use provided the original author and source are credited.

### INTRODUCTION

The complete denture presents numerous drawbacks related to its removability and bulkiness; the support surface promotes, due to the depressibility of the mucosa and the disappearance of the periodontal proprioception, a prosthetic imbalance and a reduced chewing efficiency [1]. This phenomenon is exacerbated at the mandibular level given the unfavorable anatomic-physiological context in relation to the importance of resorption, the reduced support surface, the presence of the tongue as well as the importance of salivary flow [2, 3].

The supraradicular complete removable prosthesis when the situation permits, is an interesting alternative, especially when additional means of retention are provided [4]. For this purpose, the conjunction bar is one of the devices of choice with many advantages and whose implementation is well codified. The supraradicular complete removable prosthesis on bar is a prosthesis with additional retention, often considered in cases of complete mandibular edentulism.

When treating subtotal mandibular edentulism, it is desirable to use the roots of residual anterior teeth as a support for prosthetic retainers. This alternative is possible whenever the roots under consideration are sufficiently spaced between them for effective prophylaxis and can be preserved endodontically and

periodontally with a bone implantation of at least 8 to 10 mm [5].

Through a clinical case we will present in this work, the different stages of clinical and laboratory realization to be adopted when using the anchoring bar as a secondary retention system in a complete mandibular prosthesis.

### CASE REPORT

A patient who consulted us with subtotal mandibular edentulousness, only the canines are present, without clinical mobility. The patient is aesthetically and functionally demanding.

Examination of the osteomucosal surfaces shows a high, broad ridge covered with adherent fibromucosa and moderately formed piriform eminences.

The study phase is an essential prerequisite, it allows to analyze and validate the prosthetic project from an aesthetic and functional level.

Therefore, a mounting of the study models on an articulator makes it possible to analyze the inter-ridge relationships and to evaluate the height necessary for a good integration of the attachments and the prosthetic teeth within the framework of a suitable aesthetic.

The Canines have long roots, with good bone anchorage. The endodontic preparation is performed followed by a tight filling of the 33 and 43.

Prosthetic phases: Peripheral juxta gingival preparation with a peripheral leave of 1.5 mm which follows the shape of the gingival festoon.

- Occlusal tray with 1mm thick residual walls
- Ovoid preparation of the canal entry orifice
- Canal preparation at 2/3 of the root and leaving 4 mm of obturation apically.

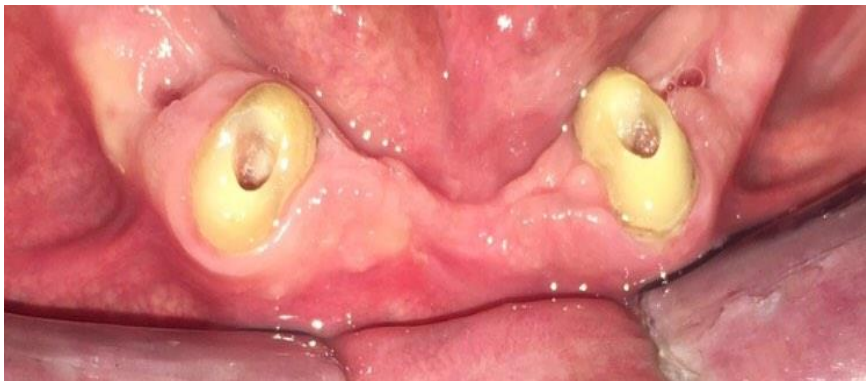A parallelism between the drillings of the two support teeth of the connecting bar is sought.

Residual teeth impression: The impression of the root copings is made using the classic double-mix impression technique: a low-viscosity silicone is injected into the canal, stakes are placed in the root housing, and a high-viscosity silicone is charged in the intrados of the individual impression tray.

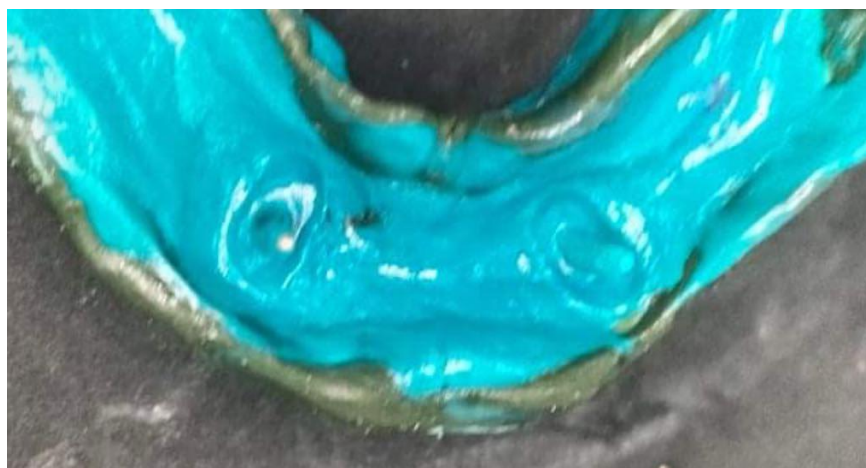
After casting, the Ackermann bar is produced in the laboratory, respecting the space reserved for the assembly of the prosthetic teeth

After validating the adaptation of the bar in the mouth, Casting of the bar and try-in in the mouth while checking insertion, adaptation, retention and spacing (1 to 1.5 mm) in relation to the top of the ridge.

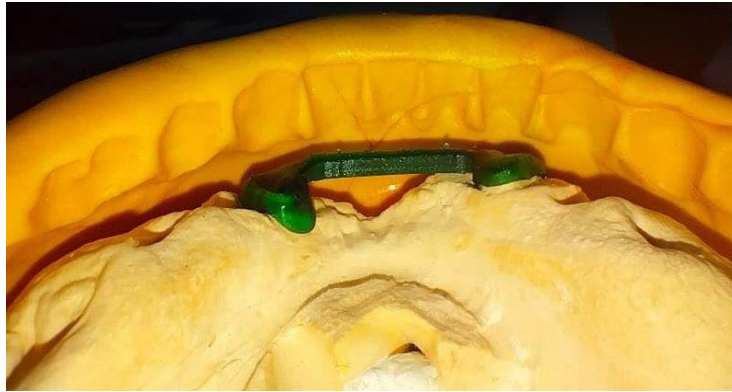
- The mouthing stage, a key stage in the success of the prosthetic treatment
- After occlusal equilibration and elimination of overextension of the prosthetic edges, the connection of the bar was made with a rider in the intrados of the prosthesis
- A hollowing out of the intrados by a light silicone-type developer was carried out
- The connection is made by the direct method with cold resin under occlusal pressure
- After taking the resin, we polish it and we give the necessary recommendations for the patient
- The retentive contribution is considerable compared to a conventional total prosthesis



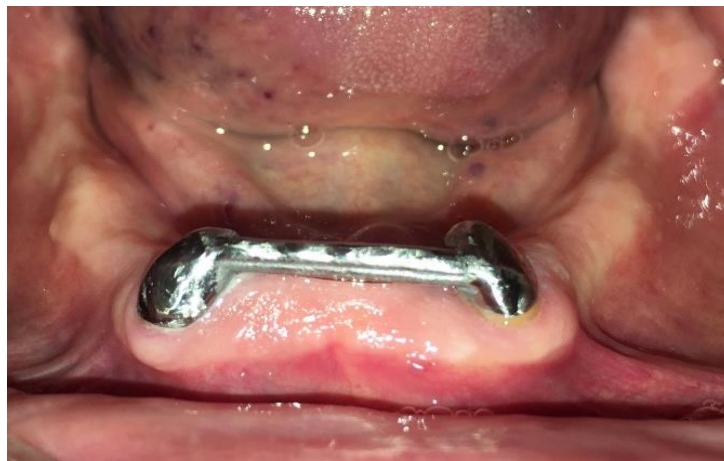**Fig 1: Preparation for Richmond crown after endodontic treatment**



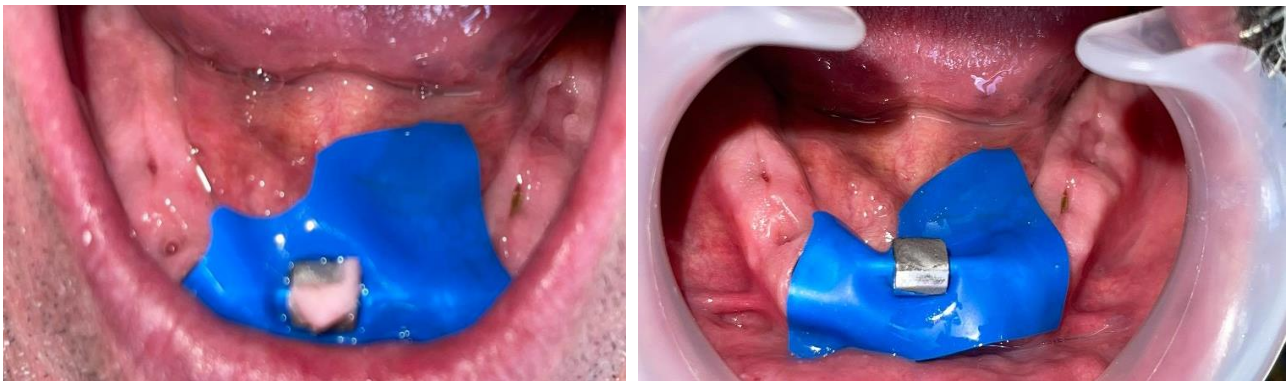
**Fig 2: Imprint of preparations using the simultaneous double-mix technique**



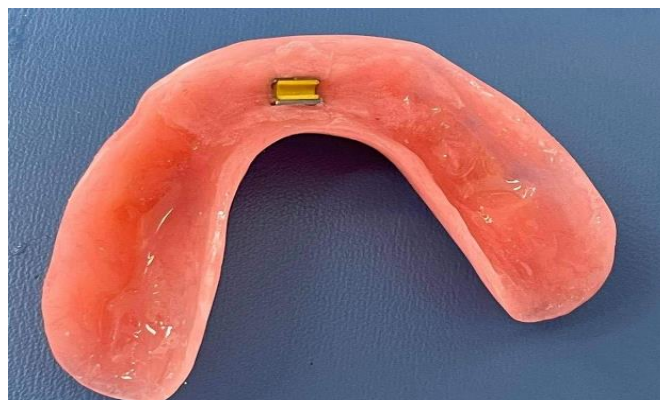
**Fig 3: Sculpture of the ackermann bar (silicone key in place)**



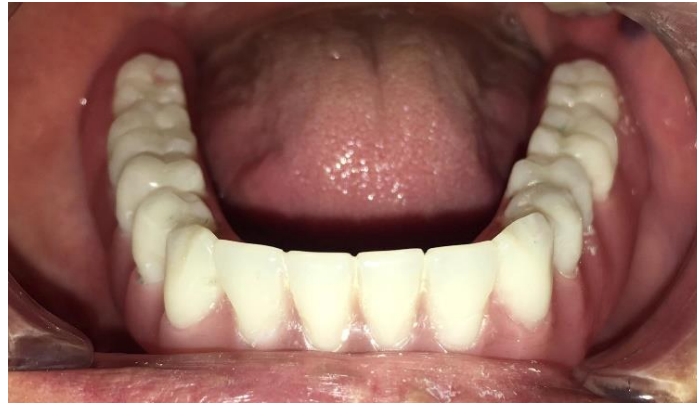**Fig 4: Ackermann bar in the anterior crest**



**Fig 5: The attachment of female part, which is retained in prosthesis under occlusal pressure**



**Fig 6: The intrados of the prosthesis**



**Fig 7: Prosthesis in the mouth**

## DISCUSSION

The Bar is a sturdy, cast metal retainer that connects multiple arch roots. It is surmounted by a device (gutter or bridge) which ensures the retention of the prosthesis by friction on the parallel walls of the bar, and which is secured to the prosthetic intrados by resin [3, 4].

There are several types of bar of different sizes ranging from 2.7 to 4.5mm for bar height and retention device [5]. It is preferred to axial attachments (press button) whenever the attachment of the teeth to each other is possible [6]. When isolated roots distributed symmetrically persist on the arch, their conservation and joining by means of a bar makes it possible to solve many problems of order:

- Aesthetics: it thus avoids the rupture of the false gum, the disharmony of color of shape of dimension and position [7].
- Biomechanical: it increases retention and prevents the prosthesis from tilting around the pillars if they are kept as hook supports [7, 8].
- Periodontal: when the periodontal support is reduced, the section of the coronal part of the tooth eliminates the unfavorable lever arm and reduces the constraints undergone during mastication [9, 10].

In addition, the use of the conjunction bar makes it possible to solidarize the roots ensuring their containment and optimizing the distribution of forces [11]. In addition, the supraradicular prosthesis has advantages:

Maintenance of bone capital by avoiding the process of alveolar resorption, maintenance of periodontal proprioception, patients using supra-root prostheses maintain masticatory efficiency of up to 90% [12, 13]. Indeed, proprioception plays an important role in the programming of the masticatory cycle, in the activity of the masseters and the coordination is more effective [14, 15].

## CONCLUSION

The conservation and exploitation of residual roots (when they meet certain conditions) is of major interest in the aesthetic and functional improvement of complete removable prostheses.

The anchorage bar constitutes the complementary means of retention of choice at the mandibular level provided that

Correctly place the indication and scrupulously respect the stages of realization.

## REFERENCES

1. Rignon-Bret, C., Rignon-Bret, J. M. (2002). Intérêt et conception des prothèses amovibles supra-radicaux. In: Prothèse amovible complète. Prothèse immédiate, prothèse supraradicaux et implantaire. Reuil-Malmaison: Éditions CdP, 177-186.
2. Gibert, Y., Soulet, H., & Blandin, M. (1987). Phénomènes rétentifs en prothèse adjointe complète. *Encycl Méd Chir (Paris, France), Odontologie*, 23325, B05.
3. Mishra, R., Shivrayan, A., Jain, S., & Mehta, S. (2014). Fabrication of bar-retained tooth-supported mandibular overdenture. *International Journal of Oral Health Sciences*, 4(1), 37-41.
4. Shah, F. K., Gebreel, A., hamed Elshokouki, A., Habib, A. A., & Porwal, A. (2012). Comparison of immediate complete denture, tooth and implant-supported overdenture on vertical dimension and muscle activity. *The Journal of Advanced Prosthodontics*, 4(2), 61-71.
5. Devi, J., Goyal, P., Verma, M., Gupta, R., & Gill, S. (2019). Customization of attachments in tooth supported overdentures: Three clinical reports. *Indian Journal of Dental Research*, 30(5), 810-815.
6. Singh, K., Gupta, N., Kapoor, V., & Gupta, R. (2013). Hader bar and clip attachment retained mandibular complete denture. *Case Reports*, 2013, bcr2013010401.

7. Fromentin, O. (2003). Critères de choix des systèmes d'attachements en prothèse amovible complète supra-implantaire (PACSI). *Réalités cliniques*, 14(2), 161-171.
8. Rignon-Bret, J. M., & Pompignoli, M. (1989). La barre de rétention contra-muqueuse en prothèse complète mandibulaire. Éditions CdP, 68, 57-70.
9. Gibert, Y., & Soulet, H., & Blandin, M. (1987). Phénomènes rétentifs en prothèse adjointe complète. *Encycl Méd Chir (Paris, France), Odontologie*, 23325 B05, 4-1987, 6p.
10. Amzalag, G., Batarec, E., Schoendorff, R., Buch, D., & Assemat-Tessandier, X. (1988). Prothèses supraradiculaires «overdentures». Paris: Éditions CdP.
11. Assemat-Tessandier, X. (2000). La prothèse supraimplantaire mandibulaire: les boutons-pressions. *Implant*, 2, 114-122.
12. Unger, F., Hoornaert, A., & Estrabaud, Y. (1998). Indication et mise en œuvre des attachements axiaux supra-radicaux. *Réalités Cliniques*, 9(4), 513-523.
13. Martini, L. F. (1992). Attachements et prothèse composite. Paris: Masson, 67-74, 89-93.
14. Blanc, J., Blum, J. Y., & Isnard, L. (2002). Protheses totales amovibles de recouvrement sur implants Mode de retention associant barre de connexion et silicone. *Cahiers De Prothese*, 27-34.
15. Fromentin, O. (2003). Critères de choix des systèmes d'attachements en prothèse amovible complète supra-implantaire (PACSI). *Réalités cliniques*, 14(2), 161-171.