

Trichoepithelioma of Upper Eyelid: A Case Report

Sumit Jain¹, Nikhil Makkar¹, Chetan Singla¹, Ashutosh Talwar^{2*}

¹Department of Plastic Surgery, Guru Gobind Singh Medical College and Hospital (GGSMCH), Sadiq Rd, Kotakpura, GGS Medical Hospital, Faridkot, Punjab 151203, India

²Department Of General Surgery, Guru Gobind Singh Medical College and Hospital (GGSMCH), Sadiq Rd, Kotakpura, GGS Medical Hospital, Faridkot, Punjab 151203, India

DOI: [10.36347/sasjs.2023.v09i06.022](https://doi.org/10.36347/sasjs.2023.v09i06.022)

| Received: 18.05.2023 | Accepted: 22.06.2023 | Published: 26.06.2023

*Corresponding author: Ashutosh Talwar

Department Of General Surgery, Guru Gobind Singh Medical College and Hospital (GGSMCH), Sadiq Rd, Kotakpura, GGS Medical Hospital, Faridkot, Punjab 151203, India

Abstract

Case Report

Solitary trichoepithelioma is a rare benign adnexal tumour of hair follicles, especially over the upper eyelid. Reconstruction in these cases has not been discussed in the literature. We are reporting a case of a 60-year-old male patient with trichoepithelioma of the upper eyelid involving 70% of the upper eyelid which was managed by primary closure; thus avoiding unnecessary extensive and time-consuming reconstructive procedures.

Keywords: Trichoepithelioma, upper eyelid, anterior lamella, reconstruction.

Copyright © 2023 The Author(s): This is an open-access article distributed under the terms of the Creative Commons Attribution 4.0 International License (CC BY-NC 4.0) which permits unrestricted use, distribution, and reproduction in any medium for non-commercial use provided the original author and source are credited.

INTRODUCTION

Solitary trichoepithelioma is a rare benign tumour of hair follicles with eyelid trichoepitheliomas being even rarer with less than 30 cases reported so far in the world [1-6]. Basal cell carcinoma is the most common tumour of the eyelid constituting 90% of cases [3]. Clinical examination alone cannot clinch the diagnosis and histopathological examination is required to confirm the diagnosis and to rule out basal cell carcinoma [3, 5, 6]. Primary closure of the defect is possible in cases of trichoepithelioma as compared to basal cell carcinoma due to its peculiar features. We are reporting a case of trichoepithelioma of the upper eyelid presenting as mass over the upper eyelid which was managed by excision and primary closure.

CASE REPORT

A 60-year-old male patient presented to the Plastic Surgery OPD of our hospital with a complaint of mass over the left upper eyelid for 15 years (Fig 1). It was small and painless initially but gradually progressed to its present size over 4-5 years. The patient has no history of trauma, bloody discharge, weight loss or loss of appetite. There is no significant past and family history.

On examination, there was an irregular nodular mass involving 70 % of the upper eyelid. It was firm,

non-tender, and mobile from side to side. Eye examination was normal except for the mass over the eyelid. Eyelashes were absent beneath the involved area of the eyelid. Underlying palpebral conjunctiva was not involved.

Excision of mass was done under local anaesthesia. Primary closure of the defect was done (Fig 1a) and a biopsy specimen was sent for histopathological examination. The postoperative period was uneventful. The patient was able to open and close his eyes normally after the surgery (Fig 1 b and c). Scar line merged with the folds of the eyelid and there was not any donor site morbidity (Fig 1c). The biopsy report described it to be trichoepithelioma. There is no recurrence on follow-up of 6 months.

Histopathologically, a biopsy revealed the epidermal lining exhibiting focal thinning. The dermis showed a basaloid tumour arranged in the form of variably sized nests along with the presence of numerous keratin horn cysts. These cells were round to oval, compactly placed, hyperchromatic, to vesicular nuclear chromatin, and had a scant amount of cytoplasm, with indistinct cell boundaries. Peripheral palisading was also noted. The little intervening stroma was fibrotic. These findings are consistent with a diagnosis of trichoepithelioma (Fig 1d).

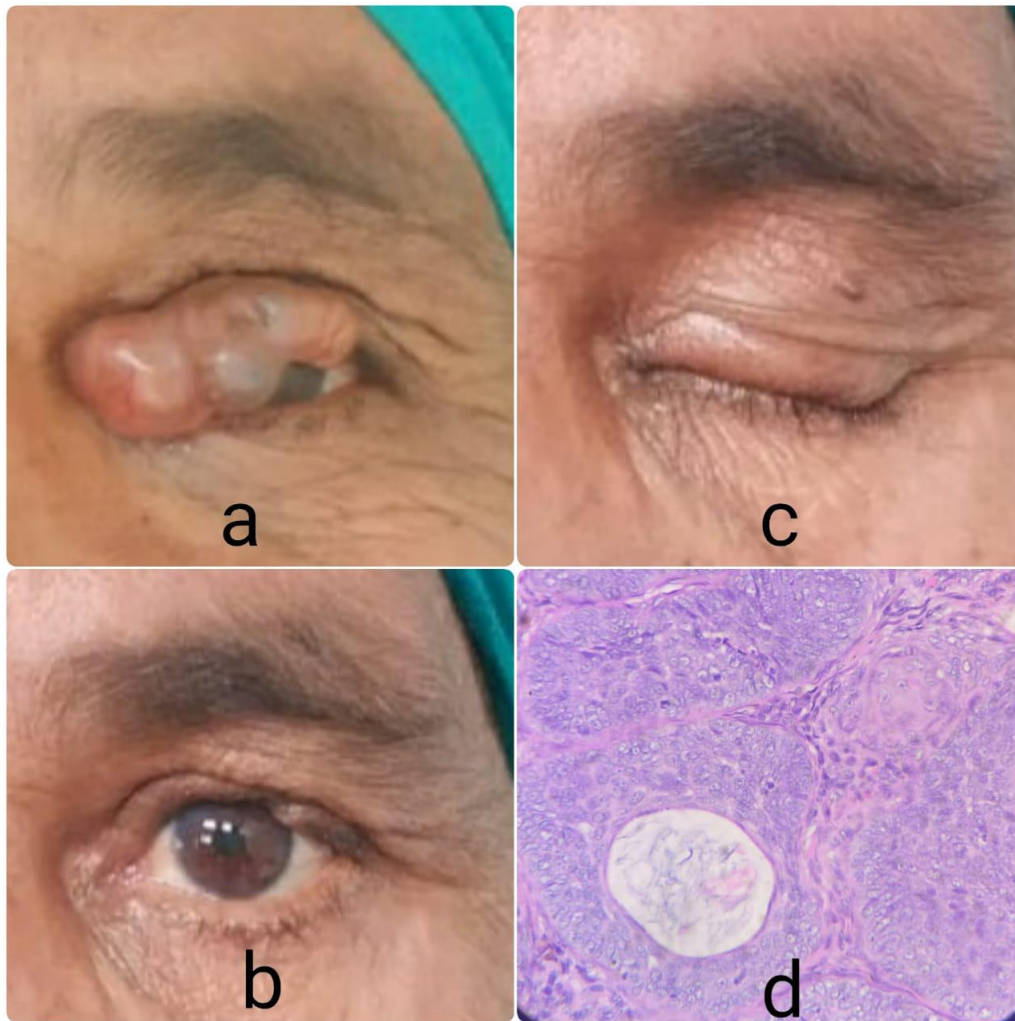


Figure 1: a) Preoperative image of a patient with a tumour of upper eyelid b) Postoperative image with an eye open c) Postoperative images with eyes closed d) High power micro field(400x) shows fibrous stroma with basaloid cells and keratin horn cysts suggestive of trichoepithelioma

DISCUSSION

Trichoepithelioma of the upper eyelid is a rare benign adnexal tumour that arises from hair follicles. They are classified into three variants: Solitary, multiple, and desmoplastic [2]. Multiple are more common than solitary and are usually inherited as autosomal dominant [3]. Solitary trichoepitheliomas do not follow any inheritance pattern and are most commonly present on the face [1].

Our case report is about the uncommon location of trichoepithelioma which is the upper eyelid. Gray and Helwig found only 1 case of solitary trichoepithelioma in their large case series of 83 trichoepitheliomas [1]. In a large study of 2529 eyelid lesions by Ozdal in 2003, only 3 cases were of trichoepithelioma [4].

Usually, defects larger than 50% of the size of the upper eyelid require flap reconstruction but in these cases, primary closure of the defect was possible due to the presence of an extra fold of skin in addition to

dermatochalasis. A similar feature of the extra fold of skin was reported in 2015 by Gupta A *et al.*, [8].

Solitary trichoepitheliomas are usually confused with BCC. Their differentiation is clinically important as BCC requires excision of 5 mm of healthy tissue but trichoepithelioma does not require excision of any healthy tissue, thereby altering the approach for reconstructive options [1, 5, 6]. Therefore solitary trichoepithelioma should also be kept in mind as a differential diagnosis while dealing with eyelid masses.

CONCLUSION

Trichoepithelioma of the upper eyelid is a rare benign tumour of the eyelid. Preoperative diagnosis can be challenging owing to the uncommon nature of the disease and its similarity to BCC. Primary closure of defects is possible in cases of trichoepithelioma due to nonrequirement of wide local excision and the presence of extra fold of skin secondary to dermatochalasis. Therefore, this tumour should be kept in mind while dealing with eyelid tumours to avoid unnecessary

extensive or time-consuming wide excision, reconstruction, and its complications.

REFERENCES

1. Ricoy, J. R., Ledesma, G., Monescillo, J., & JP, G. T. (2002). Benign hair-follicle derived eyelids tumors in adults. *Archivos de la Sociedad Espanola de Oftalmologia*, 77(11), 605-610.
2. Kuo, D. S., & Nyong'o, O. L. (2010). Congenital solitary eyelid trichoepithelioma. *Journal of American Association for Pediatric Ophthalmology and Strabismus*, 14(3), 277-279.
3. Gray, H. R., & Helwig, E. B. (1963). Epithelioma adenoides cysticum and solitary trichoepithelioma. *Archives of Dermatology*, 87(1), 102-114.
4. Özdal, P. Ç., Callejo, S. A., Codère, F., & Burnier Jr, M. N. (2003). Benign ocular adnexal tumours of aocrine eccrine or hair follicle origin. *Canadian journal of ophthalmology*, 38(5), 357-363.
5. Simpson, W., Garner, A., & Collin, J. R. (1989). Benign hair-follicle derived tumours in the differential diagnosis of basal-cell carcinoma of the eyelids: a clinicopathological comparison. *British journal of ophthalmology*, 73(5), 347-353.
6. Aurora, A. L. (1974). Solitary trichoepithelioma of the eyelid. *Indian J Ophthalmol*, 22, 32-33.
7. Subramanian, N. (2011). Reconstructions of eyelid defects. *Indian journal of plastic surgery: official publication of the Association of Plastic Surgeons of India*, 44(1), 5-13.
8. Gupta, A., Ali, M. J., Mishra, D. K., & Naik, M. N. (2015). Solitary trichoepithelioma of the eyelid: a clinico-pathological correlation. *International Journal of Trichology*, 7(2), 80-81.