

Acute Suppurative Thyroiditis in a Pediatric Patient: A Case Report

Daniel Manzano^{1*}, Laura González², Lorena Narváez³

¹Specialist in Pediatric Surgery at the Hospital de Especialidades de Fuerzas Armadas N°1 Quito-Ecuador

²Pediatric Surgery Specialist at the Hospital Instituto Ecuatoriano de Seguridad Social Quito-Sur

³Resident Physician of the Pediatric Department of the Hospital de Especialidades de Fuerzas Armadas N°1 Quito-Ecuador

DOI: [10.36347/sasjs.2023.v09i07.003](https://doi.org/10.36347/sasjs.2023.v09i07.003)

| Received: 01.06.2023 | Accepted: 04.07.2023 | Published: 19.07.2023

*Corresponding author: Daniel Manzano

Specialist in Pediatric Surgery at the Hospital de Especialidades de Fuerzas Armadas N°1 Quito-Ecuador

Abstract

Case Report

Acute suppurative thyroiditis is a rare pathology in children, which requires a timely diagnosis and early empirical antibiotic treatment, otherwise it may lead to septicemic episodes and deterioration of the patient's general condition. Its diagnosis is initially clinical and is confirmed by complementary imaging studies such as ultrasound, tomography and barium esophagogram in case of recurrences to rule out anatomical alterations. Surgical treatment should be reserved for cases in which there is a poor response to antibiotic treatment.

Keywords: acute suppurative thyroiditis, children, thyroiditis in pediatrics.

Copyright © 2023 The Author(s): This is an open-access article distributed under the terms of the Creative Commons Attribution 4.0 International License (CC BY-NC 4.0) which permits unrestricted use, distribution, and reproduction in any medium for non-commercial use provided the original author and source are credited.

INTRODUCCIÓN

Acute suppurative thyroiditis is an infrequent pathology in children, since the thyroid gland is resistant to infections, due to its high vascularity, presence of iodine and hydrogen peroxide in its tissue, besides being an encapsulated and independent organ [1]. It can also be associated with the presence of pyriform sinus fistulas (96%), especially to the left lobe [2]. Diagnosis is clinical by the appearance of a painful cervical lump, which intensifies with swallowing and/or neck movement, accompanied by signs of local and systemic inflammation [3].

In the other paraclinical studies there is leukocytosis with left shift (53%) and elevated sedimentation rate [3]. The presence of a thyroid collection or abscess, visualized by ultrasound and/or computed tomography (CT) confirms the diagnosis. But it is necessary to define the existence of a pyriform sinus fistula through an esophagogram [4]. Its treatment is based on broad-spectrum antimicrobials, in addition to the use of non-steroidal anti-inflammatory drugs; surgical management is required in up to 85% of cases [5].

CLINICAL CASE

A 5-year-old female patient with a history of untreated pica (ingestion of creams). She presents a left cervical mass, apparently due to the ingestion of wild snails 8 days before. It is accompanied by odynophagia

and dysphagia. On the fourth day she presented thermal elevation, headache, hyporexia in addition to the persistence of the cervical mass, so she went to the emergency room. Physical examination: temperature of 38°, tachycardic, left cervical mass of 4 cm x 3 cm, painful on palpation, non-mobile (Figures 1 and 2). The rest of the physical examination was unaltered.

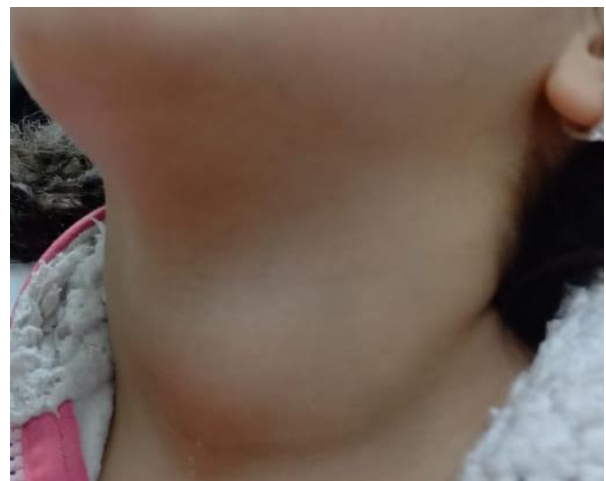


Figure 1: Left lateral aspect of the neck with presence of swelling

Source: Dr. Lorena Narváez

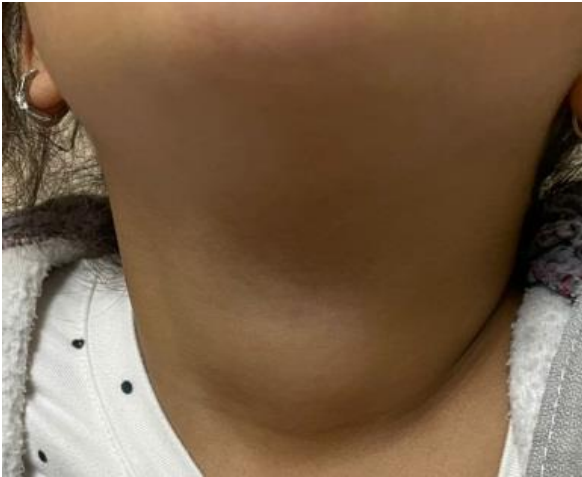

Figure 2: Frontal face of neck with presence of swelling.

Source: Dr. Lorena Narváez

Admission laboratory tests show leukocytosis with neutrophilia, elevated CRP, normal sedimentation rate and normal thyroid hormones (Table 1).

Table 1: Laboratory results at admission

| Hematology | Thyroid Function |
|-------------------------|------------------|
| Leukocytes 12.08 | TSH 0.83 |
| Neutrophils 70.6% (8.5) | FT4 1.20 |
| Lymphocytes 21% (2.5) | T3 86.57 |
| VSG 7 | TORCH negative |
| PCR 5.19 PCT 0.16 | |

Cervical ultrasound reported an enlarged thyroid gland at the expense of the left lobe with a volume of 10.3 ml and the presence of a 10 ml abscess, in addition to inflammatory nodes in the left IV level (Figures 3 and 4).

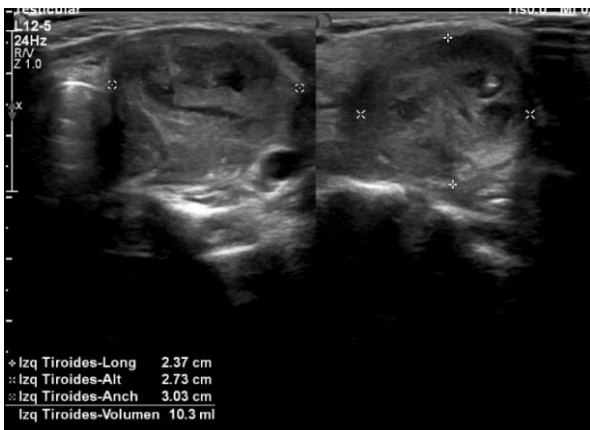


Figure 3: Thyroid abscess in left lobe 10 ml volume (*).

Source: Imaging Service HE1

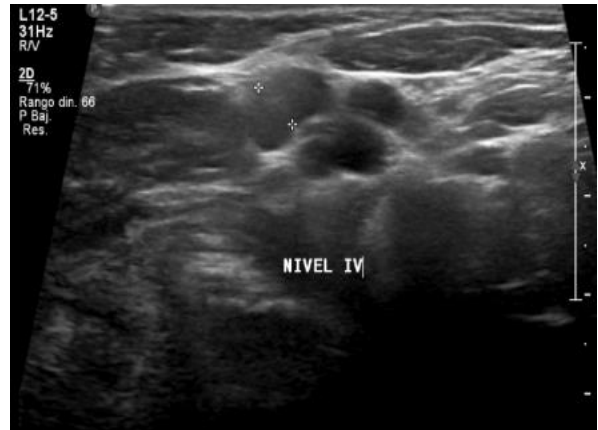

Figure 4: Inflammatory cervical adenopathy level IV left (*).

Source: Imaging Service HE1

She started antibiotic therapy with intravenous ceftriaxone (100 mg/kg/dose) every 12 hours, intravenous clindamycin (40mg/kg/day) every 6 hours, she completed 10 days of treatment; she received albendazole 400mg oral single dose and metronidazole 30 mg/kg/day every 8 hours for 5 days (due to ingestion of wild snails). Esophagogram was performed, which ruled out the presence of fistula. With a normal infectious profile, associated with clinical improvement, she was discharged for outpatient control with antibiotic treatment for 10 days based on cefpodoxime 100 mg orally every 12 hours and clindamycin 300 mg orally every 6 hours (Figure 5 and 6). The control cervical ultrasound reports: reduction of the abscess to 2 ml surrounded by a thick capsule (Figure 7).

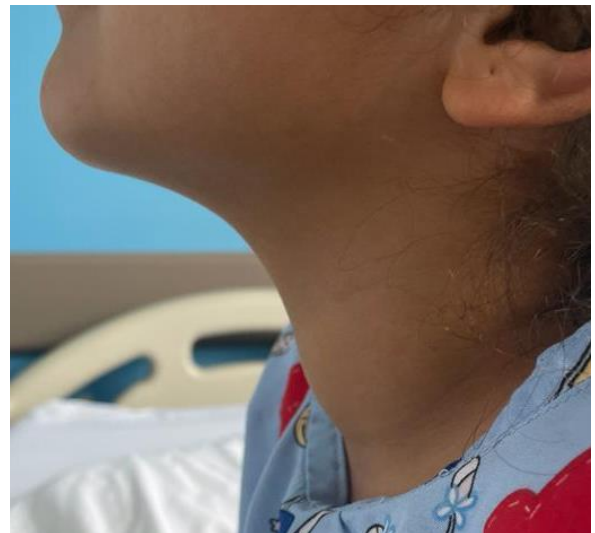

Figure 5: Left lateral aspect of the neck with decreased swelling.

Source: Dr. Lorena Narváez

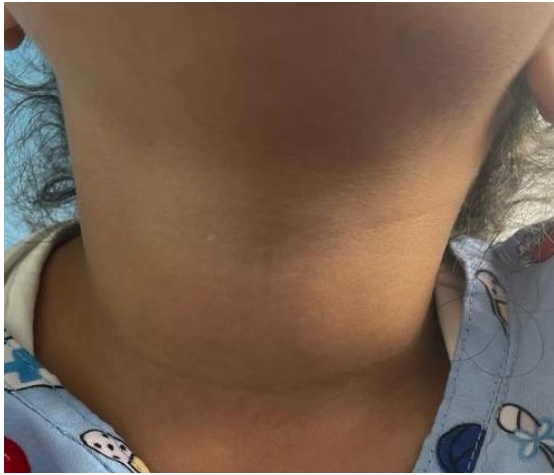

Figure 6: Anterior face of the neck with decreased swelling

Source: Dr. Lorena Narváez

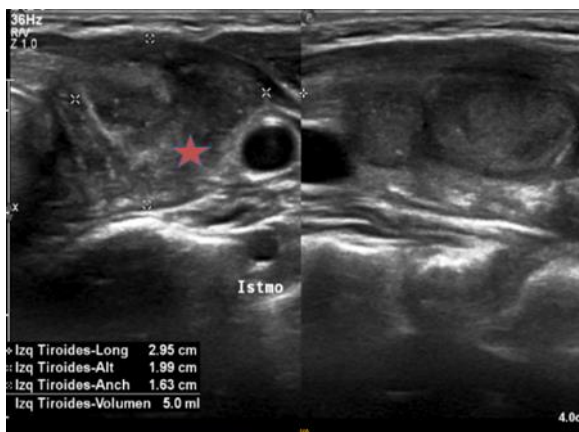


Figure 7: Thyroid lesion reduction 2 ml volume (*)

Source: Imaging Service HE1

She was reevaluated one month after discharge with cervical ultrasound that reported: asymmetric thyroid gland without occupying lesions, with a 1.2 cm residual lesion (scar), without evidence of inflammatory process (Figure 8).

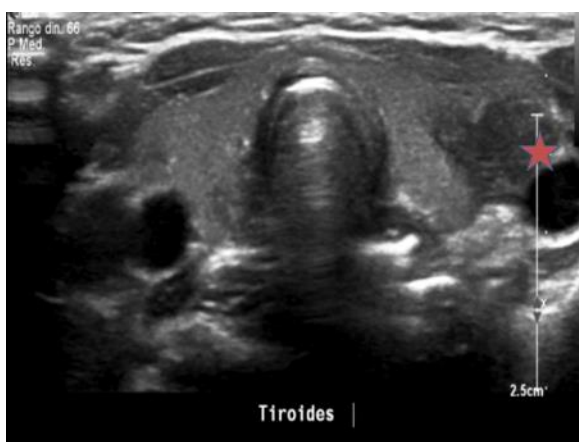

Figure 8: Lesion reduction to 1.2 cm diameter (*)

Source: Imaging Service HE1

DISCUSSION

Acute suppurative thyroiditis is an infrequent pathology in pediatrics; it is estimated to correspond to 0.1 - 0.7% of thyroid diseases and carries a 12% mortality rate if untreated [5]. However, certain embryological remnants such as the persistence of the thyroglossal duct or the pyriform sinus fistula can also cause this pathology due to the communication (mainly of the left lobe) with the airway, predisposing to recurrent acute thyroiditis [6]. Clinically it is characterized by pain (90%) of cases, presence of painful tumor mass on palpation (100%), warmth, flushing, soft tissue edema (83%), pain on neck mobilization and dysphagia. Our patient presented a left cervical mass painful on neck mobility accompanied by general malaise as a possible cause of ingestion of wild snails. The laboratory shows leukocytosis and elevation of acute phase reactants. Thyroid function is usually normal as observed in the case presented, with transient or permanent hypothyroidism in 2-3 % and thyrotoxicosis triggered by glandular inflammation leading to the release of thyroid hormones in 5 % [6].

The definitive diagnosis is made by cervical ultrasound, which identifies solid and/or cystic lesions, heterogeneous areas corresponding to local inflammation, and characterizes the location and extent of the abscess. The cervical tomography determines the degree of involvement of the thyroid gland, and eventually the presence of air caused by a fistula. In cases of recurrence, esophagogram can detect pyriform sinus fistulas with a sensitivity (50%-80%) [6,7]. In the case of our patient only thyroid ultrasound was performed to assess the evolution of the picture, finding a decrease in the size of the abscess with signs of resolution and improvement of inflammatory parameters, so additional studies were not considered.

Treatment is by intravenous administration of broad-spectrum antibiotics and non-steroidal anti-inflammatory drugs. The most frequently reported etiological agents have been streptococci, staphylococci, pneumococci, salmonellae, bacteroides. Therefore, in our case antibiotic therapy based on third generation cephalosporin (ceftriaxone) combined with clindamycin was used. However, due to a history of ingestion of wild snails, antiparasitic coverage was completed with albendazole and metronidazole for 5 days. The satisfactory response to the antibiotics used suggests the presence of microorganisms sensitive to the established medication, so it was not necessary to rotate antibiotic therapy or surgical resolution, complementing outpatient antibiotic treatment receiving a total of 20 days of antibiotic therapy. The evolution with adequate treatment is almost always satisfactory, but there may be recurrences in case of pyriform sinus fistula or thyroglossal cyst, being necessary to investigate this by performing an esophagogram with barium.

CONCLUSION

Acute suppurative thyroiditis is an infrequent pathology that requires a timely diagnosis and early antibiotic treatment through which resolution of the picture can be obtained without requiring surgical treatment and in case of recurrence is complemented with esophagogram study to rule out the presence of fistulas. Conflicto de intereses. This article does not present any type of conflict of interest between the authors.

REFERENCES

1. Lee, S. F. P., & Li, Y. W. (2002). Clinical characteristics and management of acute suppurative thyroiditis in children. *J Formos Med Assoc*, 101(7), 468-71.
2. Valle, S.S., Papendieck, P., Masnata, M.E., Elías, E., Torrado, L., Bergadá, I. (2002). Endocrinología Infantil de referencia.
3. Chi, H., Lee, Y. J., Chiu, N. C., Huang, F. Y., Huang, C. Y., Lee, K. S., ... & Shih, B. F. (2002). Acute suppurative thyroiditis in children. *The Pediatric infectious disease journal*, 21(5), 384-387.
4. Lammers, D., Campbell, R., Davila, J., & MacCormick, J. (2018). Bilateral Piriform sinus fistulas: a case study and review of management options. *Journal of Otolaryngology-Head & Neck Surgery*, 47, 1-6.
5. Majety, P., & Hennessey, J.V. (2000). Acute and Subacute, and Riedel's Thyroiditis. En: Feingold KR, Anawalt B, Blackman MR, Boyce A, Chrousos G, Corpas E, editores. Endotext [Internet]. South Dartmouth (MA): MDText.com, Inc.; [citado 12 de junio de 2023]. Disponible en: <http://www.ncbi.nlm.nih.gov/books/NBK285553/>
6. She, X., Zhou, Y. N., Guo, J., & Yi, C. (2022). Clinical Analysis of Acute Suppurative Thyroiditis in 18 Children. *Infection and Drug Resistance*, 4471-4477.
7. Yang, H., Li, D., Ye, X., Cheng, J., Jia, Z., Huang, X., ... & Xu, Y. (2020). Aspiration with or without lavage in the treatment of acute suppurative thyroiditis secondary to pyriform sinus fistula. *Archives of Endocrinology and Metabolism*, 64, 128-137.