

## Surgical Approach of Substernal Goiter

K. Ghebouli<sup>1\*</sup>, I. Manaa<sup>2</sup>, H. Larkem<sup>3</sup>, M. Belbekri<sup>3</sup>, M-A Kecir<sup>3</sup>

<sup>1</sup>Department of Cardiovascular Thoracic Surgery and Organ Transplantation CHU Mustapha Algiers, Algeria

<sup>2</sup>Department of Maxillofacial Surgery El Khroub Constantine, Algeria

<sup>3</sup>Department of Thoracic Surgery CHU Constantine, Algeria

DOI: [10.36347/sasjs.2023.v09i08.006](https://doi.org/10.36347/sasjs.2023.v09i08.006)

| Received: 05.07.2023 | Accepted: 08.08.2023 | Published: 11.08.2023

\*Corresponding author: K. Ghebouli

Department of Cardiovascular Thoracic Surgery and Organ Transplantation CHU Mustapha Algiers, Algeria

### Abstract

### Original Research Article

Substernal goiters are quite common; their diagnosis is mainly based on the CT scan which must be performed systematically in case of suspicion of intrathoracic extension of the goiter. The diagnosis of thoracic goiter requires surgical excision, most often by cervicotomy, more rarely by sternotomy. The arguments in favor of this surgical treatment are twofold: on the one hand the inevitable evolution towards phenomena compression; on the other hand, the risk of malignant transformation.

**Keywords:** Substernal goiter, CT scan, cervicotomy, combined approach, complications.

Copyright © 2023 The Author(s): This is an open-access article distributed under the terms of the Creative Commons Attribution 4.0 International License (CC BY-NC 4.0) which permits unrestricted use, distribution, and reproduction in any medium for non-commercial use provided the original author and source are credited.

## INTRODUCTION

The clinical definition of substernal goiter is not unanimous. In general, it is considered that it is a thyroid gland which has a part which remains permanently retrosternal during the examination of the neck without hyperextension [1, 2].

Several definitions have been proposed, the most commonly accepted is that of (Merlier and Eschapaspe), proposed at the French Congress of Surgery in 1971: "a substernal goiter is a cervical goiter whose lower pole protrudes at least three fingerbreadths beyond the upper edge of the manubrium sternal in the operative position, and which, in addition, requires a specific extraction maneuver, without which exteriorization of the thyroid is not possible [3, 4].

Due to a multitude of definitions, the true incidence of substernal goiters remains difficult to determine, and varies in the literature from 2% to 19% (White *et al.*, 2008) [5].

The same applies to the prevalence, which is also difficult to determine since the number of non-operated substernal goiters remains largely unknown. It is estimated to be present in 0.02% of the general population and 0.05% of women over 40 [6].

The management of Substernal goiters is special because of the size of the thyroid, its mediastinal

location, its anatomical relation with trachea and the vessels, and the choice of the surgical approach.

## METHODS

Between January 2014 and December 2022, the results of 106 operations performed patients with substernal goiter were examined in the thoracic surgery department.

Our patients benefited before their admission from a complete clinical examination, a standard chest X-ray, cervical echography, CT scan, and cardio-respiratory explorations (ECG, echocardiography, EFR), specific biological examinations (T<sub>4</sub>, TSH, calcemia) in addition to routine examinations, cytopuncture was performed in 32 cases.

In our series, a naso-fibroscope was systematically requested in order to detect a possible paralysis of the recurrent nerve.

We retained all the observations that fulfill one or more of these criteria: a non-palpable lower pole on clinical examination, a Substernal goiter on ultrasound, a plunging character on CT scan, a Substernal goiter discovered intraoperatively. We excluded goiters that did not have intraoperative confirmation of the plunging character (false plunging), and patients operated on for autonomous endothoracic goiter.

The variables analyzed were age, sex, history, functional signs, physical signs, the imaging data, the data of the intervention (approach, surgical difficulties, type of excision), and postoperative anatomopathological examination result. The average patient follow-up rate is 16 months.

## RESULTS

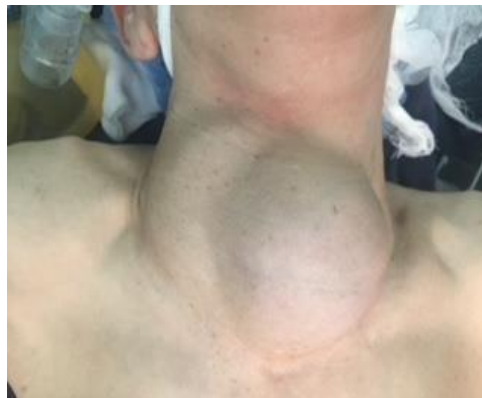Our study involved 106 patients with a clear female predominance; 88 women (83.01%) for 18 men (16.99%) with a male/female sex ratio of 1/5. The average age was 56.7 years with extremes of 47 to 74

years. In total, 19.81% of our patients had a family history of goiters.

We realize that the reason for consultation was mainly anterior cervical swelling associated with signs of compression, namely dyspnea; representing the main symptom present in 22.64% of cases; dysphagia in 16.98% of cases and dysphonia in 7.54% of cases, two patients (1.88%) presented a cave syndrome. In addition, goiter was asymptomatic in 10 cases (9.43%) (Table 1) (Fig 1).

**Table 1: Discovery circumstances of Substernal Goiter**

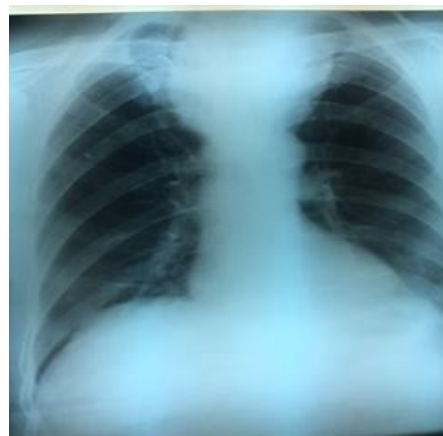| Symptom                    | Number n | Percentage |
|----------------------------|----------|------------|
| Anterior cervical swelling | 70       | 66.03%     |
| Dyspnea                    | 24       | 22.64%     |
| Dysphagia                  | 18       | 16.98%     |
| Dysphonia                  | 8        | 7.54%      |
| Cave syndrome              | 2        | 1.88%      |
| Asymptomatic               | 10       | 9.43%      |



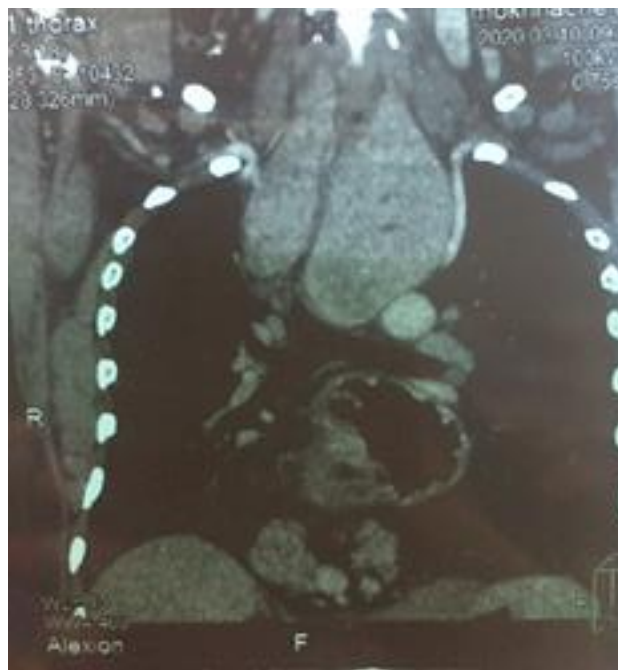
**Fig 1: Frontal clinical examination (K.Ghebouli collection)**

All our patients were admitted to the surgical department in a state of euthyroidism. The chest X-ray performed in all patients showed greater mediastinal opacity in 55 patients (51.88%), tracheal deviation in 37 patients (34.9%), and tracheal deviation and compression in 14 patients (13.2%) (Fig 2). Cervical

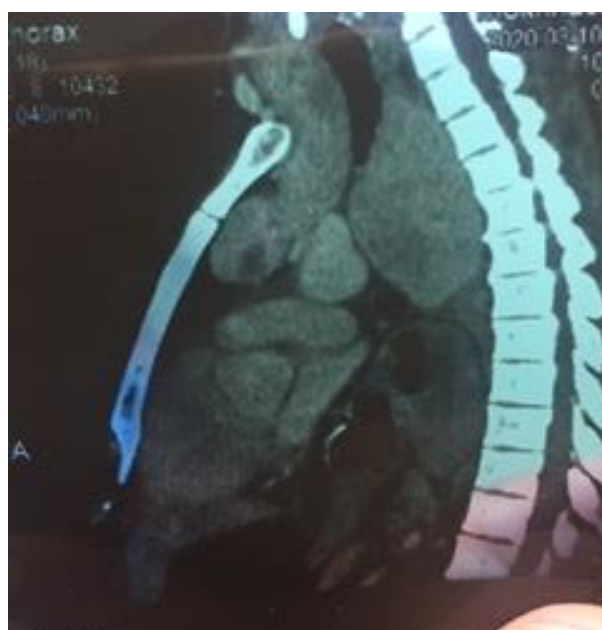
ultrasound was performed in 84 patients (79.24%), but it had only specified the plunging nature in 46 cases (43.39%). CT scan was performed in all patients; it made it possible to confirm the plunging nature of the goiter in all cases (Fig 3 & 4).



**Fig 2: Chest X-ray showed greater mediastinal opacity (K.Ghebouli collection)**



**Fig 3: CT scan showed greater Substernal Goiter associated with hiatal hernia (K. Ghebouli collection)**



**Fig 4: CT scan showed greater Substernal Goiter associated with hiatal hernia (K. Ghebouli collection)**

Our results showed that the goiter was plunging into his left lobe in 57.54%, into his right lobe in 38.67%, and bilaterally in 3.77%. Patients were classified according to the location of the mediastinal extension in relation to the trachea and the arch of the aorta (Table 2).

Subcarinal extension was constant in 35.84% of our patients and compression of nearby organs (trachea, esophagus, vessels) was observed in 39.62% of cases.

**Table 2: Relation between plunging lobe and goiter topography**

| Topography    | Plunging lobe |             |           | Total       |
|---------------|---------------|-------------|-----------|-------------|
|               | Left lobe     | Right lobe  | Bilateral |             |
| Prevascular   | 48 (45.28%)   | 22 (20.75%) | 3 (2.83%) | 73 (68.87%) |
| Retrovascular | 13 (12.26%)   | 19 (17.92%) | 1 (0.94)  | 33 (31.13%) |
| Total         | 61 (57.54%)   | 41 (38.67%) | 4 (3.77%) | 106         |

All patients in our series were operated under general anesthesia. The approach was an anterior cervicotomy in 76 cases (71.69%), a cervicotomy combined with a manubriotomy in 22 patients (20.75%), a cervicotomy combined with a total sternotomy in 6 cases (5.66%), a cervicotomy combined with anterior thoracotomy in two cases (1.88%).

Of the 33 patients with retrovascular goiter, the combined approach was practiced in 21 cases (63.63%) which correspond to 19.81% of the entire population studied.

Of the 73 patients with prevascular goiter, the combined approach was practiced in 9 cases (12.32%) which correspond to 8.49% of the entire population studied (Table 3).

**Table 3: Relation between surgical approach and goiter topography**

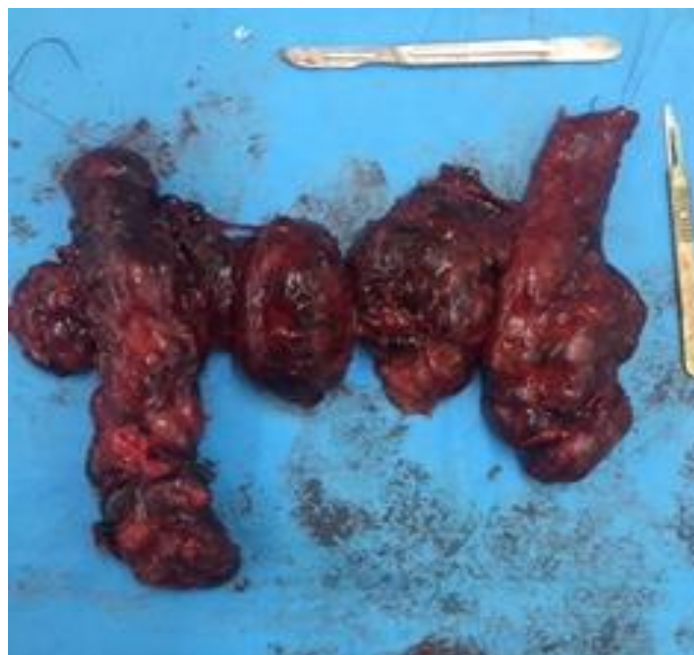
| Topography    | Surgical approach |                               |                             |                                       | Total       |
|---------------|-------------------|-------------------------------|-----------------------------|---------------------------------------|-------------|
|               | Cervicotmy        | Cervicotomy with manubriotomy | Cervicotomy with sternotomy | Cervicotomy with anterior thoracotomy |             |
| Prevascular   | 64 (60.37%)       | 6 (5.66%)                     | 1 (0.94%)                   | 2 (1.88%)                             | 73 (68.87%) |
| Retrovascular | 12 (11.32%)       | 16 (15.09%)                   | 5 (4.72%)                   | 0 (0%)                                | 33 (31.13%) |
| Total         | 76 (71.69%)       | 22 (20.75%)                   | 6 (5.66%)                   | 2 (1.88%)                             | 106         |

The surgical intervention corresponded to a total thyroidectomy in 103 cases (97.16%) and a subtotal thyroidectomy was performed in three cases.

The histological study concluded that benignity was found in 96.56% of cases, 5 cases of

papillary carcinoma, 3 cases of vesicular carcinoma and two cases of medullary carcinoma.

The average weight of the Substernal Goiters our series was 238 grams with a maximum of 836 grams. The size was between 6.2 cm and 27 cm for the largest (Fig 5).



**Fig 5: HUGH Substernal Goiter (K. Ghebouli collection)**

Two patients presented with a compressive hematoma postoperatively treated by revision surgery. A transitory hypoparathyroidism, revealed by paresthesias of the extremities, was observed in eight patients, it was suppressed by calcium supplementation. No cases of permanent hypocalcemia were observed. Four patients had presented recurrent paralysis postoperatively without prior nasofibroscope abnormalities; they had a benign histology. No tracheotomy was performed and mortality was nil.

## DISCUSSION

Substernal goiters usually occur at an advanced age 56 to 72 years [7-9]. This can be explained by the slow migration of thoracic goiters [10]. In our series it was 56.7 years.

Our study has further confirmed the clear female predominance of Substernal Goiters with 83.01%, this corresponds to the studies of (Makeieff) [11] with 80%; (Benbakh) [12] with 94%; (Mesli) [13]

with 84%; Only (Ozdemir) [14] obtains perfect equality between the two sexes.

19.81% of our patients had a family history of thyroid disease. This corresponds to the rates published in several series [6, 15, 16].

Substernal goiters are often asymptomatic, discovered by the presence of anterior cervical swelling, however the topography and the volume of the goiter lead to signs of compression.

Dyspnea comes to the fore of the clinical signs found in 22.64% of cases, the analysis of the literature has shown a rate which varies from 12% to 58% [17].

Dysphagia, mainly to solids, is most often due to compression of the esophagus. This was the telltale sign in 22% of our patients. This rate varies between 11% and 31.6% for (M. deSouza) and (B. Abboud) [18, 9]. For (Brenet) it is more important, it can go up to 43%. [15].

Nerve compression, especially common in posterior goiter, often involves the recurrent nerve and will be responsible for dysphonia observed in 7.54% of cases. Nerve compression can also involve the cervico-thoracic or cervico-brachial sympathetic but also the phrenic nerve [19].

The frequency of venous compression varies from 3 to 19% of cases [3, 20]. It almost always involves the venous trunks of the superior vena cava confluence and will be responsible for a cava syndrome, which was observed in 1.88% of cases in our series.

The incidental finding was in the order of 9.43%, generally following a x-ray requested for another reason. It corresponds to the numbers published in the literature which vary from 5 to 50% of cases depending on the series [21, 22].

CT Scan is the gold standard in goiter imaging; it was performed in all patients. It made it possible to confirm the presence of the intrathoracic extension of the goiter, to appreciate its volume, the nature of its liquid or solid contents, its position in relation to the trachea, the vessels and the esophagus, also it help us to decide on the type of approach and to predict the morbidities associated with this type of surgery.

The analysis of the results of the CT Scan showed that the dominant plunging lobe was the left lobe, found in 57.54% of the cases. (Sanders) [23] found that the left lobe was the dominant lobe [23]. (Mostafa) [24] also finds a slight predominance on the left lobe. The extension of the goiter into the anterior mediastinum is the most frequent, for (Tabchouri) it is 81.5% [25]. For the position of the goiter in relation to the vessels of the mediastinum, we found a

predominance of pre-vascular goiter representing 68.87% of substernal goiters against 31.13% of retro-vascular goiter.

The choice of surgical approaches remains a hot topic and the center of discussion for surgeons. The aim of the surgical procedure is to achieve the least invasive radical excision of the goiter possible with reduced morbidity. For this, the cervical approach is sufficient in the majority of cases [11, 26]. In our study, cervicotomy alone was performed in 71.69% of patients. Indeed, we used a combined approach in 28.31%. In the literature, the incidence of the combined approach is variable, ranging from 2% to 40%. For (Li) it is 2% [27] and for (Testini) it is 6.5% [28]. For (Pelizzo) and (Coskun), it is 8.5% and 9.5% respectively [29, 30].

For (Huin)s it is 11% [31]. However, there are more implications found by (Tabchouri), who finds 22% [25], and (Sancho) who finds an incidence of 40%. [32]; this variability could be explained by the difference in the recruitment criteria for patients with substernal represented mainly (90%) by Substernal Goiters that did not reach the carina. On the other hand, Sancho published an incidence of sternotomy of 40% for 35 patients presenting substernal goiter with extension under the carina, with a thoracotomy for one patient.

In our series, the rate of goiters reaching the arch of the aorta was 35.84%, with a combined approach in 28.31%.

(Rios *et al.*) [33] do not record any deaths, and the same is true in our series. The most common complication is compressive hematoma observed in two cases (1.88%), this complication is described in the literature as rare with a rate of 0.3 to 2% [34, 35] depending on the series.

The frequency of recurrent lesions, usually recognized only at the time of extubation, varies according to the authors from 2 to 27% [6, 36]. We recorded 4 cases (3.77%) without nasofibrosopic abnormalities.

The anatomopathological study of the surgical specimens showed the benignity of the goiter in 96.56% which seems higher compared to the figures published in the study carried out by (Sanders), who finds that the incidence of benign goiters is 79% [23].

## CONCLUSION

Substernal goiter has always been considered a challenge for surgeons, due to its particular severity, linked on the one hand to the potential for compression of noble organs, including the trachea, and on the other hand to the additional difficulties that can be

encountered during surgical management and the possibility of resorting to a combined approach.

The cervical approach is generally sufficient for the surgical management of Substernal goiters; however, the use of subtotal or total sternotomy may be necessary to extract the entire thyroid gland.

**Conflict of interest:** None declared.

## REFERENCES

- Tsilimigras, D. I., Patrini, D., Antonopoulou, A., Velissaris, D., Koletsis, E., Lawrence, D., & Panagiotopoulos, N. (2017). Retrosternal goitre: the role of the thoracic surgeon. *Journal of thoracic disease*, 9(3), 860-863. doi: 10.21037/jtd.2017.02.56.
- Ríos, A., Rodríguez, J. M., Balsalobre, M. D., Tebar, F. J., & Parrilla, P. (2010). The value of various definitions of intrathoracic goiter for predicting intra-operative and postoperative complications. *Surgery*, 147(2), 233-238. doi: 10.1016/j.surg.2009.06.018.
- Cougard, P., Matet, P., Goudet, P., Bambili, R., Viard, H., & Vaillant, G. (1992). Les goitres plongeants : 218 cas opérés. *Ann Endocrinol*, 53, 230-235.
- Merlier, M., & Eschapasse, H. (1972). Problèmes posés au chirurgien par les goitres à développement thoracique. Rapport au 73e congrès français de chirurgie 1971. In: *Actualités chirurgicales*. Paris: Masson, 138-155.
- White, M. L., Doherty, G. M., & Gauger, P. G. (2008). Evidence-based surgical management of substernal goiter. *World journal of surgery*, 32, 1285-1300.
- Terris, D. J., & Duke, W. Éd., (2016). *Thyroid and Parathyroid Diseases: Medical and Surgical Management*, 2nd edition. New York Stuttgart Dehli Rio de Janeiro: Thieme.
- Singh, B., Lucente, F. E., & Shaha, A. R. (1994). Substernal goiter: a clinical review. *American journal of otolaryngology*, 15(6), 409-416.
- Zainine, R., El Aoud, C., Bachraoui, R., Beltaief, N., Sahtout, S., & Besbes, G. (2011). The Substernal Goiter: about 43 cases. *La tunisie Medicale*, 89(11), 860-865.
- Abboud, B., Sleilaty, G., Mallak, N., Abou Zeid, H., & Tabchy, B. (2010). Morbidity and mortality of thyroidectomy for substernal goiter. *Head & Neck: Journal for the Sciences and Specialties of the Head and Neck*, 32(6), 744-749. doi: 10.1002/hed.21246.
- Raffaelli, M., De Crea, C., Ronti, S., Bellantone, R., & Lombardi, C. P. (2011). Substernal goiters: incidence, surgical approach, and complications in a tertiary care referral center. *Head & neck*, 33(10), 1420-1425.
- Makeieff, M., Marlier, F., Khudjadze, M., Garrel, R., Crampette, L., & Guerrier, B. (2000, January). Les goitres plongeants. À propos de 212 cas. In *Annales de chirurgie* (Vol. 125, No. 1, pp. 18-25). Elsevier Masson Makeieff, M., Marlier, F., Khudjadze, M., Garrel, R., Crampette, L., & Guerrier, B. (2000, January). Les goitres plongeants. À propos de 212 cas. In *Annales de chirurgie* (Vol. 125, No. 1, pp. 18-25). Elsevier Masson.
- Benbakh, M., Abou-Elfadl, M., Rouadi, S., Abada, R. L., Roubal, M., & Mahtar, M. (2016). Goitres plongeants: Expérience du service à propos de 50 cas. *Annales françaises d'Oto-rhino-laryngologie et de Pathologie Cervico-faciale*, 133(1), 17-20.
- Mesli, N., Regagba, D., Tidjane, A., Bouallou, F., & Abi-Ayad, C. (1954). Le goitre plongeant à Tlemcen dans l'ouest algérien: aspect clinique et thérapeutique de 1996-2014 Service de Chirurgie Générale A, CHU Tlemcen, Algérie, 2Service de Chirurgie Hépatobiliaire et Greffe du Foie, EHU-1er Novembre, Oran, Algérie.
- Ozdemir, A., Hasbahceci, M., Hamaloglu, E., & Ozenc, A. (2000). Surgical treatment of substernal goiter. *International surgery*, 85(3), 194-197.
- Brenet, E., Dubernard, X., Mérol, J. C., Louges, M. A., Labrousse, M., & Makeieff, M. (2017). Assessment and management of cervico-mediastinal goiter. *European annals of otorhinolaryngology, head and neck diseases*, 134(6), 409-413. doi: 10.1016/j.anorl.2017.06.001.
- Ff, R., Ib, H., Rg, E., Js, I., Myhill, J., & Th, O. (1962). The investigation and management of intrathoracic goiter. *Surgery, Gynecology & Obstetrics*, 115, 222-229.
- Chen, A. Y., Bernet, V. J., Carty, S. E., Davies, T. F., Ganly, I., Inabnet III, W. B., & Shaha, A. R. (2014). American Thyroid Association statement on optimal surgical management of goiter. *Thyroid*, 24(2), 181-189.
- DeSouza, F. M., & Smith, P. E. (1983). Retrosternal goiter. *The Journal of otolaryngology*, 12(6), 393-396.
- Lahlaidi, A. (1986). Système nerveux, tête, cou et organe des sens. *Anatomie topographique*, 4, 192-197.
- Kraimps, J. L., Gineste, D., Gauthier, J. B., & Benand, P. (1990). Goiter plongeant: 100 cas. *Lyon Chir*, 86, 455-457.
- Chauhan, A., & Serpell, J. W. (2006). Thyroidectomy is safe and effective for retrosternal goitre. *ANZ journal of surgery*, 76(4), 238-242. doi: 10.1111/j.1445-2197.2006.03699.x.
- Wax, M. K., & Briant, T. D. (1992). Management of substernal goitre. *The Journal of Otolaryngology*, 21(3), 165-170.
- Sanders, L. E., Rossi, R. L., Shahian, D. M., & Williamson, W. A. (1992). Mediastinal goiters: the need for an aggressive approach. *Archives of Surgery*, 127(5), 609-613. doi: 10.1001/archsurg.1992.01420050137018.
- Sakkary, M. A., Abdelrahman, A. M., Mostafa, A. M., Abbas, A. A., & Zedan, M. H. (2012). Retrosternal goiter: the need for thoracic approach based on CT findings: surgeon's view. *Journal of the Egyptian National Cancer Institute*, 24(2), 85-90. doi: 10.1016/j.jnci.2012.04.002.
- Tabchouri, N., Anil, Z., Marques, F., Michot, N., Dumont, P., Arnault, V., & De Calan, L. (2018). Morbidité de la thyroïdectomie totale pour goitre plongeant: série de 70 patients. *Journal de*

- chirurgie Viscérale*, 155(1), 10-15. doi: 10.1016/j.jchirv.2017.01.008.
26. Tajdine, M. T., Lamrani, M., Serhane, K., Achour, A., Benariba, F., & Daali, M. (2005). Les goitres multihétéronodulaires plongeants: à propos de 100 cas marocains. *Cahiers d'études et de recherches francophones/Santé*, 15(4), 247-252.
  27. Li, W., Li, H., Zhang, S., Tao, Y., Wang, X., & Cheng, J. (2020). To explore the risk factors and preventive measures affecting the treatment of retrosternal goiter: An observational study. *Medicine*, 99(44). doi: 10.1097/MD.00000000000023003.
  28. Testini, M., Gurrado, A., Avenia, N., Bellantone, R., Biondi, A., Brazzarola, P., ... & Basile, F. (2011). Does mediastinal extension of the goiter increase morbidity of total thyroidectomy? A multicenter study of 19,662 patients. *Annals of surgical oncology*, 18, 2251-2259. doi: 10.1245/s10434-011-1596-4.
  29. Pelizzo, M. R. (2015). Difficult thyroidectomies. *Il Giornale di chirurgia*, 36(2), 49-56. Consulté le: 18 juillet 2021. [En ligne]. Disponible sur: <https://www.ncbi.nlm.nih.gov/pmc/articles/PMC4469207/>
  30. Coskun, A., Yildirim, M., & Erkan, N. (2014). Substernal goiter: when is a sternotomy required?. *International surgery*, 99(4), 419-425. doi: 10.9738/INTSURG-D-14-00041.1.
  31. Huins, C. T., Georgalas, C., Mehrzad, H., & Tolley, N. S. (2008). A new classification system for retrosternal goitre based on a systematic review of its complications and management. *International journal of surgery*, 6(1), 71-76. doi: 10.1016/j.ijsu.2007.02.003.
  32. Sancho, J. J., Kraimps, J. L., Sanchez-Blanco, J. M., Larrad, A., Rodríguez, J. M., Gil, P., ... & Sitges-Serra, A. (2006). Increased mortality and morbidity associated with thyroidectomy for intrathoracic goiters reaching the carina tracheae. *Archives of surgery*, 141(1), 82-85. doi: 10.1001/archsurg.141.1.82.
  33. Ríos, A., Rodríguez, J. M., Galindo, P. J., Torres, J., Canteras, M., Balsalobre, M. D., & Parrilla, P. (2008). Results of surgical treatment in multinodular goiter with an intrathoracic component. *Surgery today*, 38, 487-494.
  34. Zambudio, A. R., Rodríguez, J., Riquelme, J., Soria, T., Canteras, M., & Parrilla, P. (2004). Prospective study of postoperative complications after total thyroidectomy for multinodular goiters by surgeons with experience in endocrine surgery. *Annals of surgery*, 240(1), 18-25. doi: 10.1097/01.sla.0000129357.58265.3c.
  35. Reeve, T., & Thompson, N. W. (2000). Complications of thyroid surgery: how to avoid them, how to manage them, and observations on their possible effect on the whole patient. *World journal of surgery*, 24, 971-975. doi: 10.1007/s002680010160.
  36. Testini, M., Gurrado, A., Bellantone, R., Brazzarola, P., Cortese, R., De Toma, G., ... & Rosato, L. (2014). Paralysie récurrentielle et goitre sous-sternal: une étude multicentrique italienne. *Journal de Chirurgie Viscérale*, 151(3), 187-193. doi: 10.1016/j.jchirv.2014.03.009.