

## Case Report

# Symptomatic Diffuse Adenomyomatosis of the Gallbladder—Report of a Rare Case

Tiwari P<sup>1</sup>. M.S, Tiwari M<sup>2</sup>. M.D.

<sup>1</sup>Tiwari P, M.S. Assistant Professor in General Surgery, Medical Campus SGT Medical College, Budhera, Gurgaon, India

<sup>2</sup>Tiwari M, M.D. Assistant Professor in Anaesthesiology, Medical Campus SGT Medical College, Budhera, Gurgaon, India

### \*Corresponding author

Dr. Pawan Tiwari

Email: [tiwaripawan58@gmail.com](mailto:tiwaripawan58@gmail.com)

**Abstract:** Adenomyomatosis of the gallbladder is a benign and degenerative condition of the gallbladder, characterized by proliferation of the mucosa of the gallbladder wall, forming invaginations and diverticula, penetrating a thickened muscular layer: the so-called Rokitansky-Aschoff sinuses (RAS). Most of the patients with adenomyomatosis remain asymptomatic. Hence adenomyomatosis is usually an incidental finding, either on ultrasonography performed for the detection of stones or by histologic examination of surgical gallbladder specimens. We report a case of symptomatic diffuse adenomyomatosis of the gallbladder. Clinical findings, etiology, diagnosis and therapy are discussed.

**Keywords:** Adenomyomatosis of gallbladder; symptoms; treatment.

## INTRODUCTION

Adenomyomatosis of the gallbladder is a degenerative condition of the gallbladder characterized by the proliferation of the mucosa of the gallbladder wall, which forms invaginations and diverticula penetrating a thickened muscular layer: the so-called Rokitansky-Aschoff sinuses (RAS). Adenomyomatosis is usually an incidental finding at the histologic examination of gallbladders removed for chronic cholecystitis or at ultrasonography performed for the detection of stones. Only occasionally will adenomyomatosis be diagnosed in an acalculous gallbladder by the visualisation of Rokitansky-Aschoff sinuses on ultrasonography, CT scan or MRI. Most of the patients with adenomyomatosis of the gallbladder remain asymptomatic. However, right upper quadrant pain can occur, which is indistinguishable from the pain generated by cholelithiasis. Treatment of symptomatic adenomyomatosis consists of cholecystectomy by laparoscopic approach whenever possible.

## CASE REPORT

A 56-year-old man was referred to the Department of Surgery with recurrent right upper quadrant pain. The pain was described as colicky and occurred especially after fatty meals. The patient had experienced this pain for three years. In the course of the last three months, the attacks had become more frequent (up to once or twice a week), intense and distressing. The history of the patient was negative except for a road side accident sustained in 1989 which caused Blunt injury abdomen and fracture ribs on right side from which he completely recovered. At physical examination we found tenderness of the right upper quadrant and epigastric region. All laboratory data,

including liver and pancreatic enzymes were within normal limits. USG showed chronic cholecystitis with diffuse wall thickening upto 6mm with multiple calculi (Fig. 1). CT scan could not be done due to financial constrains. Laparoscopic cholecystectomy was performed. Macroscopic examination of the specimen showed a gallbladder of 7cmX4cm, with a diffusely thickened a wall, with trabeculation and saccule formation, with multiple stones (Fig. 2). Histologic examination showed a hyperplastic mucosa with focal erosions and a thickened musculosa. Rokitansky-aschoff sinuses (RAS) or out pouchings of the mucosa into and through the musculosa were noted. Minor inflammatory changes were seen around inspissated bile in the diverticula. The surrounding fat tissue was almost completely substituted by a reparative fibrosis. The RAS, minor inflammatory and fibrotic changes were found spread diffusely all over the gallbladder wall and were typical of the histologic appearance of the generalized type of adenomyomatosis of the gallbladder. The patient remained symptom-free after laparoscopic cholecystectomy.

## DISCUSSION

Adenomyomatosis of the gallbladder is generally accepted to be a benign, proliferative and degenerative condition of the gallbladder. The term adenomyomatosis was introduced by Jutras *et al* [1,2,3] in 1960 as part of the hyperplastic cholecystoses. Hyperplastic implies the proliferation of normal tissue elements, while cholecystoses indicates a pathological process distinct from inflammatory disease. In adenomyomatosis, there is hyperplasia and hypertrophy of the tissues which constitute the gallbladder wall, characterized by proliferation of the mucosa and

thickening of the muscle wall. The resulting epithelial proliferation forms invaginations and diverticula which penetrate the muscular layer; the so called Rokitansky-Aschoff sinuses (RAS) [4].

The incidence of adenomyomatosis varies between 0.6 and 33.3% of all gallbladder diseases, depending on whether figures are derived from radiological or surgical specimens [5].

According to a morphological classification, adenomyomatosis is divided into three types: generalized, segmental and localized, depending on the extent and the site of involvement. In generalized or diffuse adenomyomatosis there is diffuse thickening and irregularity of the mucosal surface and the muscle coat, accompanied by intramural diverticula, which results in the appearance of gland-like or cyst-like structures in the gallbladder wall. This histologic appearance prompted the terms cholecystitis glandularis proliferans or cystic cholecystitis. In the segmental or annular form of adenomyomatosis, a focal circumferential stricture divides the gallbladder lumen into separate interconnected compartments (compartmentalization). In the focal type of adenomyomatosis, the lesion is confined to the fundus and usually presents as a nodule, bulging into the lumen. Histologically, focal hyperplasia of tissues in the wall and mucosal herniations are seen [4]. The incidence of the different types of adenomyomatosis varies depending on the series of patients described by the authors. In the series of Colquhoun *et al* [6]. And Ootani *et al*[7]. The segmental and fundal types form the largest groups (each  $\pm$  40%) while in the series of Christensen and Ishak [8] the generalized type of adenomyomatosis dominates.

In the present case, the histologic findings correlate with a diffuse form of adenomyomatosis, characterized by generalized hyperplasia of the mucosa and the muscular layers of the gallbladder wall, and the formation of intramural diverticula, crypts or sinus tracts (Rokitansky-Aschoff sinuses). At macroscopic examination, a gallbladder with a diffusely thickened wall was found. Microscopically, the lesions were not limited to the fundus or to any other segment of the gallbladder but RAS were found diffusely spread all over the gallbladder wall.

Adenomyomatosis of the gallbladder is accepted to be a degenerative disease. Only one case of childhood adenomyomatosis of the gallbladder is reported in the literature [9]. Other reports show series of adenomyomatosis occurring in patients of middle age and with an incidence increasing with age, which infirms the theory of a congenital lesion [4]. Little is known about the etiology of adenomyomatosis of the gallbladder. According to the recent literature, the possible causes of the disease remain hypothetical.

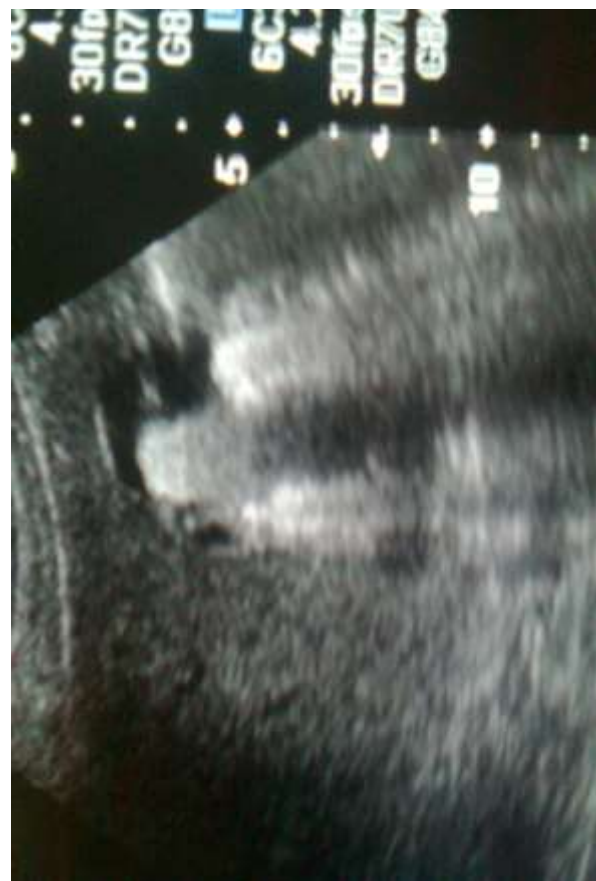

Fig. 1 showing thick walled gall bladder with multiple calculi.

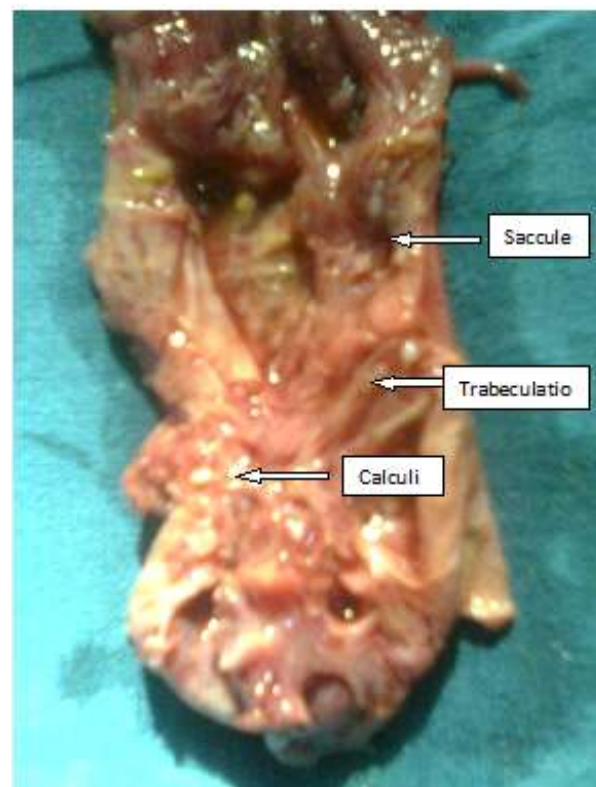


Fig. 2 Operated specimen of gall bladder with trabeculation, sacculation and multiple calculi.

These hypotheses can be classified into two groups. For a first group of authors, the pathogenetic mechanism is possibly related to increased intraluminal pressure. High gallbladder pressure is not caused by a mechanical obstruction but is the result of abnormal muscle contraction due to neurogenic dysfunction as seen in diverticular disease of the colon. The thickened muscular wall, as seen in adenomyomatosis, is compatible with a contracture of the muscular layer upon which the redundant intraluminal mucosa bunches up into folds and even penetrates the muscle by forming diverticula [4,5,9]. For a second group of authors [10], the etiology of adenomyomatosis is related to an anomalous pancreaticobiliary ductal union. In this condition, the common bile channel is abnormally long and the junction between the common bile duct and the pancreatic duct is located outside the duodenal wall. As a result of this anomalous junction, there is regurgitation of pancreatic juice into the gallbladder. The mechanism that causes adenomyomatosis in this situation would be elevation of the intragallbladder pressure or chronic stimulation of the gallbladder mucosa by regurgitated pancreatic juice. Although many patients with adenomyomatosis present with gallstones, there is no clear relationship between these two entities. Some authors like Yang *et al* [5]. and Cetta *et al* [11]. suggest a possible etiologic relationship between adenomyomatosis and the formation of gallstones while others like Berk *et al*[4]. do not believe there is a pathophysiological relationship between the two entities.

The clinical implications of adenomyomatosis are controversial. On the one hand, many patients remain asymptomatic and adenomyomatosis is an incidental finding on ultrasonography or histologic examination. It is impossible to determine the exact extent of this asymptomatic group of patients because a lot of them remain undetected. On the other hand, the pain described by patients with symptomatic adenomyomatosis has a colicky nature and cannot be distinguished from the pain caused by calculi. About 70% of the symptomatic patients present with gallstones (Jutras, 78% [1], Meguid, 72% [12], Kasahara, 67% [13]. Hence, in symptomatic patients who also have gallstones, it is impossible to say if the symptoms are due to the stones or to the adenomyomatosis [4,5,9]. In the residual 30% of patients with symptomatic but acalculous adenomyomatosis, the main symptoms are vague indigestion, discomfort and abdominal pain, all symptoms that are the same as those characteristic of calculous cholecystitis [12,13,14]. In acalculous adenomyomatosis, there is often a remarkable chronicity of symptoms.

In general, all laboratory findings of patients with adenomyomatosis are within normal limits. The typical radiological appearance of adenomyomatosis is very helpful in obtaining a correct diagnosis. On oral

cholangiography (OCG), the filling of intramural diverticula with contrast material can easily be seen. The diverticula are demonstrated as small contrast collections parallel with the lumen of the gallbladder. A fatty meal often highlights the findings. At the present time however, most centers have abandoned Ocg in favour of ultrasonography [16,17]. In our case, no OCG was performed. In general, ultrasonography is becoming the method of choice in evaluating the patient with suspected calculous gallbladder disease [16] and for the screening and follow-up of polypoid lesions [17]. Concerning adenomyomatosis, a good correlation between sonographic and pathologic findings is described by several authors [18,19] ; moreover, others claim that more cases of adenomyomatosis are detected through sonographic examinations than through oral cholangiography [20, 21]. The ultrasonic diagnostic criteria for gallbladder adenomyomatosis include diffuse or segmental thickening of the gallbladder wall and the appearance of anechoic intramural diverticula. If the diverticula are too small to be visualized, the ultrasonic findings may be limited to nonspecific gallbladder wall thickening which may be confused with chronic cholecystitis or gallbladder carcinoma [18]. Because the symptom complex suggested a calculous gallbladder disease and because of the non-invasive character of this examination, ultrasonography was the investigation of choice in starting the evaluation of our patient.

Methods for diagnosing adenomyomatosis of the gallbladder are CT-scan and MRI. The CT-appearances of adenomyomatosis are similar to the sonographic findings: thickening of the gallbladder wall and the appearance of intramural diverticula in the diseased segment. Dis-advantages of CT-scan are the need for a contrast medium and the fact that there must be connections between the diverticular lesions and the gallbladder cavity [18]. In MRI on the other hand, fluid in the gallbladder and bile ducts can be visualized without contrast. RAS appear on MRI as high intensity spots in the gallbladder wall and need not be connected to the gallbladder cavity to be detected. Several studies show the importance of MRI in the detection of RAS, while MRI failed to clearly visualize the cystic duct and the gallbladder wall because of the short T2-values. A disadvantage still related to MRI is the motion related artefacts, which may prevent clear depiction of small sinuses and mild wall thickening. Solutions to this problem are the use of breath-hold images or simple shot fast spin echo sequences [9,18]. Although CT-scan and MRI-findings of adenomyomatosis are well correlated with the known histologic changes, they cannot exclude coexisting carcinoma. Although adenomyomatosis of the gallbladder was initially described as a non-inflammatory and exclusively benign lesion, it is noteworthy that in the recent literature its possible premalignant character is being investigated. Several cases of gallbladder carcinoma arising in adenomyomatosis were described by Aldridge

et al [22]. Ootani et al [7] emphasize the possible relationship between the segmental type of adenomyomatosis and the prevalence of gallbladder carcinoma in a series of 188 patients with segmental adenomyomatosis. Two other studies by Tokiwa et al [23] and Chang et al [24]. describe an etiological relationship between anomalous pancreaticobiliary ductal union (APBDU) and the appearance of gallbladder carcinoma on one hand and the causal relationship of APBDU and adenomyomatosis on the other. Both groups of investigators suggest a possible relationship between adenomyomatosis and gallbladder carcinoma, but this hypothesis has not yet been proved [23, 24]. Concerning the management of adenomyomatosis, there is consensus in the recent literature. All patients presenting with symptomatic adenomyomatosis or with gallbladder lesions suggestive of adenomyomatosis but indistinguishable from premalignant or malignant lesions, are considered as an indication for cholecystectomy. In the last 10 years, most of the cholecystectomies were performed laparoscopically and nearly all of the patients operated upon for symptomatic adenomyomatosis improved after the operation [9]. Our patient, who presented with a symptom complex similar to that of calculous cholecystitis, was immediately relieved after cholecystectomy, which could be performed laparoscopically.

## CONCLUSION

Adenomyomatosis of the gallbladder is a benign and degenerative condition of the gallbladder, which is incidentally found by cholecystography, ultrasonography, CT scan or MRI. Only in a few cases does adenomyomatosis give rise to a symptom complex similar to that of chronic cholecystitis. Most often, adenomyomatosis is discovered at microscopic examination of excised gallbladder specimens for cholelithiasis. Therapy consists of cholecystectomy, by laparoscopic approach whenever possible.

## Acknowledgements

We are indebted to Dr. T.D. Dogra Vice chancellor, SGT University, Gurgaon, Dr. K.Kohli Director Principal, SGT Medical College, Gurgaon for allowing us to report this study and for being a source of inspiration in our academic pursuits.

## REFERENCES

1. Jutras JA, Longtin JM, Levesqu EHP; Hyperplastic cholecystoses. Hickey lecture. *AJR* 1960; 83: 795-827.
2. Jutras JA, Levesque HP; Adenomyoma and adenomyomatosis of the gallbladder; radiologic and pathologic correlations. *Rad Clin N Amer*, 1966; 4: 483-500.
3. Jutras M; The cholesteroses (adenomyomatosis, cholesterolosis and neuromatosis). In: Bockus HL. (ed.).

*Gastroenterology*. 3<sup>rd</sup> ed. Vol III. Philadelphia: WB Saunders, 1976; 816-827.

4. Berk RN, Van Der Vegt JH, Lichtenstein JE; The hyperplastic cholecystoses: cholesterolosis and adenomyomatosis. *Radiology*, 1983; 146: 593-601.
5. Yang WG, Wang SS, Weng YJ. et al.; Adenomyomatosis of the gallbladder. *Chung Hua I Hsueh Tsa Chih (Taipei)*, 1996; 58: 12-17.
6. Colquhoun J; Adenomyomatosis of the gallbladder (intramural diverticulosis). *Br J Radiol*, 1961; 34: 101-112.
7. Ootani T, Shirai Y, Tsukada K, Muto T; Relationship between gallbladder carcinoma and the segmental type of adenomyomatosis of the gallbladder. *Cancer*, 1992; 69: 2647-52.
8. Christensen AH, Ishak KG; Benign tumors of the gallbladder. Report of 180 cases. *Arch Pathol*, 1970; 90: 423-432.
9. Alberti D, Callea F, Camoni G, Falchetti D, Rigamonti W, Caccia G; Adenomyomatosis of the gallbladder in childhood. *J Pediatr Surg*, 1998; 33: 1411-12.
10. Kainuma O, Asano T, Nakagohri T et al.; A case of gallbladder adenomyomatosis with pancreaticobiliary maljunction and an anomaly of the cystic duct joining the common channel. *Am J Gastroenterol*, 1998; 93: 1156- 58.
11. Cetta F, Lombardo F, Malet PF; Black pigment gallstones with cholesterol gallstones in the same gallbladder. 13 cases in a surgical series of 1226 patients with gallbladder stones. *Dig Dis Sci*, 1995; 40 (3): 534-38.
12. Meguid MM, Aun F, Bradford ML; Adenomyomatosis of the gallbladder. *Am J Surg*, 1984; 147 (2): 260-62.
13. Kasahara Y, Sonobe N, Tomiyoshi H. et al; Adenomyomatosis of the gallbladder: a clinical survey of 30 surgically treated patients. *Nippon Geka Hokan*, 1992; 61 (2): 190-98.
14. Halpert RD, Bedi DG, Tirman PJ, Gore DC; Segmental adenomyomatosis of the gallbladder. A radiologic, sonographic and pathologic correlation. *Am Surg*, 1989; 55 (9): 570-72.
15. Ram MD, Midha D; Adenomyomatosis of the gallbladder. *Surgery*, 1975; 78 (2): 224-29.
16. Cooperberg PL, Burhenne HL; Real-time ultrasonography. Diagnostic technique of choice in calculous gallbladder disease. *N Engl J Med*, 1980; 302 (23): 1277-79.
17. Sugiyama M, Atomi Y, Yamato T; Endoscopic ultrasonography for differential diagnosis of polypoid gallbladder lesions: analysis in surgical and follow-up series. *Gut*, 2000; 46: 250-54.
18. Hwang JI, Chou YH, Tsay SH. et al; Radiologic and pathologic correlation of

- adenomyomatosis of the gallbladder. *Abdom Imaging*, 1998; 23: 73-77.
19. Raghavendra BN, Subramanyam BR, Balthazar EJ, Horii SC, Megibow AJ, Hilton S; Sonography of adenomyomatosis of the gallbladder: radiologic-pathologic correlation. *Radiology*, 1983; 146 (3) 747- 52.
  20. Kim MJ, Oh YT, Park YN, Chung JB, Kim DJ, Chung JJ, Mitchell DG; Gallbladder adenomyomatosis : findings on MRI. *Abdom Imaging*, 1999; 24 (4): 410-13.
  21. Fowler RC, Reid WA; Ultrasound diagnosis of adenomyomatosis of the gallbladder: ultrasonic and pathological correlation. *Clin Radiol*, 1988; 39 (4): 402-6.
  22. Aldridge MC, Gruffaz F, Castaign D, Bismuth H; Adenomyomatosis of the gallbladder. A premalignant lesion? *Surgery*, 1991; 109: 107-10.
  23. Tokiwa K, Iwai N; Early mucosal changes of the gallbladder in patients with an anomalous arrangement of the pancreaticobiliary duct. *Gastroenterology*, 1996; 110: 1614-18.
  24. Chang LY, Wang HP, Wu MS. et al; Anomalous pancreaticobiliary ductal union – an etiologic association of gallbladder cancer and adenomyomatosis. *Hepatogastroenterology*, 1998; 45: 2016-19.