

## Case Report

# Chronic Isolated Sphenoid Sinusitis in a 12-Year-Old Child with Isolated Oculomotor Nerve Palsy: A Rare Case

Chowdareddy N<sup>1\*</sup>, Dayanandakumar R<sup>2</sup><sup>1</sup>Assistant Professor, Department of Pediatrics, MVJ Medical College, Bangalore, India<sup>2</sup>Associate Professor, Department of Radiodiagnosis, MVJ Medical College, Bangalore, India

### \*Corresponding author

Dr. Chowdareddy N

Email: [ncreddypeds@gmail.com](mailto:ncreddypeds@gmail.com)

**Abstract:** Isolated, sphenoid sinusitis is unusual, especially in children. Its incidence is about 2.7% of all sinus infections. It is frequently misdiagnosed because of its atypical presentation and it can cause serious complications because of the sphenoid sinus anatomical relations with many intracranial structures. One of the intracranial structures located closely to sphenoid sinus is oculomotor nerve. As the name suggests, the oculomotor nerve supplies the majority of the muscles controlling eye movements. Thus, damage to this nerve will result in the oculomotor palsy. There are many etiologies for oculomotor palsy one of the rare cause is sphenoid sinusitis. The manifestations depend on the affected area of 3rd nerve track. We are reporting a rare case of isolated oculomotor nerve palsy due to sphenoid sinusitis.

**Keywords:** Oculomotor nerve palsy, Eye movements, Sphenoid sinusitis

## INTRODUCTION

The sphenoid sinus is often referred to as the "neglected" sinus [1]. Infection usually occurs in conjunction with infection of the other paranasal sinuses. Isolated acute sphenoiditis is rare [1-3] and it is reported almost uniquely in older children [4]. It merits particular concern, due to potentially serious and even fatal complications [5-8]. It is frequently misdiagnosed because of its atypical presentation.

Furthermore, the clinical presentation of third nerve dysfunction is remarkably varied—the nerve supplies seven different muscles, and almost any combination of these can be affected to varying degrees. We report a case of a previously healthy 12-year-old boy, presenting with head ache and difficulty to open right eye.

## CASE REPORT

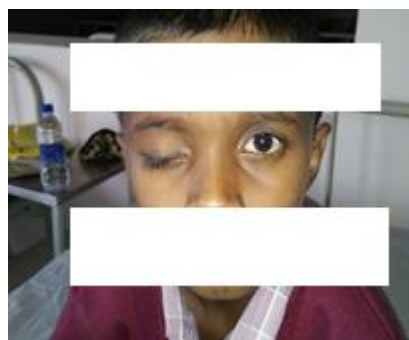A 12-year-old boy, presented to hospital with head ache and inability to open right eye since 4 days. He had no fever and no signs of infection, nor any history of trauma. His parents declared that he could not reach any medication at home nor had they witnessed any obvious convulsions. His personal and family medical history was insignificant. He was fully immunized.

General physical examination was normal. Neurological examination revealed right isolated right sided oculomotor nerve palsy. Complete blood count and biochemistry tests were normal, except for

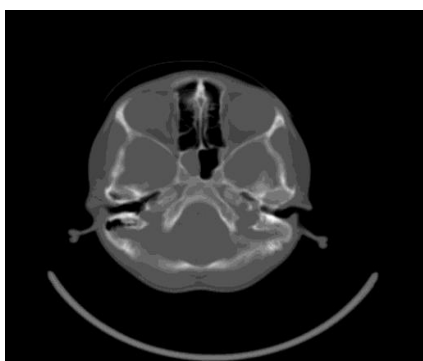lymphocytosis and thrombocytosis. CT and MRI of the head revealed right sphenoid sinus opacity, with the rest of the sinuses and brain normal. The patient commenced treatment with i.v. ceftriaxone plus metronidazole. He was treated with intravenous antibiotics for 10 days, after which he was switched to oral cefuroxime axetil for 10 days. His final outcome was excellent.

**Table 1: Showing motor Functions of oculomotor cranial nerve**

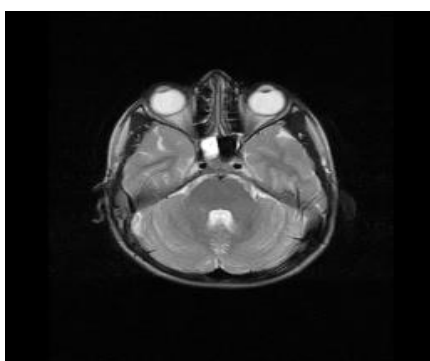
	Right eye	Left eye
Levator palpebrae superioris muscle action	Absent	Intact
Squint	Outward and downward	Absent
Pupil size	4mm	3mm
Light reflex	Present	Present



**Fig. 1: Patient showing right sided ptosis**



**Fig. 3: CT scan showing: Right isolated sphenoid sinus opacification**



**Fig. 4: MRI of the head revealed right sphenoid sinus opacity**

#### DISCUSSION

Sphenoid sinusitis is an uncommon entity in children. Van Alyea had described the sphenoid sinus as the most neglected sinus [9]. It affects children in pre-adolescent and adolescent age, clinically apparent between the age of 5 and 15 years [10]. The low incidence of isolated sphenoiditis is due to its deep position away from the current of nasal secretions, irritants and pathogens [11]. The low rate of sphenoiditis can also be explained by the low secretion rate of its lining mucosa and therefore decreased drainage problems as compared to other paranasal sinuses [12].

The clinical presentation of isolated sphenoiditis is usually vague and nonspecific that makes delay in diagnosis [13]. Other symptoms include blindness, ophthalmoplegia, cavernous sinus thrombosis, meningitis, cerebral infarction and cranial nerves palsy [14]. Uncomplicated acute sphenoiditis can be treated with 3-4 weeks of antibiotics directed against the most common pathogens [4].

#### CONCLUSION

Chronic isolated sphenoid sinusitis in children is a rare but serious condition. Its unspecific presentation may delay the diagnosis and can lead to devastating complications. It may involve several intracranial structures, with potentially severe or even fatal complications. Prompt diagnosis and antibiotic therapy is essential to minimize mortality and morbidity. CT

scan of the head is the examination of choice and MRI may be considered, if necessary. Uncomplicated cases can resolve with optimal antibiotic therapy.

#### REFERENCES

1. Ng YT, Butler IJ; Sphenoid sinusitis masquerading as migraine headaches in children. *J Child Neurol.*, 2001;16(12): 882-884.
2. Uren BA, Berkowitz RG; Isolated inflammatory sphenoid sinus disease in children. *Ann Otol Rhinol Laryngol.*, 2003; 112(4): 370-372.
3. Tan HHK, Ong YK; Acute isolated sphenoid sinusitis. *Ann Acad Med Singap.*, 2004; 33(5): 656-659.
4. Haimi-Cohen Y, Amir J, Zeharia A, Danziger Y, Ziv N, Mimouni M; Isolated sphenoid sinusitis in children. *Eur J Pediatr.*, 1999; 158(4): 298-301.
5. Rimal D, Hashmi SM, Prinsley PR; An unusual presentation of sphenoid sinusitis with septicaemia in a healthy young adult. *Emerg Med J.*, 2006; 23(6): e36.
6. Saitoh A, Beall B, Nizet V; Fulminant bacterial meningitis complicating sphenoid sinusitis. *Pediatr Emerg Care*, 2003; 19(6): 415-417.
7. Radulescu L, Poiata I, Curca IA, Martu D; Thrombophlebitis of left cavernous sinus secondary to acute right sphenoid sinusitis. *Rev Med Chir Soc Med Nat Iasi.*, 2005; 109(3): 573-576.
8. Deans JA, Welch AR; Acute isolated sphenoid sinusitis: a disease with complications. *J Laryngol Otol.*, 1991;105(12):1072-1074.
9. Van Alyea OE; Sphenoid sinus: anatomic study, with consideration of the clinical significance of the structural characteristics of the sphenoid sinus. *Arch Otolaryngol.*, 1941; 34(2): 225-253.
10. Wolf G, Anderhuber W, Kuhn F; Development of the paranasal sinuses in children: implication for paranasal sinus surgery. *Ann Otol Rhinol Laryngol.*, 1993; 102(9): 705-711.
11. Lew D, Southwick FS, Montgomery WW, Weber AL, Baker AS; Sphenoid sinusitis: a review of 30 cases. *N Engl J Med.*, 1983; 309(19): 1149-1154.
12. Tan HK, Ong YK; Acute isolated sphenoid sinusitis. *Ann Acad Med.*, 2004; 33(5): 656-659.
13. Lahat E, Danieli J, Cohen H, Paret G, Barzilai A; Acute isolated sphenoid sinusitis in children. *Pediatr Infect Dis.*, 1997; 16(12): 1180-1183.
14. Marseglia GL, Pagella F, Licari A, Scaramuzza C, Marseglia A, Leone M *et al.*; Acute isolated sphenoid sinusitis in children, *Int J Pediatr Otorhinolaryngol.*, 2006; 70(12): 2027-2031.