

## **Case Report**

# **Chondroblastoma-Like Extraskelatal Chondroma of the Hand: A Rare Case Report**

**Navya BN<sup>1\*</sup>, Ranganath N<sup>2</sup>, Karumbaiah P<sup>3</sup>, Kariappa TM<sup>4</sup>**

<sup>1</sup>Assistant Professor, Department of Pathology, KVG Medical College and Hospital, Kurunjibag, Sullia-574327, India

<sup>2</sup>Assistant Professor, Department of Orthopaedics, KVG Medical College and Hospital, Kurunjibag, Sullia-574327, India

<sup>3</sup>Associate Prof, Department of Pathology, KVG Medical College and Hospital, Kurunjibag, Sullia-574327, India

<sup>4</sup>Professor & HOD, Department of Pathology, KVG Medical College and Hospital, Kurunjibag, Sullia-574327, India

### **\*Corresponding author**

Dr. Navya BN

**Email:** [navyabn@rediffmail.com](mailto:navyabn@rediffmail.com)

---

**Abstract:** Extraskelatal chondroma (ESC) is a rare benign cartilaginous tumor that occurs predominantly in soft tissues near small joints of hand and feet. The importance of this lesion is that it must be distinguished from more aggressive soft tissue chondrosarcoma so as to spare the patient from unnecessary radical therapy. Here, we present a case of ESC of hand in a 32 yr old female with a variable histological appearance exhibiting chondroblastoma- like areas leading to a mistaken diagnosis of Extraskelatal myxoid chondrosarcomas (ESMCS). Hence, the case had to be carefully evaluated to exclude ESMCS and to make the diagnosis of ESC. The treatment was limited to simple excision of the tumor and extensive surgery and radiotherapy was avoided.

**Keywords:** Extraskelatal chondroma, chondroblastoma- like areas, Extraskelatal myxoid chondrosarcomas.

---

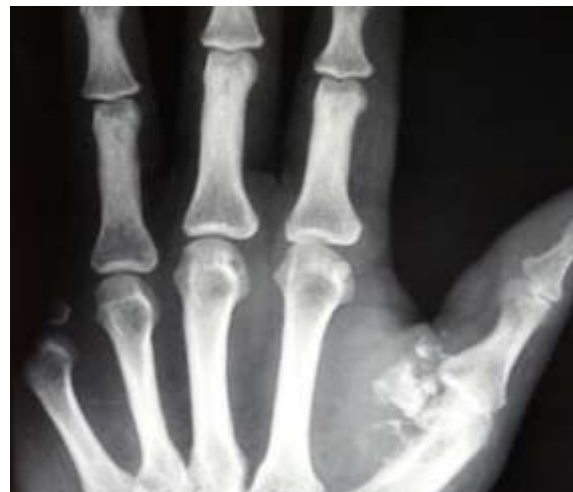## **INTRODUCTION**

Extraskelatal chondroma (ESC ) also called as chondroma of soft parts is a relatively rare, benign, slow-growing soft tissue tumor composed mainly of hyaline cartilage with no connection to bone or periosteum. The most frequent sites of involvement for an ESC are hands and feet. Less commonly, it is found in the oral cavity, pharynx, trunk, and knee [1, 3]. It usually arises as slow growing, painless mass in adults with age range of 30-60 years [3].

## **CASE REPORT**

A 32 year old female patient presented with history of painless swelling on the left palm since 1 year. Physical examination revealed irregular firm mass on the volar aspect of the left thumb measuring 3x2 cm extending from base of the thumb to thenar crease. Movements of left thumb at MCP joint were restricted. X-ray of the hand showed a dense soft tissue mass with calcification (Fig. 1). There was no periosteal reaction nor any erosion of the cortical bone. Marginal excision of the tumor was done under regional anaesthesia and was sent for histopathological examination.

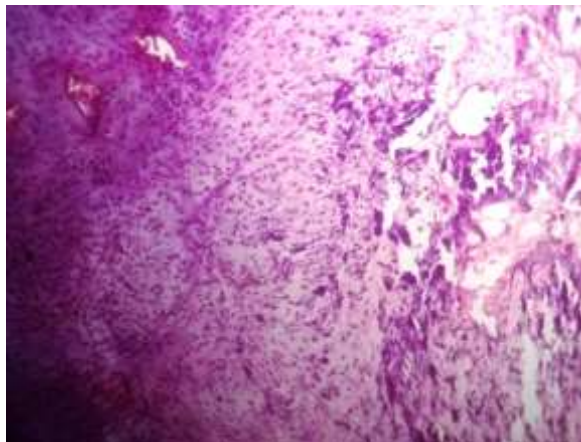
Gross examination revealed well defined mass of 2x2 cm. Cut section showed a firm, whitish tumor with gelatinous and chalky white areas of calcification.



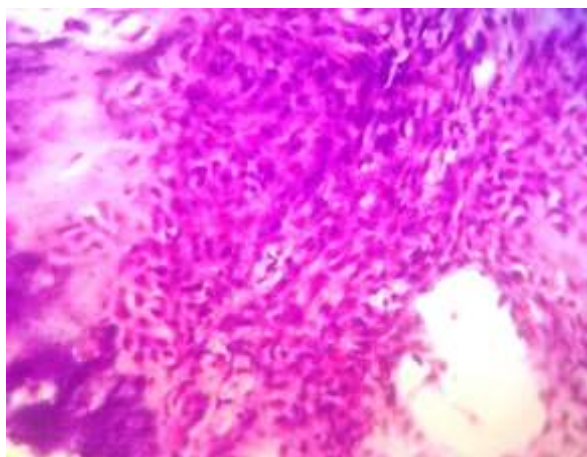
**Fig. 1: X-ray showing soft tissue mass with calcification**

Microscopic examination showed lobules of mature cartilage with varying degree of cellularity separated by fibrous septa (Fig. 2). At places of increased cellularity immature pattern of cells exhibiting chondroblastoma like areas was seen (Fig. 3). The chondroblastic cells were polygonal with moderate to abundant eosinophilic cytoplasm, oval eccentrically placed indented nuclei. Foci of myxoid areas, multinucleated giant cells and metaplastic ossification were also seen. Extensive areas of calcification were noted at the centre of the tumor

(Fig. 2). The differentials of ESC and Extraskelatal myxoid chondrosarcoma were considered. Absence of atypical nuclei, binucleate cells, mitotic figures and necrosis rules out ESMCS and a final diagnosis of Extraskelatal chondroma with chondroblastic differentiation was made.



**Fig. 2: Mature cartilage with varying degree of cellularity and calcification (10 X view)**



**Fig. 3: Cellular Chondroblastoma like areas**

## DISCUSSION

Chondroma of soft parts is a rare benign cartilaginous tumour. It usually arises as slow growing painless mass in adults with age range of 30-60 years [3]. In 1974, Dahlin and Salvador [4] reported a series of 70 patients. In 1978, Chung and Enzinger [2] reviewed the record of 104 cases over 23 years. These two large series and many case reports confirm benign nature of these lesions, their predilection for hands and feet and emphasize their variable histologic appearance which often is confused with chondrosarcoma. It is well known that these tumors may undergo secondary changes or exhibit features that impart a confusing histologic appearance such as dystrophic calcification, enchondral ossification, hemorrhage or myxoid degeneration [2].

Radiographically discrete, irregular, ring like, or curvilinear calcifications are often seen [3]. Grossly,

ESC usually are lobulated, well encapsulated, pearly white cartilaginous lumps that are enucleated easily at surgery [9]. Histopathologically, they can be diverse, ranging from a mature form with hyaline cartilage which is arranged in distinct lobules with fibrosis or ossification or myxoid areas to an immature pattern with a Pre-pondreance of chondroblasts [3, 5, 8]. In 2001, Cates JM and Rosenberg AE [6] reported 8 cases of chondroblastoma like areas in chondroma of soft tissue as seen in our case. One third of them can display granular/floccular calcification which can be focal/diffuse, such areas were also seen in our case. This worrisome cellularity can be mistaken for chondrosarcoma. Like normal chondrocytes, the cells of ESC are positive for vimentin and S100 [3].

Chondroblastoma like ESC have to be differentiated from calcifying aponeurotic fibroma (CAF), tumoral calcinosis, tenosynovial giant cell tumor (GCT), synovial chondromatosis, and ESMCS [2, 3, 5, 6, 8].

CAF is characterized by short bar like foci of cartilaginous metaplasia in a dense, poor circumscribed fibromatous background. It occurs in hand, almost always affects patients < 25 yrs [3, 5, 8].

Tumoral calcinosis may mimic a heavily calcified ESC, but lacks cartilage and it has a distinct histiocytic response to calcified material [3].

Chondroblastoma like ESC may be confused with tenosynovial GCT because of their well circumscribed borders, lobular growth pattern, hypercellularity and presence of epithelioid mononuclear cells with interspersed multinucleated giant cells. Tenosynovial GCT can be distinguished from chondroblastoma like chondroma by collagenous and hyalinized stroma and variable number of siderophages, foamy macrophages and lymphocytes intermixed with mononuclear cells in tenosynovial GCT. These cell types and sclerotic stroma are not observed in chondroblastoma like chondromas [6].

Distinction between ESC and synovial chondromatosis usually made because the latter occurs in large joints and involves the formation of numerous small cartilaginous nodules within the synovium or an adjacent bursa [5].

The cellular and primitive cartilage in chondroblastoma like ESC may resemble that seen in extraskelatal myxoid chondrosarcoma. Unlike chondromas, these tumors are much larger and involve the deep soft tissues of the lower or proximal upper extremities [3, 5, 6]. In contrast to chondroblastoma like ESC, the neoplastic cells of ESMCS are small, round-oval to spindled and have a scant to moderate amount of eosinophilic cytoplasm and ovoid hyperchromatic nuclei with inconspicuous nucleoli. The cells are arranged in short cords, delicate strands or

small nests within abundant myxoid stroma; such architectural patterns not observed in chondroblastoma like ESC. Additionally, multinucleated giant cells and abundant mineralization are not features of ESMCS [6].

Chondroblastoma like ESC thus appear to behave clinically very much like their conventional counterparts. Conservative excision of soft-tissue chondromas is therefore recommended. The potential problem with ESC is that they recur. In the fifty four cases seen by Dahlin and Salvador, there was recurrence in eight cases, during an observation period of 1-10 yrs [4]. Our patient, now after a follow up of two years, is disease free without recurrence.

### CONCLUSION

In summary, chondromas of soft tissue are easily recognized when they are composed entirely of mature hyaline cartilage. However, many secondary or degenerative changes may make the diagnosis more difficult. The unusual variant with chondroblastoma – like areas can simulate more aggressive chondroid neoplasms, but clinical and histopathologic features are helpful in distinguishing them from more ominous lesions.

### REFERENCES

1. Adaletli I, laor T, Yin H, Podberesky DJ; Extraskeletal chondroma: Another diagnostic possibility for a soft tissue axillary mass in an adolescent. *Case Rep Orthop.*, 2011; 2011:309328.
2. Chung EB, Enzinger FM; Chondroma of soft parts. *Cancer*, 1978; 41(4): 1414-1424.
3. Rajalakshmi V, Jayaraman, Anand V, Ramprasad N; Extraskeletal chondroma of foot- a case report. *J Clin Diagn Res.*, 2014; 8(3): 134-135.
4. Dahlin DC, Salvador AH; Cartilaginous tumors of the soft tissues of the hands and feet. *Mayo Clin Proc.*, 1974; 49(10): 721-726.
5. Singh P, Mathur SK, Kundu ZS, Singh S, Marwah N, Arora B; Extraskeletal chondroma of the hand- A case report. *Indian J Pathol Microbiol.*, 2005; 48(2): 206-208.
6. Cates JM, Rosenberg AE, Connell JX, Nielsen PG; Chondroblastoma like chondroma of soft tissue. *Am J Surg Pathol.*, 2001; 25(5): 661-666.
7. Khedhaier A, Maalla R, Ennouri J, Regaya N; Soft tissue chondromas of the hand: A report of five cases. *Acta Orthop Belg.*, 2007; 73(4): 458-461.
8. Weiss SW, Goldblum JR; Cartilaginous soft tissue tumors. In: Weiss SW, Goldblum JR editors; *Enzinger and Weiss's soft tissue tumors*. 4<sup>th</sup> edition, Missouri: Mosby, 2001: 1361-88.
9. Delsignore JL, Torre BA, Miller RJ; Extraskeletal chondroma of the hand: Case report and review of the literature. *Clin Orthop Relat Res.*, 1990; 254: 147-152.