

**Research Article****Androgen Insensitivity Syndrome: An Experience from a Tertiary Centre - Saudi Arabia**

Nasir A. M. Al-Jurayyan<sup>1\*</sup>, Abdullah N. A. Al Jurayyan<sup>2</sup>, Amir M.I. Babiker<sup>3</sup>, Hessah M. N. Al Otaibi<sup>4</sup>,  
Abdulrahman M.H. Al Nemri<sup>5</sup>, Abdullah S. Al Herbish<sup>6</sup>

<sup>1</sup>Professor and Head, Endocrine Division, <sup>3</sup>Assistant Professor and Consultant Endocrinologist, <sup>4</sup>Consultant Pediatric Endocrinologist, <sup>5</sup>Associate Professor and Consultant Neonatologist, <sup>6</sup>Professor of Pediatrics and Endocrinologist, Department of Pediatrics, College of Medicine, King Saud University, Saudi Arabia

<sup>2</sup>Laboratory Service, King Fahad Medical City, Riyadh, Saudi Arabia

**\*Corresponding author**

Dr. Nasir A. M. Al Jurayyan

**Email:** [njurayyan@ksu.edu.sa](mailto:njurayyan@ksu.edu.sa)

---

**Abstract:** Androgen insensitivity syndrome (AIS), formerly known as testicular feminization, is a disorder of sex development caused by mutations in the gene encoding the androgen receptor, and characterized by 46 XY karyotype, bilateral testes, absent Mullerian duct structure, and female appearing external genitalia. This is a retrospective, hospital-based study conducted over 25 years (1989-2014) at King Khalid University Hospital, Riyadh, Saudi Arabia. The case notes, imaging and laboratory investigations were reviewed for patients diagnosed with androgen insensitivity. During the period under review, a total of 16 patients were seen with androgen insensitivity syndrome (AIS), with variable degrees of insensitivity ranging between complete 11 (68.2%) and partial 5 (31.2%). The clinical characteristic and radiological imaging are presented. The extent of androgen insensitivity in 46 XY individuals is not that rare in a community with high incidence of consanguineous mating. A multidisciplinary team approach is essential for successful management.

**Keywords:** Androgen insensitivity syndrome, Clinical characteristic, Imaging, Management.

---

**INTRODUCTION**

Androgen insensitivity syndrome (AIS), previously known as testicular feminization, is an X-linked recessive condition that results in failure of normal masculinization of the external genitalia in chromosomally male individuals. The failure of virilization can be either complete or partial, depending on the amount of receptor function [1-8].

Individuals with complete androgen insensitivity have female external genitalia. The phenotype of these individuals may range from mildly virilized female external genitalia to undervirilized male (Fig. 1). In either case, affected individuals possess normal testes with normal production of testosterone and normal conversion to dihydrotestosterone. Normal production of Mullerian-inhibiting factor (MIF), thus, affected individuals do not have female internal organs [9-12].

The basic aetiology is a loss-of-function mutation in the androgen receptor (AR) gene. Over 1,000 mutations have been described. The incidence of the disease is appropriately 1 case per 20,400 live born males' internationally [13-14].

In this report, we describe our experience over 25 years period (1989-2014) at King Khalid University Hospital, a major tertiary centre, Riyadh, Saudi Arabia.

**MATERIALS AND METHOD**

The study population included all patient's presented to the endocrine service, King Khalid University Hospital (KKUH), Riyadh, Saudi Arabia over a twenty-five years period (1989-2014). King Khalid University Hospital is the main teaching hospital of King Saud University and considered as one of the main referral hospital in the central Saudi Arabia. The hospital provides primary, secondary, and tertiary health care services for the local population and also receive patient's referral from all over the country.

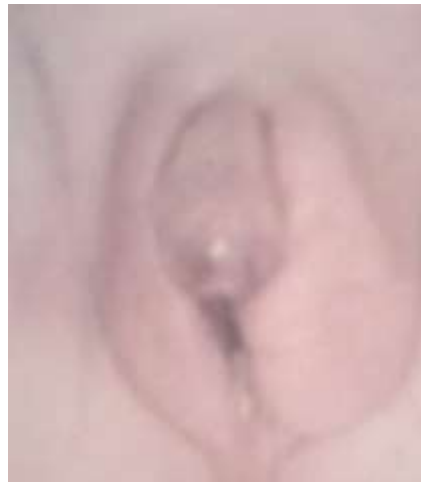Reviewing the clinical notes of patients, the diagnosis of androgen insensitivity was done retrospectively. The medical history and clinical examination were also reviewed. The appropriate diagnosis was based on (radiological and serological) evaluation. Unfortunately, no genetic studies were performed. All patients were managed by an experienced multi-disciplinary team constitute of a pediatric endocrinologist, neonatologist, geneticist, psychologist,

and a pediatric surgeon or urologist. Ethical approval for this study was obtained from the Institutional Review Board (IRB) at King Khalid University Hospital.

**RESULTS**

During the period under review a total of 16 patients with androgen insensitivity were seen with variable

degrees of insensitivity ranging between complete 11 (68.8%) and partial 5 (31.2%), insensitivity. Table 1 shows their clinical characteristics, presenting from birth to adulthood. Ultrasound imaging remains the first modality used for evaluation (Fig. 2), as it is cheap and readily available. However, magnetic resonance imaging (MRI), provides more tissue characteristics and detection of the intra-abdominal gonads (Fig. 3).

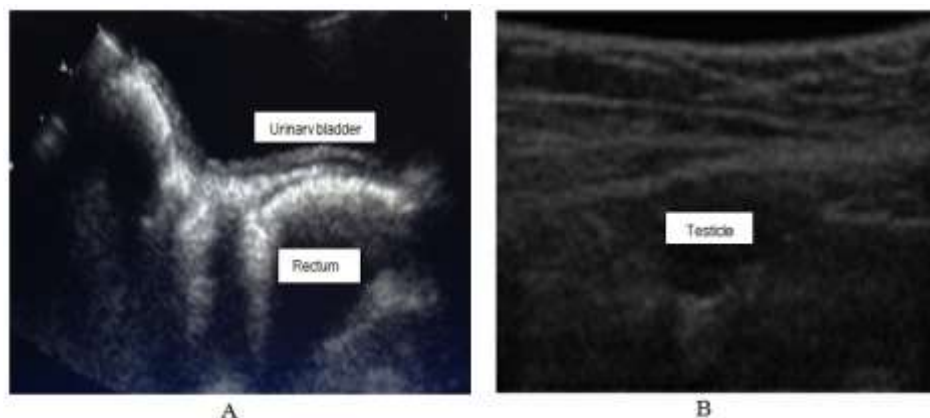


**Fig. 1: Ambiguous genitalia in a 46, XY patient known to have partial androgen insensitivity. Note the micropenis, urogenital sinus, and labioscrotal folds (the left fold contains a palpable gonad).**

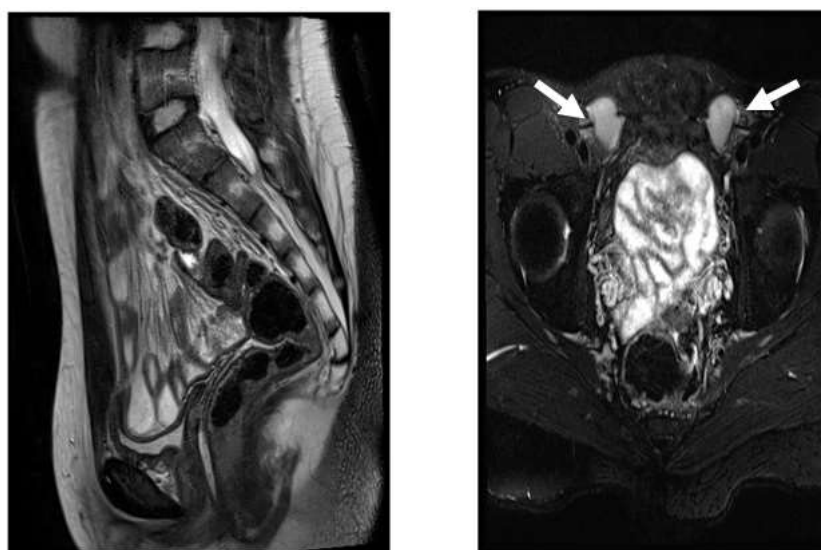
**Table 1: Clinical characteristics in 16 patients with androgen insensitivity syndrome (CAIS)**

Patient	Age at presentation	Clinical features	Family history	Sex of rearing
1	3 y	Inguinal hernia	-ve	Female
2	15 y	Delayed puberty	-ve	Female
3	Newborn	Severe hypospadias	-ve	Female
4	Newborn	Normal female genitalia	+ve	Female
5	Newborn	Normal female genitalia	+ve	Female
6	4 y	Inguinal hernia	-ve	Female
7	Newborn	Normal female genitalia	+ve	Female
8	Newborn	Bilateral undescended testis, micropenis, chorde, bifid scrotum	+ve	Female
9	Newborn	Normal female genitalia	+ve	Female
10	15 y	Delayed puberty	-ve	Female
11	16 y	Delayed puberty	-ve	Female
12	Newborn	Ambiguous genitalia	+ve	Male
13	Newborn	Micropenis with bilateral undescended testes	+ve	Male
14	3 m	Micropenis normal descended testes	-ve	Male
15	6 m	Micropenis bifid scrotum Normal descended testes	-ve	Male
16	18 m	Micropenis with chorde and bilateral undescended testes	-ve	Male

All patients had 46 XY karyotype and no female internal structures were noted. -ve = negative; +ve = positive



**Fig. 2:** Trans-abdominal ultrasonography showing no female internal structures (A), and atestes (B) in the inguinal canal in a patient with complete androgen insensitivity syndrome (CAIS).



**Fig. 3:** Magnetic resonance imaging (MRI) a T<sub>2</sub>-weighted image demonstrating no internal female structure (A) and (B) bilateral testes (arrow) within the abdomen in a patient with complete androgen insensitivity syndrome (CAIS).

## DISCUSSION

Androgen insensitivity syndrome (AIS) is a genetic condition. In an individual with complete AIS and karyotype 46 XY, testes develop during gestation, with production of Mullerian inhibiting hormone (MIH) and testosterone. MIH causes the regression of fetal Mullerian ducts. But, due to the failure to respond to testosterone; genitals differentiate in the female rather than the male pattern. Thus, the newborn infant has genital of normal female appearance, undescended or partially descended testes. While in the partial form, variable ambiguity of the genitalia is encountered. The condition is not that rare in a community with high prevalence of consanguineous mating [15] as in Saudi Arabia.

The diseases have variable presentation from a normal female genitalia with 46 XY karyotype, through variable genital ambiguity, to delayed puberty in a normal looking female individuals, or an infertile male syndrome. Many of the patients, with the syndrome

have no pubic or axillary hair. A multidisciplinary team approach is needed, to ensure better prognosis [16]. An experienced pediatric surgeon or urologist is needed, either for genital penile reconstruction or vaginoplasty. The pediatric radiologist plays an important role in delineating the various internal structures and testes. At the time of diagnosis AIS, whether complete or partial, imaging should be ordered to evaluate the internal genitalia and location of the gonads. Ultrasound remains the best choice. However, Magnetic Resonance Imaging (MRI) is the study of choice for evaluation as it provides more tissue characterization and detection of intra-abdominal gonads, but it most costly and least accessible [17].

Patients with complete androgen insensitivity, lack response to testosterone and, therefore, should be raised as females. It is advisable to remove the gonads at the time of diagnosis rather than wait until puberty, to avoid the adverse effects of testosterone on the neurons and to minimize the risk of the development of

gonadoblastoma. Availability of oestrogen replacement therapy allows gender re-assignment in these cases. But, use of oestrogen replacement therapy was debated recently. It has been suggested that the removal of gonads should be deferred until puberty to allow for oestrogen formation. On the other hand, in cases where genetic male demonstrate any appreciable response to exogenous stimulation, a testosterone treatment of short duration might indicate the degree of masculinization achievable at puberty and facilitate the decision to raise such an individual as a male [18, 19].

### CONCLUSION

The extent of androgen insensitivity in 46 XY individuals is not that rare in a community with high incidence of consanguineous mating. A multidisciplinary team approach is essential for successful management.

### ACKNOWLEDGEMENT

The authors would like to thank Ms. Loida M. Sese for her secretarial assistance and extend their thanks and appreciation to the College of Medicine Research Centre, Deanship of Scientific Research, King Saud University, Riyadh, for funding this work.

### REFERENCES

1. Griffin JE, Wilson JD; The syndromes of androgen resistance. *N Engl J Med.*, 1980; 302(4): 198-209.
2. Hashmi A, Hanif F, Hanif SM, Abdullah FE, Shamin MS; Complete androgen insensitivity syndrome. *J Coll Physicians Surg Pak.*, 2008; 18(7): 442-444.
3. Oakes MB, Eyvazzadesh AD, Quint E, Smith YR; Complete androgen insensitivity syndrome – a review *J Pediatr Adolesc Gynecol.*, 2008; 21(6): 305-310.
4. Hughes IA, Deeb A; Androgen resistance. *Best Pract Res Clin Endocrinol Metab.*, 2006; 20(4): 577-598.
5. Hughes IA, Werner R, Bunch T, Hiort O; Androgen insensitivity syndrome. *Semin Repr Med.*, 2012; 30(5): 432-442.
6. Hughes IA, Davies JD, Bunch TI, Pasterski V, Mastroyannopoulou K, MacDougall J; Androgen insensitivity syndrome. *Lancet*, 2012; 380(9851): 1419-1428.
7. Hiort O; Clinical and molecular aspects of androgen insensitivity. *Endocr Dev* 2013; 24:33-40.
8. Gottlieb B, Pinsky L, Beitel LK, Trifiro M; Androgen insensitivity. *Am J Med Genet.*, 1999; 89: 210-217.
9. Quigley CA, De Bellis A, Marscike KB, El Awady MK, Wilson EM, French FS; Androgen receptor defects: historical, clinical and molecular perspective. *Endocr Dev.*, 1995; 16(3): 271-321.
10. Deans R, Creighton SM, Liao LM, Conway GS; Timing of gonadoectomy in adult women with complete androgen insensitivity syndrome (CAIS) patients preference and clinical evidence. *Clin Endocrinol (Oxf).*, 2011; 76(6): 894-898.
11. Boehmer AL, Brinkmann O, Brüggewirth H, van Assendelft C, Otten BJ, Verleun-Mooijman MC *et al.*; Genotype versus phenotype in families with androgen insensitivity syndrome. *J Clin Endocrinol Metab.*, 2001; 86(9): 4151-4160.
12. Zuccarello D, Ferlin A, Vinanzi C, Prana E, Garolla A, Callewaert L *et al.*; Detailed functional studies on androgen receptor mild mutation demonstrate their association with male infertility. *Clin Endocrinol (Oxf).*, 2008; 68(4): 580-588.
13. Elfferich P, van Royen ME, van de Wijngaart DJ, Trapman J, Drop SL, van den Akker EL *et al.*; Variable loss of functional activities of androgen receptor mutations in patients with androgen insensitivity syndrome. *Sex Dev.*, 2013; 7(5): 223-234.
14. Galani A, Kitsiou-Tzeli S, Sofokleous C, Kanavakis E, Kalpini-Mavrou A; Androgen insensitivity syndrome: clinical features and molecular defects. *Hormones (Athens)*, 2008; 7(3): 217-229.
15. Saedi-Wong S, Al Frayh AR, Wong HYM; Socio-economic epidemiology of consanguineous mating in Saudi Arabian population. *J Asian Afr Stu.*, 1989; 24: 247-252.
16. Al-Jurayyan NAM; Ambiguous genitalia: two decades of experience. *Ann Saudi Med.*, 2011; 31(3): 284-288.
17. Khan S, Craig L; A review of radiologic imaging in patients with androgen insensitivity. *J Genit Syst Disor.*, 2013: S1.
18. Hughes IA, Houk C, Ahmed SF, Lee PA; Consensus statement on management of intersex disorders. *J Pediatr Urol.*, 2006; 2(3): 148-162.
19. Rajpert-De Meyts E; Developmental model for the pathogenesis of testicular carcinoma in status: genetic and environmental aspect. *Human Reproduction Update*, 2006; 12(3): 303-323.