

Case Report

An Uncommon Cause of Recurrent Sub-Ileus and Abdominal Pain: Meckel's Diverticulum Inverted by a Lipoma

Mustafa Ugur^{1*}, Cem Oruc¹, Seckin Akkucuk¹, Orhan Veli Özkan², İbrahim Yetim¹, Güvenç Diner¹, Yılmaz Yiğit¹, İlhan Paltacı¹

¹ Medicine School of Mustafa Kemal University, Department of General Surgery, Hatay, Turkey

² Medicine School of Sakarya University, Department of General Surgery, Hatay, Turkey

***Corresponding author**

Mustafa Ugur, M.D

Email: drmustafaugur@gmail.com

Abstract: Complications of Meckel's diverticulum are seen rarely in adults. Most common complications are intestinal obstruction and diverticulitis. Obstruction caused by inversion of Meckel's diverticulum by intestinal tract lipomas is a much more rare condition. Preoperative diagnosis is difficult due to absence of specific clinical signs. Diagnosis becomes even more difficult when the symptoms are mild. In this article, a 45 years old female patient with intermittent signs of mild intestinal obstruction ongoing for approximately a year is presented. By the use of abdominal computerized tomography, the patient was diagnosed with Meckel's diverticulum inverted by a lipoma and was treated surgically.

Keywords: Meckel's diverticulum, Lipoma, Ileus

INTRODUCTION

Meckel's diverticulum is a true diverticulum containing all the layers of intestinal wall; caused due to unclosure of omphalomesenteric duct which is supposed to regress during intrauterine life. It is the most common congenital anomaly of gastrointestinal system in adults [1].

Meckel's diverticulum can be diagnosed coincidentally without any symptoms as well as it may appear with life-threatening complications. Incidence of these complications is less than 5% and they consist of mechanical intestinal obstruction, intussusceptions, bleeding and diverticulitis [2, 3].

Lipomas located in gastrointestinal system are rare, benign tumours located submucosally or subserosally. Especially small intestinal lipomas are extremely rare. Although they are mostly asymptomatic, they may cause abdominal pain, gastrointestinal bleeding, ileus, subileus or invagination. They are mostly diagnosed coincidentally during operation [3].

In this study a case of Meckel's diverticulum inverted by lipoma causing repeating episodes of subileus and diagnosed preoperatively via abdominal computerized tomography.

CASE REPORT

54 years old female patient applied our clinic with intermittent episodes of nausea, vomiting and abdominal pain which started approximately 1 year ago. On her medical background she did not have any comorbidities or previous abdominal operations. Physical examination revealed minimal sensitivity with deep palpation on epigastric area. Defense and rebound were not seen. Intestinal auscultation revealed normoactive intestinal sounds. Complete blood count and biochemical parameters did not reveal any abnormal values. Erect abdominal radiography showed few air-fluid levelings located on intestinal loops. Abdominal ultrasonography did not show any pathology. Complete abdominal computerized tomography revealed a lesion conformable with lipoma which was located on intestinal loop, was 32 mm in diameter and caused narrowing of the lumen and inversion (Fig. 1A, 1B). The complaints of the patient were thought to be caused by this so elective operation was planned. During operation, abdomen was reached via supraumbilical incision approximately of 7cm in size. During exploration Meckel's diverticulum which was inverted by subserosal lipoma of 4cm in diameter was found located on 70 cm proximally of ileocecal valve (Fig. 2-3). The excision of lipoma was followed by diverticulectomy and jejunal lumen was enclosed biperforated. The patient who did not develop any complications postoperatively was discharged on 4th day.

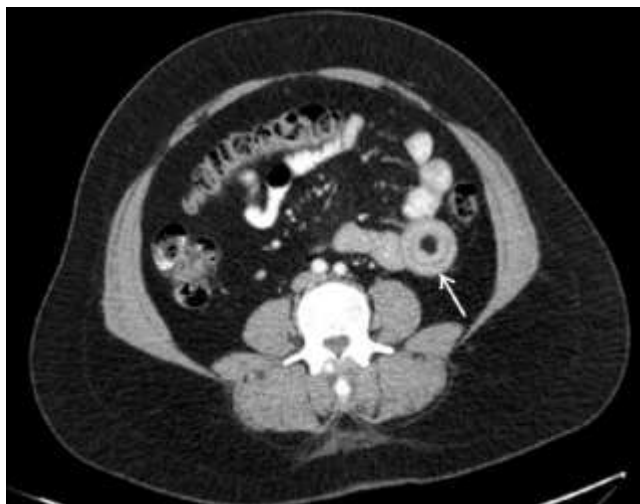

Fig. 1: Intussusception due to lipoma in Meckel's diverticulum (Abdominal Computed tomography)

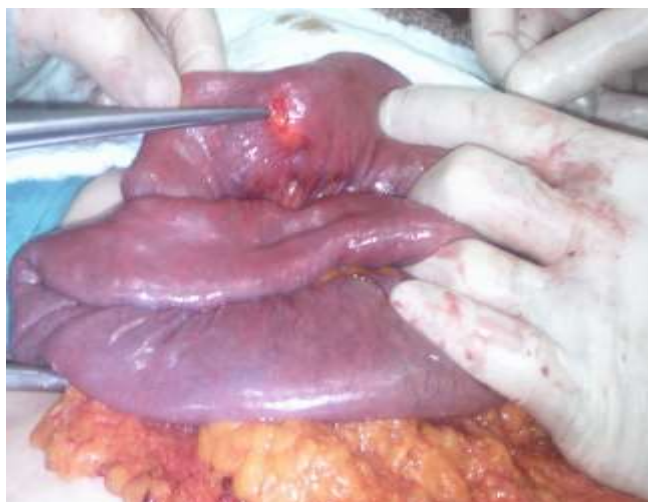

Fig. 2: Lipoma in Meckel's diverticulum

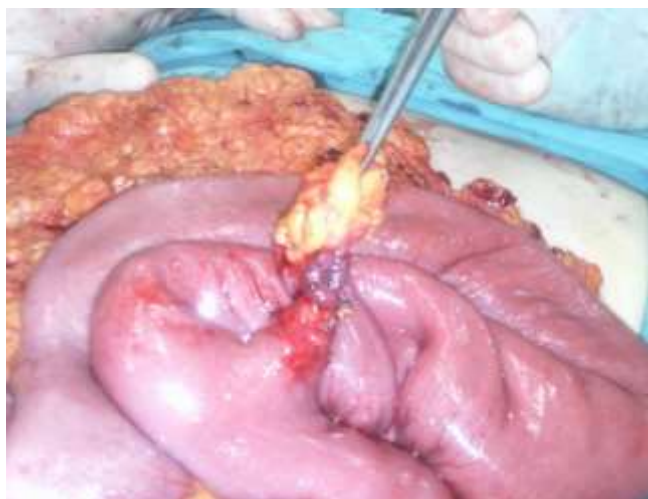


Fig. 3: Meckel's diverticulum with lipoma

DISCUSSION

Meckel's diverticulum is caused by unclosure of omphalomesenteric duct which is supposed to regress on intrauterine 7-8th weeks and is the most common anomaly of gastrointestinal tract. Incidence in

population is 2-4%. Most of these cases do not show any symptoms. Symptomatic Meckel's diverticula are more common in children than adults. Lifelong complication rate is approximately 4% [2, 4, 5]. Common complications include bleeding in gastrointestinal tract, obstruction and diverticulitis [5]. While bleeding and obstruction are more common with pediatric population, obstruction and diverticulitis are seen more commonly with adults. It is seen 2-4 times more common in women than men [2, 6].

Most common complication of Meckel's diverticulum in adults is intestinal obstruction. Clinical signs of obstruction in adults last for weeks or months and consist of abdominal pain, nausea, vomiting, rectal hemorrhage, changes in intestinal habits and weight loss [7]. Most common cause is intussusception or invagination. Other causes are volvulus developing around fibrous bands extending towards umbilicus, inflammatory adhesions and Littre's hernia [4]. A rare cause of obstruction is a tumour developing within diverticulum. Histologically these tumours resemble small intestine tumours. Commonly seen benign tumours are; myoma, lipoma, neuroma, adenoma; malign tumours are adenocarcinoma, leiomyosarcoma and carcinoid tumours. Malignant tumours are 3 times more common than benign tumours and usually are symptomatic while benign tumours are mostly asymptomatic. Development of a lipoma within Meckel's diverticulum and obstruction caused by this lipoma by causing inversion of diverticulum is a condition encountered much more rarely [8]. As clinical signs are non-specific they usually are difficult to diagnose preoperatively. But radiological procedures like radiographies with barium, computerized tomography are useful for preoperative diagnosis [9]. In our case the patient had intermittent complaints of abdominal pain, nausea and vomiting ongoing for approximately a year. The patient applied different hospitals with these complaints and received treatments for 4 times but her complaints repeated every time. Endoscopic procedure has not shown any pathology. Most important factors for delaying the diagnosis were thought to be non-specificity and mildness of patient's complaints. Abdominal CT was planned as the complaints were ongoing for a while and a definitive diagnosis could not be achieved despite recurrences.

Filling defect located on distal ileum seen on barium radiography suggests inverted Meckel's diverticulum or a mass lesion. Coil spring image is characteristic for intussusception. Computerized tomography is ineffective to reveal Meckel's diverticulum since radiological differentiation between Meckel's diverticulum and intestinal loops is not clear. But if serosal fat tissue caused inversion of Meckel's diverticulum, filling defect shaped as concentric circles in fat tissue density can be seen at that localization. When this image is seen, differential diagnosis should be considered. This could be a lipoma located at distal

ileum, an inflammatory fibroid polyp or a pedunculated polyp seen with familial adenomatous polyposis coli and Peutz-Jeghers syndrome. Gastrointestinal tract lipomas are seen more commonly located in the colon. They are seen rarely at distal ileum. If circular image surrounding fat tissue density is seen, then Meckel's diverticulum inverted by a lipoma should be considered. Inflammatory fibroid polyps are usually found in stomach and do not show fat tissue on computerized tomography. Lesions associated with polyposis syndromes tend to be multiple by contrast with inverted Meckel's diverticulum [10]. Computerized tomography of our case showed lesions of 32 mm in diameter located on an intestinal loop surrounded by concentric circles, causing narrowing of intestinal lumen and inversion which are coherent with lipoma. Because the lesion was single, located on intestinal loop and showed characteristic image, the patient was diagnosed with lipoma causing inversion of Meckel's diverticulum, operated and discharged without developing any complications.

CONCLUSION

Lipomas located within Meckel's diverticulum are extremely rare and may cause intestinal obstruction by inversion of the diverticulum. It is difficult to diagnose preoperatively as it does not present any specific symptoms. Abdominal computerized tomography is useful for diagnosis especially with patients having mild and intermittent intestinal obstructions. A circular image of fat density located at the distal ileum in abdominal computerized tomography may suggest a lipomatous lesion causing inversion of Meckel's diverticulum.

REFERENCES

1. Akçakaya A, Alimoğlu O, Özkan OV, Şahin ML; Komplikasyonlu Meckel divertikülleri, *Ulus Travma Derg.*, 2003; 9(4):246-249.
2. Chen JJ, Lee HC, Yeung CY, Chan WT, Jiang CB, Sheu JC, Wang NL; Meckel's Diverticulum: Factors associated with clinical manifestations. *ISRN Gastroenterol.*, 2014; 1;2014:390869.
3. Jai SR, Bensardi F, Chehab F, Khaiz D, Bouzidi A; Jejunal lipoma with intermittent intussusception revealed by partial obstructive syndrome. *Saudi J Gastroenterol.*, 2008; 14(4): 206-207.
4. Dumper J, Mackenzie S, Mitchell P, Sutherland F, Quan ML, Mew D. Complications of Meckel's diverticula in adults. *Can J Surg.*, 2006; 49(5): 353-357.
5. Park JJ, Wolff BG, Tollefson MK, Walsh EE, Larson DR; Meckel diverticulum: the Mayo Clinic experience with 1476 patients (1950-2002). *Ann Surg.*, 2005; 241(3): 529-533.
6. Stone PA, Hofeldt MJ, Campbell JE, Vedula G, DeLuca JA, Flaherty SK; Meckel diverticulum: ten-year experience in adults. *South Med J.*, 2004; 97(11): 1038-1041.

7. Ahmed HU, Wajed S, Krijgsman B, Elliot V, Winslet M; Acute abdomen from a Meckel lipoma. *J R Soc Med.*, 2004; 97(6): 288-289.
8. Krespis EN, Sakorafas GH; Partial intestinal obstruction caused by a lipoma within a Meckel's diverticulum. *Dig Liver Dis.*, 2006; 38(5): 358-359.
9. Dujardin M, de Beeck BO, Osteaux M; Inverted Meckel's diverticulum as a leading point for ileoileal intussusception in an adult: case report. *Abdom Imaging*, 2002; 27(5): 563-565.
10. Turkington JR, Devlin PB, Dace S, Madden M; An unusual cause of intermittent abdominal pain (2006: 5b). Inverted Meckel's diverticulum. *Eur Radiol.*, 2006; 16(8):1862-1864.