

Case Report

Maintenance Therapy with Procarbazine and Chlorambucil without Autologous Stem Cell Transplantation as a New Option for Patient with Hodgkin Lymphoma

Mehrdad Payandeh¹, Masoud Sadeghi^{2*}, Edris Sadeghi³

¹Department of Hematology and Oncology, Kermanshah University of Medical Sciences, Kermanshah, Iran

²Students Research Committee, Kermanshah University of Medical Sciences, Kermanshah, Iran

³Department of Nursing, Kermanshah University of Medical Sciences, Kermanshah, Iran

***Corresponding author**

Masoud Sadeghi

Email: sadeghi_mbrc@yahoo.com

Abstract: Hodgkin lymphoma (HL) affects patients of all ages, particularly adolescents and young adults between 16-34 years. Patients with HL who relapse following effective front-line therapy are offered salvage second-line chemotherapy regimens followed by high-dose therapy and autologous stem cell transplantation. The aim of this study is a report of a HL patient that treated with maintenance therapy without autologous stem cell transplantation (ASCT) and radiotherapy for four months and had a complete response (CR). In Spring 2014, A 54 year-old women referred to our Clinic. Six years ago was treated with diagnosis of HL stage 2B with cervical and mediastinal involvement and she was treated with 6 courses from ABVD (adriamycin, belomycin, vinblastine and dacarbazine) regimen. During last six months ago with chief complaints of abdominal pain, weight loss and fever referred to Hematology Clinic. In restating, after bone marrow biopsy and whole body CT scan, both lungs and right side of liver were involved. We selected second-line chemotherapy individualized, second-line chemotherapy of ICE (ifosfamide, carboplatin, etoposide) regimen. The patient was selected for ASCT but she denied of this recommendation. We decide that continue maintenance therapy of procarbazine and chlorambucil for this patient. Final message of this case is that maintenance therapy can be considered in HL relapse cases that not referred for another new decision (such as ASCT), either by patient or manager team, and this regimen can be a new option for patients with HL.

Keywords: Autologous Stem Cell Transplantation, Hodgkin Lymphoma (HL), Maintenance Therapy.

INTRODUCTION

Hodgkin lymphoma (HL) affects patients of all ages, particularly adolescents and young adults (ages 16-34) [1]. Relapses occur in 20-30% of patients with HL [2]. Patients with HL who relapse following effective front-line therapy are offered salvage second-line chemotherapy regimens followed by high-dose therapy and autologous stem cell transplantation (ASCT) [3]. More than 70% of patients can be cured with the current strategies based on chemotherapy, with or without radiotherapy. One-third of the cases finally relapses and need salvage regimens that are usually consolidated with high-dose chemotherapy and ASCT [4].

Herein, we reported a patient with HL that treated with maintenance therapy without ASCT and radiotherapy for four months and had a complete response (CR).

CASE REPORT

Spring 2014, A 54 year-old women referred to our Clinic. Six years ago was treated with diagnosis of Hodgkin Lymphoma (HL) stage 2B with cervical and

mediastinal involvement and she was treated with 6 courses from ABVD (adriamycin, belomycin, vinblastine and dacarbazine) regimen. During last six years in close follow up be without symptom and all laboratory and imaging was normal. During last six months ago with chief complaints of abdominal pain, weight loss and fever referred to Hematology Clinic. In further evaluation multiple well defined masses detected in lung CT scan and right liver lobe in CT scan (Fig. 1). Suspected relapse should be confirmed with liver CT guided biopsy, and in complimentary immunohistochemistry (IHC), CD30 and CD15 both were positive. This patient had long disease-free intervals but with unfavorable features (B-symptom, and parenchyma involvement). In restating, after bone marrow biopsy and whole body CT scan, both lungs and right side of liver were involved. We selected second-line chemotherapy individualized, second-line chemotherapy of ICE (ifosfamide, carboplatin, etoposide) regimen as an appropriate treatment for this patient with relapsed disease, with the length of initial remission. After four courses (time between course of chemotherapy in ICE regimen be 2 weeks) for 2 months, all lesions of lung and liver

resolved (Fig. 2) and patient was selected for ASCT but she denied of this recommendation. We decide that continue maintenance therapy of procarbazine and

chlorambucil for this patient. At now after four months of this policy she is alive and all lesions also subside and achieved a CR.

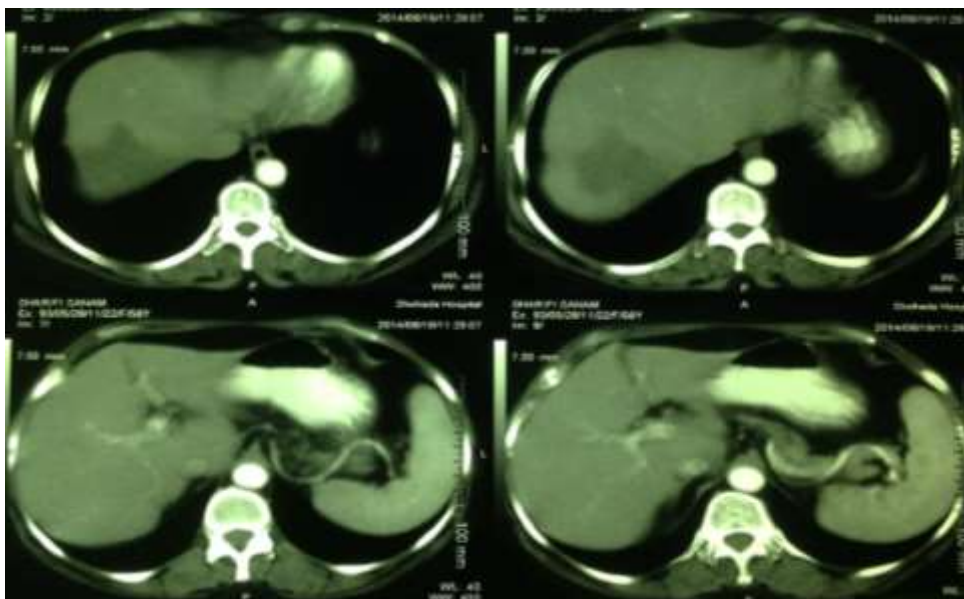


Fig. 1: CT scan of abdominal shows a well define hypo-dense mass from liver before treatment in the beginning of disease

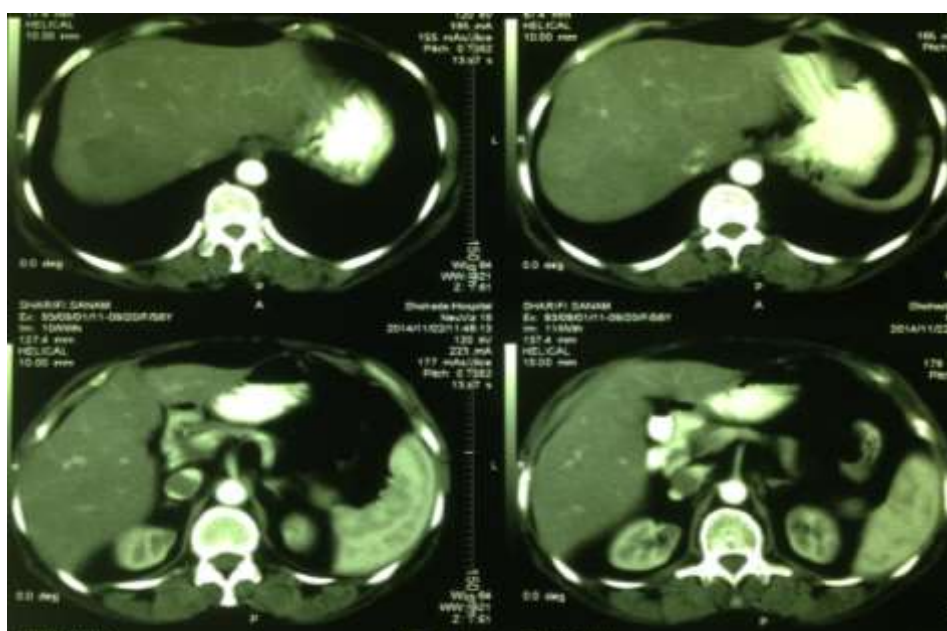


Fig. 2: CT scan of abdominal of patient after 4 courses of chemotherapy that shows resolution of live lesion

DISCUSSION

The NCCN Clinical Practice Guidelines in Oncology (NCCN Guidelines) for HL include the clinical management of classical HL and lymphocyte-predominant HL (LPHL) [5]. Historically, radiotherapy (RT) to all involved lymph node volumes was the first available curative treatment for children and adults [1]. The standard treatment for relapsed or refractory (rel/ref) HL is high-dose chemoradiotherapy followed by ASCT [6-9] or a salvage regimen (ICE) followed by ASCT [10]. The ICE regimen is an effective, dose-

intense, short-course cytoreductive regimen capable of mobilizing peripheral blood progenitor cells (PBPCs) with minimal extramedullary toxicity [11].

Approximately 80% of patients with advanced stage HL achieve a CR when treated with ABVD, [12,13] the current gold-standard up-front HL therapy in the United States, or ABVD/MOPP (mechlorethamine, vincristine, procarbazine, and prednisone) hybrid therapy [13]. Druker BJ *et al.* [14] concluded that chlorambucil, vinblastine, procarbazine,

and prednisone (ChlVPP) appears as effective as MOPP chemotherapy for Hodgkin's disease in comparable presentations but is a less toxic regimen. ABVD continues to be the standard of care for patients with advanced stage HL although escalated BEACOPP (bleomycin, etoposide, adriamycin, cyclophosphamide, vincristine, procarbazine, prednisone) has improved survival in one randomized controlled trial (RCT) [15].

A study [16] reported that vinorelbine, paclitaxel, etoposide, and cisplatin (VTEPA) is a promising regimen for HL patients in whom previous lines of therapy have failed.

Another study in 2014 [17] for four patients showed that all patients received the ABVD regimen followed by salvage treatment with ICE regimen. After relapse, patients were subsequently treated with brentuximab as maintenance therapy. Only 1 of the 4 patients achieved a CR after nine cycles, 2 of the other 3 had progressive disease after partial response, and in the fourth patient disease progressed immediately after brentuximab treatment.

In our study, the patient was treated with ABVD (first-line chemotherapy) and then ICE (second-line chemotherapy) without radiotherapy. The important thing is that in our patient without ASCT and with maintenance therapy (procarbazine and chlorambucil), her lesions in liver and lung was reduced and had a CR. This treatment is a new treatment about HL.

CONCLUSION

Final message of this case is that maintenance therapy can be considered in HL relapse cases that not referred for another new decision (such as ASCT), either by patient or manager team, and this regimen can be a new option for patients with HL.

REFERENCES

1. Pieters RS, Wagner H, Baker S, Morano K, Ulin K, Cicchetti MG *et al.*; The impact of protocol assignment for older adolescents with Hodgkin lymphoma. *Front Oncol.*, 2014; 28:4:317.
2. Móciková H, Sýkorová A, Stěpanková P, Marková J, Michalka J, Král Z *et al.*; Treatment and Prognosis of Relapsed or Refractory Hodgkin Lymphoma Patients Ineligible for Stem Cell Transplantation. *Klin Onkol.*, 2014 Winter; 27(6):424-428.
3. Reddy NM, Perales MA; Stem Cell Transplantation in Hodgkin Lymphoma. *Hematol Oncol Clin North Am.*, 2014; 28(6): 1097-1112.
4. Gutierrez A, Rodriguez J, Martinez-Serra J, Gines J, Paredes P, Garcia F *et al.*; Gemcitabine and oxaliplatin: an effective regimen in patients with refractory and relapsing Hodgkin lymphoma. *Onco Targets Ther.*, 2014; 7: 2093-2100.
5. Hoppe RT, Advani RH, Ai WZ, Ambinder RF, Aoun P, Bello CM *et al.*; Hodgkin lymphoma, version 2.2012 featured updates to the NCCN guidelines. *J Natl Compr Canc Netw.*, 2012.10(5):589-97.
6. Moskowitz AJ, Yahalom J, Kewalramani T, Maragulia JC, Vanak JM, Zelenetz AD *et al.*; Pretransplantation functional imaging predicts outcome following autologous stem cell transplantation for relapsed and refractory Hodgkin lymphoma. *Blood.* 2010.116(23):4934-7.
7. Schmitz N, Pfistner B, Sextro M, Sieber M, Carella AM, Haenel M *et al.*; Aggressive conventional chemotherapy compared with high-dose chemotherapy with autologous haemopoietic stem-cell transplantation for relapsed chemosensitive Hodgkin's disease: a randomised trial. *Lancet.* 2002; 359(9323): 2065–2071.
8. Keller SF, Kelly JL, Sensenig E, Andreozzi J, Oliva J, Rich L *et al.*; Late relapses following high-dose autologous stem cell transplantation (HD-ASCT) for Hodgkin's lymphoma (HL) in the ABVD therapeutic era. *Biol Blood Marrow Transplant*, 2012; 18(4): 640-647.
9. Crump M; Management of Hodgkin lymphoma in relapse after autologous stem cell transplant. *Hematology Am Soc Hematol Educ Program*, 2008: 326–333.
10. George B, Benson W, Hertzberg MS; A pilot study on the use of outpatient fractionated ifosfamide, carboplatin and etoposide (ICE) and pegfilgrastim as a salvage and mobilizing regimen for relapsed and refractory non-Hodgkin's and Hodgkin's lymphoma. *Bone Marrow Transplant*, 2012; 47(7):1001-1002.
11. Kewalramani T, Zelenetz AD, Nimer SD, Portlock C, Straus D, Noy A *et al.*; Rituximab and ICE as second-line therapy before autologous stem cell transplantation for relapsed or primary refractory diffuse large B-cell lymphoma. *Blood*, 2004; 103(10): 3684-3688.
12. Smith SD, Moskowitz CH, Dean R, Pohlman B, Sobecks R, Copelan E *et al.*; Autologous stem cell transplant for early relapsed/refractory Hodgkin lymphoma: results from two transplant centres. *Br J Haematol.*, 2011; 153(3): 358-363.
13. Duggan DB, Petroni GR, Johnson JL, Glick JH, Fisher RI, Connors JM *et al.*; Randomized comparison of ABVD and MOPP/ABV hybrid for the treatment of advanced Hodgkin's disease: report of an intergroup trial. *J Clin Oncol.*, 2003; 21(4): 607–614.
14. Druker BJ, Rosenthal DS, Canellos GP; Chlorambucil, vinblastine, procarbazine, and prednisone. An effective but less toxic regimen than MOPP for advanced-stage Hodgkin's disease. *Cancer*, 1989; 63(6):1060-1064.
15. Uhm J, Kuruvilla J; Treatment of newly diagnosed advanced stage Hodgkin lymphoma. *Blood Rev.*, 2012; 26(4): 167-174.

16. Sinha R, Shenoy PJ, King N, Lechowicz MJ, Bumpers K, Hutcherson D *et al.*; Vinorelbine, paclitaxel, etoposide, cisplatin, and cytarabine (VTEPA) is an effective second salvage therapy for relapsed/refractory Hodgkin lymphoma. Clin Lymphoma Myeloma Leuk., 2013; 13(6): 657-663.
17. Carlson RH; Hodgkin lymphoma: brentuximab active in relapsed disease, but use as maintenance debated. Oncology Times, 2014; 36(3): 38-39.