

## **Case Report**

### **Isolated Muscular Cysticercosis: A Rare Presentation of a Common Helminth**

**K. Krishna<sup>1</sup>, B. Purandare<sup>2</sup>, R. Chauhan<sup>3\*</sup>**

<sup>1</sup>Professor of Medicine & Rheumatologist, Bharati Vidyapeeth Deemed University Medical College, Pune, Maharashtra, India

<sup>2</sup>Infectious Disease Specialist, Department of Medicine, Bharati Vidyapeeth Deemed University Medical College, Pune, Maharashtra, India

<sup>3</sup>Post Graduate Student, Department of Medicine, Bharati Vidyapeeth Deemed University Medical College, Pune, Maharashtra, India

#### **\*Corresponding author**

Dr. R.Chauhan

Email: [rajatmessi.rc@gmail.com](mailto:rajatmessi.rc@gmail.com)

---

**Abstract:** Cysticercosis is a parasitic disease caused by *Taenia solium*, a common public health problem in developing countries. Infection occurs due to the ingestion of raw or undercooked meat that contains the cysticercus. After penetrating the walls of the alimentary tract, larvae reach the blood stream. Though cysticerci can be found any part of the body, but more commonly found in brain, eye, skeletal muscle and subcutaneous tissue. We report an unusual case, with a lump on medial aspect of right mid – arm. Diagnosis of intramuscular cysticercosis was confirmed by MRI.

**Keywords:** Cysticercosis, Muscular cysticercosis, Isolated swelling, Pseudotumor, Helminth.

---

## **INTRODUCTION**

Cysticercosis is parasitic infection of tissues caused by cysticercus as a result of ingestion of eggs of *Taenia solium* [1]. Cysticercosis is a common worldwide infection, endemic in South East Asia, Central and South America and Africa [2, 3]. Human is the definitive host and pig can act as the intermediate host [3, 4]. Human get affected due to the ingestion of *T. solium* egg-contaminated soil, water or food (mainly vegetables) [1]. In humans, the organisms penetrate the intestinal wall and invade subcutaneous tissue, brain, eye, heart, muscle, lung, liver and peritoneum [5].

Intra muscular cysticercosis is a very rare [6, 7] finding and is not easily diagnosed due to vague symptoms on presentation and fewer cases have been reported. Hereby we are reporting an unusual case, with a lump on medial aspect of right mid – arm.

## **CASE REPORT**

A 15 yr male, student, with no major illness, presented in Medicine Outpatient clinic with complaints of fever, pain and swelling over inner aspect of right mid-arm since last 8-10days, with history of increase in size of the swelling over last 4-5 days, swelling became more prominent with contraction of muscle, pain increased on flexion at elbow joint and on lifting heavy objects. Patient has no significant past medical history or family history. Patient is a pure vegetarian by diet with no addictions.

### **On General examination**

Patient was afebrile. Pulse was 96/m and B.P was 110/70 mm of Hg, no pallor, icterus or edema was present.

### **Local examination**

Diffuse small lemon shaped swelling was seen over medial aspect of right mid arm, with erythema over and around swelling, no vessels were seen above or around the swelling, the swelling was not pulsatile (Fig. 1). On palpation swelling was 4 ×4×1cm, tender, with raised temperature, firm in consistency with well defined margins, with no enlarged axillary group of lymph nodes. No bruit was heard over the swelling. No other swelling was seen or palpable. Systemic examination is normal.

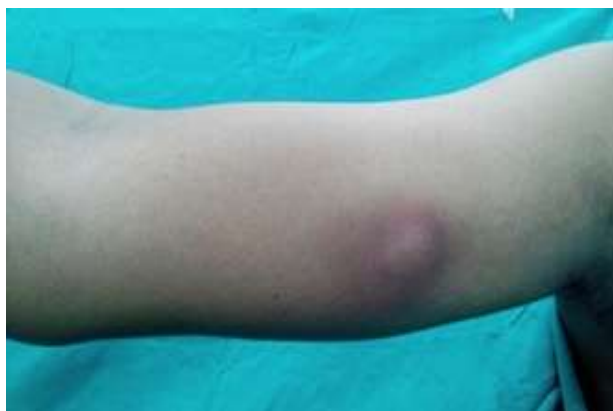USG of swelling revealed - an intramuscular area of altered echoes predominantly hypoechoic, measuring 2.3 x 1.1 x 2.5 cm (CC X AP X Trans) with calcifications within, the largest calcified foci measuring 5.2 mm seen in mid arm in medial compartment. The lesion had extension deep upto the humerus however no cortical irregularity was seen. A 8 X 6 X 7 mm solid hypoechoic lesion on superomedial aspect of the main lesion with multiple tiny calcific foci was seen. On Doppler, it showed no vascularity, the lesion was associated with extensive subcutaneous edema over it, adjacent muscle showed increased

echoes & diffuse thickening of muscle fibers with extensive subcutaneous edema. Bony shadow and vascular contour in the axilla was normal. Findings were confirmed using MRI (plain+contrast) which revealed mildly hyperintense lesion on T1 and STIR images. 02.0 mm sized punctate gradient blooming seen in the medial fibres of triceps muscle suggestive of calcification (Fig. 2 & 3)

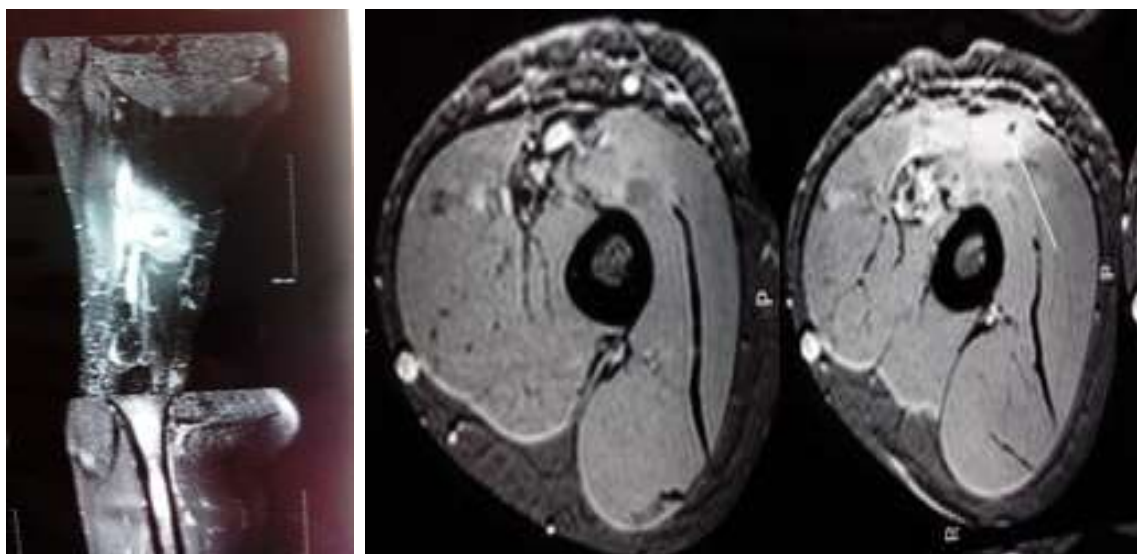
Markedly enhancing phlegmonous tissue measuring 40.2 x 22.0 x 44.1 mm in size, 5.8 x 15.6 x

19.1 mm size peripherally enhancing fluid signal collection is seen within the phlegmonous tissue around the calcification (Fig. 2 & 3).

Patient was advised surgical excision which he declined. Patient was treated with Albendazole 400mg daily for 4 weeks and showed marked reduction in size of swelling and reduction of symptoms. The swelling totally disappeared after 2 months with only overlying hyper-pigmentation left.



**Fig. 1: Diffuse small lemon shaped swelling was seen over medial aspect of right mid arm**



**Fig. 2 & 3: Diagnostic imaging**

## DISCUSSION

The clinical presentation of cysticercosis depends on the anatomical location of the cysts and the extent of associated inflammatory response [5, 8]. It may manifest as neuro, ocular, muscular and subcutaneous cysticercosis [5].

Neurocysticercosis is most common. It commonly manifest as headache and acute seizures. Others include hydrocephalous, focal neurological deficit, chronic meningitis, dementia or spinal cyst [5, 7, 8]. Ocular cysticercosis manifests as proptosis, diplopia, vision loss or slow growing tumour/ nodule

with focal inflammation [5]. The ocular cysts are commonly vitreous and may be found in subretinal locations [7]. In muscular cysticercosis the distinct clinical manifestations include myalgia, pseudotumour, abscess and pseudohypertrophy [5, 8]. Cysts may cause spasms, weakness, pain [7]. Muscular cysticercosis is a rare entity [6, 7].

The degeneration of the cyst leads to the intermittent leakage of the fluid that elicits a chronic inflammatory response due to the collection of fluid around the cyst. It results in formation of a mass or

pseudotumour. The resulting acute inflammation causes myalgia and local pain [5, 8].

Cysticercal cyst can be detected sonographically [9, 10]. Laboratory diagnostic studies play an important role. Different tests can be used including stool examination, serological tests like Enzyme-linked Immunosorbent Assay (ELISA), Enzyme-linked Immuno electrotransfer Blot (EITB) indirect etc. [5, 8].

The treatment of cysticercosis depends upon the site and symptoms of patient. In case of isolated cystic disease surgical excision produces cure, for disseminated disease treatment with anti-helmenthics for several weeks is recommended.

The role of anti-helmenthics in treatment of cysticercosis has been supported [5, 8, 11]. Our patient was given Tab. Albendazole as he declined surgery and responded well without showing any side-effects.

### CONCLUSION

Muscular cysticercosis should always be kept in mind as a differential diagnosis of small lump within muscle presenting with pain and fever especially in the tropics. The diagnosis of cysticercosis can be suspected with USG and MRI (plain+contrast) of the muscle. Surgery and medical treatment option are available and should be recommended depending on the merit of individual case. However, treatment with Albendazole gives good results.

### REFERENCES

1. WHO; Taeniasis/cysticercosis. Fact sheet N°376. Available from <http://www.who.int/mediacentre/factsheets/fs376/en/>
2. Tolan RW Jr.; Taenia Infection. Available from <http://emedicine.medscape.com/article/999727-overview>
3. Jubelt B; parasitic infections. In Rowland LP, Pedley TA editors; Merritt's Neurology. Lippincott Williams & Wilkins, 2010: 228.
4. Taenia solium. Availavle from [http://en.wikipedia.org/wiki/Taenia\\_solium](http://en.wikipedia.org/wiki/Taenia_solium)
5. Bangal V, Tayade S, Kwatra A; Rare case of cysticercosis of rectus abdominis muscle presenting as pelvi - abdominal lump during puerperium. Pravara Med Rev., 2010; 2(2): 21-24.
6. Singal R, Mittal A, Gupta S, Gupta R, Sahu P, Gupta A; Intramuscular cysticercosis diagnosed on ultrasonography in thigh: A rare case report. N Am J Med Sci., 2010; 2(3): 162-164.
7. Yaqoob N, Haq E, Thomali K, Ali K, Ali Z; Cysticercosis of soft tissue. J Pak Med Assoc., 2009; 59(2): 108-110.
8. Shive ME, Jayanthi K; Primary sonographic diagnosis of subcutaneous cysticercosis. Journal of Indian Academy of Oral Medicine and Radiology, 2011; 23(3): 241-244.
9. Mani NB, Kalra N, Jain M, Sidhu R; Sonographic diagnosis of a solitary intramuscular cysticercal cyst. J Clin Ultrasound., 2001; 29(8): 472-475.
10. Vijayaraghavan SB; Sonographic appearances in cysticercosis. J Ultrasound Med., 2004; 23(3): 423-427.
11. Garg RK; Drug treatment of neurocysticercosis. Natl Med J India, 1997; 10(4):173-177.