

Research Article**Comparative Analysis of Mandibular Cortical Index in Orthopantomogram and Bone Mineral Density in Dual Energy X-Ray Absorptiometry in Postmenopausal Females –A Radiological Study in North Indian Population****Dr. Anshul Aggarwal^{*1}, Dr. Rati Goyal², Dr. Juhi Gupta³, Dr. Kauser J Khwaja⁴**^{1,3}Assistant Professor, ⁴Associate Professor & Chairman, Department of Oral Pathology /Oral Medicine and Radiology, Dr ZA Dental College, Aligarh Muslim University, Aligarh, 202002²General Practitioner, Department of Oral Pathology /Oral Medicine and Radiology, Dr ZA Dental College, Aligarh Muslim University, Aligarh, 202002***Corresponding author**

Dr. Anshul Aggarwal,

Email: doctorsahab_00@yahoo.com

Abstract: The Purpose of current study is that Osteoporosis is a systemic disorder characterized by low bone mass leading to fractures reported commonly in females after menopause. The investigations for osteoporosis most commonly used DEXA are very costly and not easily available. Few studies have proposed the use of orthopantomogram as a diagnostic marker for osteoporosis as it is simple, quick, easy, inexpensive, non-invasive and widely used. Thus the present study has undertaken to assess the relation between mandibular cortical index (MCI) of panoramic radiograph and bone mineral density of body measured by dual energy x-ray absorptiometry (DEXA). The study comprised of fifty post-menopausal females. All the females were subjected to panoramic radiographs and DEXA. The visual analysis was done based on the radiographic appearance of the lower border of the mandible on the left side by two observers who were blinded about DEXA results. Intra/Inter-observer variability was ruled out by visual analysis at two occasions which was followed by comparison of different grades of MCI and BMD statistically. There was significant difference in the three groups of mandibular cortical index of panoramic radiograph as interpreted by the two observers (p value < 0.05). The intra-observer reproducibility of this index had moderate agreement (Kappa value of 0.34& 0.31) and the inter-observer agreement of this index followed fair reproducibility (kappa value of 0.37&0.32). This study concluded that there is a significant correlation between mandibular cortical index (MCI) and bone mineral density (BMD) of the lumbar vertebrae as determined by the dual energy x-ray absorptiometry(DEXA). So, visual examination of the panoramic radiographs can be used as a screening procedure for diagnosis and referral of patients for further evaluation of osteoporosis.

Keywords: Osteoporosis, mandibular cortical index, dual energy x-ray absorptiometry(DEXA).

INTRODUCTION

The importance of prevention and early diagnosis is not only in conditions which are incurable but also in conditions which are difficult to treat once they progress. One such condition is osteoporosis. Osteoporosis is defined as a systemic disease of the bone that is characterized by reduced bone mass and disrupted bone tissue microstructure, which leads to increased bone fragility and fracture risk [1].

The diagnosis of osteoporosis is based on the physical signs and symptoms, x-rays, bone scans and bone mineral density (BMD) assessment. The gold standard for determining osteoporosis is DEXA (Dual Energy X-ray Absorptiometry [2] but high cost and unavailability of this equipment at many diagnostic centers limits its usefulness for screening examination.

Panoramic radiograph is widely used for dental examination to detect and scrutinize dental diseases and conditions as it is very cost effective as compared to the other advanced imaging modalities. The use of these radiographs for assessing individuals with low skeletal bone mineral density would be very economical and beneficial as the dentists can refer the patient for further examination if required. Till date no studies have been carried out in this field in postmenopausal females of North India.

MATERIALS AND METHODS

Female subjects with in age group of 45-75 years reporting to the Dental Department of HIDS, Pantnagar, India whose post-menopausal status of at least one year was confirmed by detailed history were included in this study. Patients were subjected to digital panoramic radiographic examination followed by

DEXA for estimation of bone mineral density of the lumbar vertebrae (L2- L4). The lumbar spine was taken for comparison with panoramic radiograph as the spine and femur is considered as the gold standard for diagnosis of osteoporosis.

All the radiographs were analyzed by using the criteria proposed by Klemetti et al[3] by two separate observers who were blinded about the dual energy x-ray absorptiometry results. The analysis was repeated by both the observers after one month. The visual analysis was done by radiographic appearance of the lower border of the mandible near the mental foramen of the left side in panoramic radiographs which is based on MCI. The MCI at lower border of mandible in panoramic radiograph is basically a three point index (C1-3) and was assessed using the following criteria.

- C1: the endosteal margin of the cortex was even and sharp on both sides (Fig I)
- C2: the endosteal margin showed semilunar defects (lacunar resorption) or seemed to form endosteal cortical residues (one to three layers) on one or both sides.(Fig II)
- C3: the cortical layer formed heavy endosteal cortical residues and was clearly porous.(Fig III)

The results were tabulated and analyzed to assess the relation between the MCI of panoramic radiograph and the bone mineral density obtained from DEXA of L2 to L4 region (Fig-4). Intraobserver and interobserver agreement for the classifications in MCI was also calculated

The correlation between the different grades of the MCI of orthopantomograph and bone mineral density obtained from DEXA was compared. Spearman's Rank Correlation coefficient was used to find the association between the different grades of MCI and BMD. The intra-observer and inter-observer reproducibility was calculated by using Cohen Kappa Statistics. The interpretation of the Kappa Statistics was based on the guidelines of Landis and Koch.

- Less than 0.00 – poor
- 0.00 to 0.20 – slightly
- 0.21 to 0.40 – fair

RESULT

The present study comprised of fifty post menopausal female subjects. The mean age of the subjects included in this study was 55 years (\pm 5.53

years) with the age range of 45 to 75 years. The present study has assessed the comparison between the bone mineral density obtained by DEXA and the index (mandibular cortical index) of the panoramic radiograph

The T score obtained from DEXA showed that 20 patients had normal BMD, 19 had osteopenia and 11 patients were osteoporotic (Table 1). Bone Mineral Density in each of the three groups according to the panoramic index was calculated and the classification was based on the observation made by two observers who were blinded about DEXA results. Bone mineral density of the subjects in the C3 group was minimum followed by the C2 and C1 groups respectively. Significant difference was observed between the bone mineral densities of the three groups (p value <0.05) as graded by the first observer. BMD according to the second observer showed that there is a progressive decline in the mean BMD values from C1 to C3 groups. It was also observed that there was a significant difference (p value <0.05) in the values of the BMD between the three groups.

The intraobserver reproducibility of MCI as assessed by the first observer and second observer had fair agreement (Kappa value was 0.34 and 0.31, respectively). The inter observer agreement for the visual analysis of the lower border of mandible as seen in the panoramic radiograph in the first and observation showed fair agreement with the Kappa value of 0.37 and 0.32, respectively.

Spearman's Rank correlation coefficient was calculated between the various grades according to the classification of mandibular cortical index and bone mineral density. The value was found to be significantly correlated for both first observer and second observer (p <0.05) (Table 2).

The correlation between different grades of OPG as graded by the first observer and individual T score of the DEXA analysis was also calculated. The kappa value was found to be 0.492 which showed moderate agreement. (Table 3).

The correlation between different grades of OPG as graded by the second observer and individual T score of the DEXA analysis was also calculated. The kappa value was found to be 0.544 which showed moderate agreement. (Table 4).

Table-1: Bone Mineral Density by DEXA

DEXA Diagnosis	n	BMD	SD	Range
Normal	20	1.179	0.218	0.783-1.487
Osteopenia	19	.971	0.017	0.989-1.074
Osteoporosis	11	.762	0.079	0.814-0.974

Table-2: Spearman’s rank Correlation coefficient between Mandibular cortical index and BMD

	1 st observer		2 nd observer	
	Spearman's correlation coefficient	Probability	Spearman's correlation coefficient	Probability
1 st observation	-0.467	p <0.05	-0.312	p <0.05
2 nd observation	-0.423	p <0.05	-0.157	p <0.05

Table-3: Co-relation between OPG Index of 1st observer and T- Score of DEXA

OPG Grades	DEXA Diagnosis			
	Normal	Osteopenia	Osteoporosis	Total
C1	13	2	0	15
C2	7	12	4	23
C3	0	3	9	12

Table-4: Co-relation between OPG Index of 2nd observer and T- Score of DEXA

OPG Grades	DEXA Diagnosis			
	Normal	Osteopenia	Osteoporosis	Total
C1	14	4	0	18
C2	6	11	3	20
C3	0	2	10	12

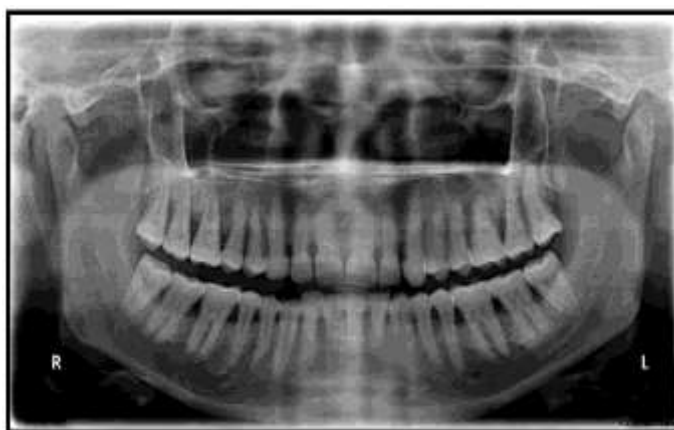


Fig-1: OPG showing normal mandibular cortex (C1)

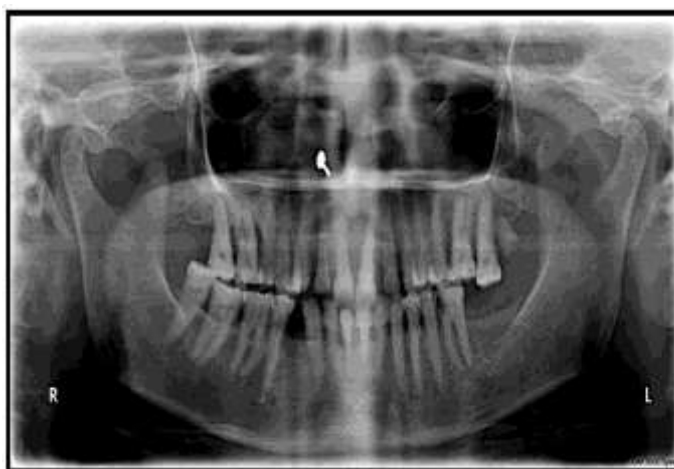


Fig-2: OPG showing mildly eroded mandibular cortex (C2)

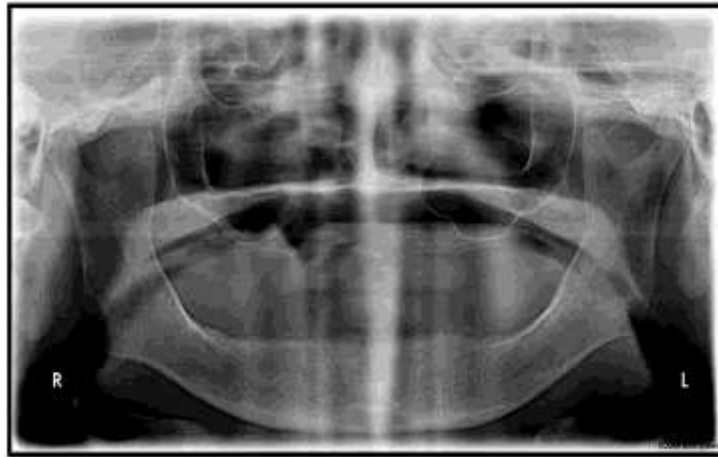

Fig-3: OPG showing severely eroded mandibular cortex (C3)

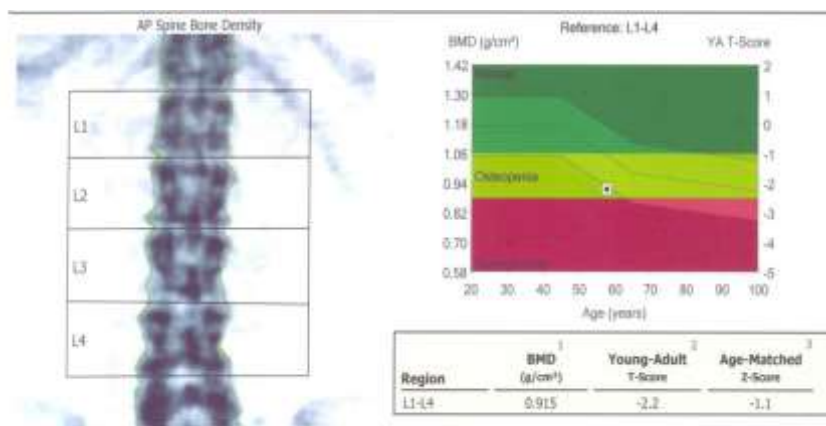


Fig-4: DEXA analysis showing t score with BMD

DISCUSSION

Osteoporosis is defined as a systemic skeletal disorder characterized by low bone mass and microarchitectural deterioration of the bone scaffold that results in increased bone fragility and susceptibility to fracture¹. Calcium is essential for proper functioning of the heart, brain, and other organs. To keep those critical organs functioning, the body reabsorbs calcium that is stored in the bones to maintain blood calcium levels. If calcium intake is not sufficient or if the body does not absorb enough calcium from the diet, bone production and bone tissue may suffer. Early screening and diagnosis of osteoporosis can save many lives [4].

Panoramic radiograph is widely used for dental examination as it is easily available and cost effective as compared to the other advanced imaging modalities. Indices using panoramic radiographs have been proposed as an indicator of the bone mineral density [5,6]. These indices can be of two types - radiomorphometric indices and densitometric indices. Radiomorphometric index is based on the morphological or visual analysis of the panoramic radiograph [7,8]. Densitometric analysis involves quantitative measurements and analysis. Klemetti et al had proposed a radiomorphometric index based on the visual appearance of the lower border of mandible. This

was called as Mandibular cortical index (MCI). The present study evaluated the relation between this index and the bone mineral density of the lumbar spine.

Fifty post-menopausal females were included in this study with the age range of 45-75 years. There is a high risk of osteoporosis associated with the post menopausal females because of which the present study was done on female subjects whose post-menopausal status of at least one year as confirmed by detailed history [9,10]. In the present study 40% patients had normal bone mineral density and the rest 60% of patients had reduced bone mineral density (Table I). This is consistent with other studies that also showed the irrefutable evidence of higher incidence of osteoporosis associated with elderly patients [11].

Inter-observer agreement was also calculated in the present study. The inter-observer agreement in the first observation was found to be 0.38 and in the second observation was found to be 0.32. Both the observations showed fair agreement. Another study done by Lee et al. to assess the relation between mandibular cortex on OPG and BMD reported intraobserver agreement to be almost perfect (Kappa score .89, .92) for the first and second for the second, it was substantial (.77) [12].

Variation in the inter-observer agreement between the present study and the above mentioned study can be attributed to the small sample size used in the present study. In the present study values between the various groups according to the classification of mandibular cortical index and bone mineral density showed significant correlation for the first observer & second observer (p value <0.05).

In the present study an attempt was made to calculate the correlation between the various groups according to the classification of mandibular cortical index and bone mineral density (Table 2). The value was found to be significantly correlated for the first observer & second observer (p value <0.05). This study also evaluated the individual T scores of the DEXA and the three grades of MCI according to the two observers (Table 3, 4). The kappa correlation showed a score of 0.492 for first observer and a score of 0.544 for the second observer. Both the scores showed moderate agreement according to the Landis and Koch guidelines.

Hence the present study shows that mandibular cortical index i.e. a simple three graded classification of radiographic changes in the lower border of mandible can be used to distinguish normal subjects & subjects with altered bone mineral density. Thus postmenopausal females with significant thinning of mandibular cortex should be referred for further evaluation of osteoporosis by the dentists. Therefore visual estimation of the panoramic radiograph can be used as a screening procedure for diagnosis and referral of patients for further evaluation of osteoporosis

CONCLUSION

Osteoporosis is a systemic disorder that also affects the jaw bones. Panoramic radiograph is a simple, quick, easy, inexpensive, non-invasive and widely used yet a sensitive diagnostic tool that has been proposed as a diagnostic marker for the systemic changes of osteoporosis. Hence this study was undertaken to assess efficacy of panoramic radiographic index as a diagnostic marker for osteoporosis.

The present study comprised of fifty post menopausal female subjects who were selected from the outpatient Dental Department of HIDS, PONTA SHAHB. All the patients were subjected to panoramic radiographic examination and DEXA. The panoramic radiographic interpretation was done by two observers who were blinded about DEXA results.

This study concluded that there is a significant correlation between mandibular cortical index (MCI) and bone mineral density (BMD) of the lumbar vertebrae as determined by the dual energy x-ray absorptiometry (DEXA). So, visual examination of the panoramic radiographs can be used as a screening procedure for diagnosis and referral of patients for further evaluation of osteoporosis. The intra-observer

reproducibility of this index has moderate agreement and the inter-observer agreement of this index follows fair reproducibility. Hence all the dental professional should be trained to interpret radiographs accurately as assessment of lower border of mandible is a key for early diagnosis of osteoporosis which is a burning issue today. However, further studies should be carried out in larger population to substantiate the results.

REFERENCE

1. White SC; Oral Radiographic predictors of osteoporosis. *Dentomaxillofac Radiol*, 2002; 31(2): 84-92.
2. Horner K, Devlin H; The relationship between two indices of mandibular bone quality and bone mineral density measured by dual energy x-ray absorptiometry. *Dentomaxillofac radiol*, 1998; 27(1): 17-21.
3. Klemetti E, Kolmakov S, Kroger H; Pantomography in assessment of the osteoporosis risk group. *Scand J Dent Res*, 1994; 102(1): 68-72.
4. Raisz LG; Pathogenesis of osteoporosis: concepts, conflicts, and prospects. *The Jour Clin Inves*. 2005; 115(12): 3318-3325.
5. Andre F, Paulo T, Claudia M, Nilse S, Ana P; Correlation between seven panoramic radiomorphometric indices and bone mineral density in postmenopausal women. *Oral Surg Oral Pathol Oral Radiol Oral Endod*, 2010; 109(3): 449-456.
6. Cakur B, Dagistan S, Şahin A, Harorli A, Yilmaz AB; Reliability of mandibular cortical index and mandibular bone mineral density in the detection of osteoporotic women. *Dentomaxillofac Radiol*, 2009; 38: 255-261.
7. Ishii K, Taguchi A, Nakamoto T, Ohtsuka M, Sutthiprapaporn P, Tsuda M, Tanimoto K; Diagnostic efficacy of alveolar bone loss of the mandible for identifying postmenopausal women with femoral osteoporosis. *Dentomaxillofac Radiol*, 2007; 36: 28-33.
8. Dutra V, Yang J, Devlin H, Susin C; Radiomorphometric indices and their relation to gender, age and dental status. *Oral Surg Oral Pathol Oral Radiol Oral Endod*, 2005; 99(4): 479-484.
9. Nagler RM, Herschkovich O; Relationships between age, drugs, oral sensorial complaints and salivary profile. *Arch Oral Biol*, 2005; 50(1): 7-16.
10. Hildebolt CF; Osteoporosis and oral bone loss. *Dentomaxillofac Radiol*, 1997; 26(1): 3-15.
11. Taguchi A, Tanimoto K, Sueti Y, Wada T; Oral signs as indicators of possible osteoporosis in elderly women. *Oral Surg Oral Pathol Oral Radiol Oral Endod*, 1995; 79(1): 127-132.
12. Lee K, Taguchi A, Ishii K, Sueti Y, Fujita M, Nakamoto T, White SC; Visual assessment of the mandibular cortex on panoramic radiographs to identify postmenopausal women with low bone mineral densities. *Oral Surg Oral Med Oral Pathol Oral Radiol Endod*, 2005; 100(2): 226-231.