

**Research Article****Conjunctival pyogenic granuloma after strabismus surgery****Shinji Makino, Kozue Hozawa, Reiko Kondo, Mika Kanai, Haruko Suto, Go Mawatari, Kanako Ito**

Department of Ophthalmology, Jichi Medical University, Shimotsuke, Tochigi, Japan

**\*Corresponding author**

Shinji Makino,

Email: [makichan@jichi.ac.jp](mailto:makichan@jichi.ac.jp)

---

**Abstract:** The Purpose of current study to evaluate the incidence and treatment of conjunctival pyogenic granuloma after strabismus surgery. We retrospectively studied 512 consecutive patients who underwent strabismus surgery from 2004 through 2013. Pyogenic granuloma developed in 2 of 512 patients (0.39%). In one patient, who presented with pyogenic granuloma on the exposed sclera located at the original insertion of the lateral rectus muscle, topical corticosteroid was successful. The other patient, who did not respond to topical corticosteroids, underwent surgical excision of the granuloma. However, the mass recurred at the same site. The size of the mass decreased markedly following topical application of vasoconstrictive drops. Our study results suggest that appropriate conjunctival closure may help prevent pyogenic granuloma and vasoconstrictive drops might be effective in the treatment of this condition..**Keywords:** Conjunctival pyogenic granuloma; Strabismus surgery; Incidence

---

**INTRODUCTION**

Conjunctival pyogenic granuloma is a potential complication of strabismus surgery [1- 4]. However, there are few reports about the incidence and management of pyogenic granuloma after strabismus surgery [1, 3, 4]. In 2005, Espinoza and Lueder [4] reported that conjunctival pyogenic granuloma developed in 2.1% of patients after strabismus surgery. Here, we report the incidence and treatment results of conjunctival pyogenic granuloma after strabismus surgery.

**MATERIALS AND METHODS**

We retrospectively evaluated 512 consecutive patients who underwent strabismus surgery from 2004 through 2013. Patient age ranged from 11 to 85 years (average,  $34.2 \pm 20.5$  years). The initial diagnoses were esotropia (n = 136), exotropia (n = 300), hypertropia (n = 44), paralytic strabismus (n = 22), torsional strabismus (n = 8), and other conditions (n = 2). All surgeries were performed on an outpatient basis, and local anesthesia was used. One of the authors (SM) operated on all cases. All cases underwent a limbal incision. All muscles were reattached to the globe using 6-0 polyglactin suture material, and the conjunctiva was

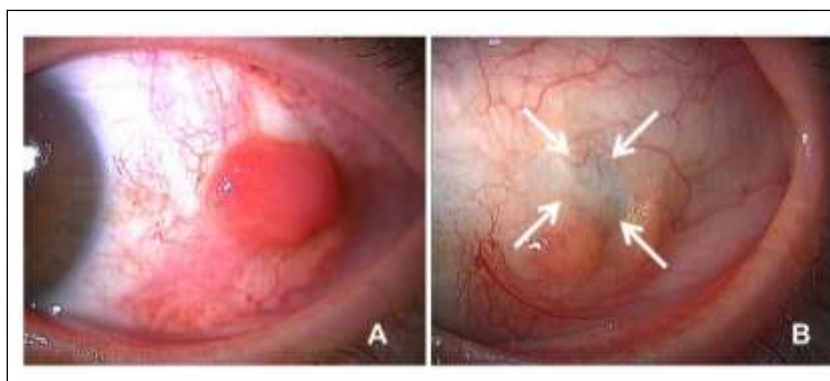
closed using 4-0 silk suture material. All cases received topical corticosteroid and antibiotic drops postoperatively. The initial types of operative procedures were as follows: muscle recession (Rec; n = 268), muscle resection (Res; n = 32), Rec + Res (n = 195), muscle transposition (n = 14), and other (n = 3).

**RESULTS**

The overall incidence of pyogenic granuloma was 0.39% per patient (2/512). Pyogenic granuloma occurred in the following two cases.

**Case 1** (reported previously [5])

A 48-year-old man presented with exotropia of the left eye. The alternate prism cover test (APCT) revealed an exotropia of 60 prism diopters (PD). A 9-mm lateral rectus muscle recession and a 7-mm medial rectus muscle resection were performed in the left eye. Approximately 1 month later, a smooth red polypoid mass appeared in the area overlying the original insertion of the lateral rectus muscle (Figure 1A). One month after administration of topical corticosteroid drops, the mass had completely resolved (Figure 1B). At 2 years, the mass had not recurred.

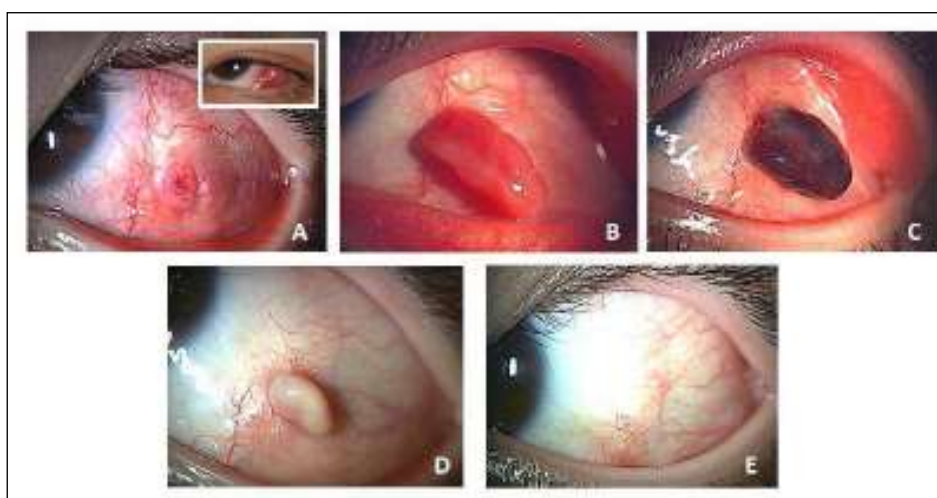


**Fig-1: Case 1: The smooth red polypoid mass in the area overlying the original insertion of the lateral rectus muscle (A). After 1 month of topical corticosteroid treatment, the mass has completely resolved (B). Arrows indicate exposed sclera.**

### Case 2

An 11-year-old boy presented with exotropia of the left eye. The APCT revealed an exotropia of 40 PD. A 9-mm lateral rectus muscle recession and a 7-mm medial rectus muscle resection were performed in the left eye. Approximately 1 month later, a smooth red polypoid mass appeared in the area overlying the original insertion of the lateral rectus muscle (Figure 2, inset A). Although topical corticosteroid drops were administered, the mass increased in size. Surgical

excision was performed using cautery (Figure 2A); however, at 1 month postoperatively, the mass had recurred at the same site (Figure 2B). Three weeks later, the mass became hemorrhagic (Figure 2C). The size of the mass decreased markedly after topical application of vasoconstrictive drops (naphazoline nitrate; Figure 2D) for 2 weeks, and complete resolution was achieved 1 month later (Figure 2E). At 6 months, the mass had not recurred.



**Fig-2: Case 2: The smooth red polypoid mass in the area overlying the original insertion of the lateral rectus muscle (inset A). The site of the mass after surgical excision had been performed (A). At one month postoperatively, the mass has recurred at the same site (B). Three weeks later, the mass has become hemorrhagic (C). After 2 weeks of topical application of vasoconstrictive drops, the size of the mass has decreased markedly (D). One month later, complete resolution has been achieved (E).**

### DISCUSSION

Espinoza and Lueder [4] reported that conjunctival pyogenic granuloma developed in 2.1% of patients (10/472) after strabismus surgery. In our study, the overall incidence of pyogenic granuloma was 0.39% per patient (2/512).

Elkington [1] described that granulomas were seen over resected muscles but not over those that had been recessed. In addition, according to Espinoza and

Lueder [4], the majority of cases underwent a conjunctival incision 8 mm from the limbus. Although our Case 1 underwent a limbal incision, en bloc recession involving Tenon's capsule and the lateral rectus muscle was required because of the large amount of recession. Therefore, the sclera remained exposed at the end of surgery. We speculate that pyogenic granuloma might have developed from the exposed sclera (Figure 1B, arrows). Although corticosteroids diminished the size of the pyogenic granuloma, we

consider that appropriate conjunctival closure should be recommended to prevent pyogenic granuloma.

A pyogenic granuloma is a vasoproliferative inflammatory response composed of granulation tissue [6, 7]. Capillaries are a predominant component of wound healing and pyogenic granulomas. The growth and development of new capillaries follows an orderly sequence of events that is highly regulated by a variety of angiogenic factors [7]. Jordan *et al.* [7] postulated an imbalance in angiogenesis regulation as the common pathway for pyogenic granuloma development. According to their theory, as an example, the presence of exposed sclera, such as in Case 1, delays wound repair. As a result, additional inflammatory cells are recruited to the area, which release various wound-repair mediators in an attempt to enhance the repair process. An imbalance of mediators disrupts the normal tissue-healing cascade. If this response is not inhibited or modulated, vascular development extends through the wound, forming a pyogenic granuloma.

Ferry [3] reported that only 3% of pyogenic granulomas recurred after simple excision. Similarly, recurrent conjunctival pyogenic granuloma after strabismus surgery is extremely rare. When the pyogenic granuloma is removed by simple excision, the above wound-repair cascade is initiated again [7], which may result in redevelopment of pyogenic granuloma. On the basis of the abovementioned imbalance in angiogenesis, we speculated that vasoconstrictive drops might be effective in Case 2.

Generally, conservative management with topical corticosteroid is successful, and surgical excision is effective in patients who do not improve with topical medication [4].

#### CONCLUSION

We consider that appropriate conjunctival closure should be recommended to prevent pyogenic granuloma and that vasoconstrictive drops might be effective in the treatment of this condition.

#### REFERENCES

1. Elkington A; Granulomas following squint surgery. *Trans Ophthalmol Soc U K*, 1971; 91: 543–552.
2. Gal A, France TD; Granuloma formation as a complication of the posterior fixation suture operation. *Arch Ophthalmol*, 1986; 104(12): 1755.
3. Ferry AP; Pyogenic granulomas of the eye and ocular adnexa: a study of 100 cases. *Trans Am Ophthalmol Soc*; 1989; 87: 327–347.
4. Espinoza GM, Lueder GT; Conjunctival pyogenic granulomas after strabismus surgery. *Ophthalmology*, 2005; 112(7): 1283–1286.
5. Makino S, Hozawa K; Conjunctival pyogenic granuloma after strabismus surgery. *Imaging J Clin Med Sciences*, 2014; 1(2): 109.
6. Al-Towerki AA; Pyogenic granuloma. *Int Ophthalmol*, 1996; 19(5): 287–291.
7. Jordan DR, Brownstein S, Lee-Wing M, Ashenhurst M; Pyogenic granuloma following oculoplastic procedures: an imbalance in angiogenesis regulation? *Can J Ophthalmol*, 2001; 36(5): 260–268.