

Research Article

Cystic Fluid–Pathway to Enlighten the Early Diagnosis of Keratocystic Odontogenic Tumor

Dr. Humaira Nazir¹*, Dr. Suhail Lattoo²

¹Post Graduate Student in Department Of Oral and Maxillofacial Pathology, Sree Siddhartha Dental College & Hospital, Tumkur.

²Asstt.Prof in Department of Oral and Maxillofacial Pathology, Govt. Dental College& Hospital, Srinagar

***Corresponding author**

Dr. Humaira Nazir

Email: humairanazir15@gmail.com

Abstract: To evaluate and compare the levels of albumin, prealbumin, total protein, in the cystic fluid for the diagnosis and appropriate treatment planning of keratocystic odontogenic tumours and other non keratinizing odontogenic cysts. Twenty keratocystic odontogenic tumour and twenty controls were studied. The cystic fluid was aspirated and analyzed to determine the levels of albumin, prealbumin, total protein,. The data collected was statistically evaluated using Mann Whitney U-Test and Student's t-test. In results Comparison of prealbumin, total protein, was made between keratocystic odontogenic tumour and non keratinizing odontogenic cysts and was found having highly significant difference ($p < 0.0001$). The presence of albumin also showed a significant difference ($p < 0.01$). In conclusion an analysis of total protein, albumin, prealbumin, may be used as a diagnostic addition in the preoperative diagnosis of keratocystic odontogenic tumour in a minimally invasive and highly accurate manner.

Keywords: keratocystic odontogenic tumor, dentigerous cyst, radicular cyst, albumin, prealbumin and protein levels

INTRODUCTION

The term 'odontogenic keratocyst' was introduced by Philipsen in 1956. It has a bimodal age of occurrence, first peak in second decade and the second peak in fifth decade Odontogenic keratocyst (Keratocystic odontogenic tumor) is a clinico pathologically distinct form of odontogenic cyst, known for its pathognomic microscopic features, aggressiveness and high recurrence rate and tendency to invade adjacent tissues. Odontogenic Keratocysts classically exhibit several characteristic histologic features; a uniform thickness of epithelial lining composed of 6-10 cell layers with a well polarized basal cell layer and a para keratinized luminal surface that is usually corrugated.1 Supra basal cells frequently show intracellular edema and often an abrupt transition between them and the surface layer of parakeratin [1, 2].

This lesion is now categorized as an odontogenic tumor according to the latest WHO recommendations because the increased proliferative and mitotic activity of the epithelial cells is greater than that of odontogenic jaw cysts [2]. Conservative methods of treatment such as enucleation and marsupialization consistently have produced less than optimal results in OKC compared to that of non keratinizing odontogenic cysts (KNOC) like dentigerous cyst and radicular cyst.

Hence various surgical modalities were advised for an attempt to improve the recurrence rate like curettage, peripheral ostectomy, and osseous reconstruction with or without continuity defect [3].

Preoperative diagnosis of OKC improves the treatment outcome in formulating an appropriate treatment plan and adequately counseling the patients.3.Studies have reported significant differences between the concentration of total protein, prealbumin and albumin levels in cystic fluid of OKCs and other forms of odontogenic cysts [4,5].

Hence the study was undertaken to compare the albumin, prealbumin and total protein in keratinized and non keratinized odontogenic cysts for early diagnosis of keratinized odontogenic cyst.

MATERIALS AND METHOD

20 cases of KCOT and 20 controls of KNOC like 10 DC and 10 RC were studied. The cystic fluid was aspirated from the most prominent and fluctuant part of the swelling through an intact mucosa. 1.5 ml of the fluid was used for the estimation of albumin; prealbumin, total protein .The remaining cystic fluid was placed for centrifugation at 1500rpm for 10 min. Following centrifugation, the cells which appeared at the base of the centrifuge tube was carefully removed

using a pipette and was rapidly smeared. Three smears were prepared and were stained with Haematoxyline & Eosin stain (H&E), Papanicolaou (PAP) stain and May Grunweld Giemsa stain (MGG). Determination of total protein was done using direct Biuret method. Qualitative estimation of prealbumin and albumin was done by using Sodium Dodecyl Sulphate Poly acryl amide Gel Electrophoresis and visualization of the prealbumin and albumin bands was made under standardized conditions of the intensity of Coomassie Brilliant Blue staining in trans-illuminated light on a scale: (-) no band, (+) faint band, (++) . The data collected was statistically evaluated using Mann Whitney U-Test and Student's t-test.

RESULTS

Twenty cases of KCOT and twenty controls of KNOC were studied. The KNOC comprise of 7

Dentigerous Cyst and 12 Radicular Cyst. Albumin band was observed in all cases as well as controls Out of 20 cases, 09 cases exhibited – a moderate band, 06 cases – a strong band and 05 cases – a very strong albumin band. Out of 20 controls, 12 controls exhibited – a faint band, 4 controls – a moderate band and 4 controls – a strong albumin band [Table1/graph-a]. The prealbumin band was present in all the cases where as it was absent in controls. Out of 20 cases, 8 cases exhibited a faint band, 06 cases – a moderate band, 03 cases – a strong band and 06 cases – a very strong prealbumin band [Table2/graph-b]. A comparison of total protein between cases and controls showed highly significant difference. The total protein content in the cases ranged from 2.35 to 5.75gm/dl and the total protein content in the controls ranged from 5.87 to 10.92 gm/ dl.

Table 1: Albumin Bands

	NO BAND	MODERATE	STRONG	VERY STRONG	FAINT
20 CASES OF KCOT	-	09	06	05	-
20 CONTROLS OF KNOC	-	04	04	-	12

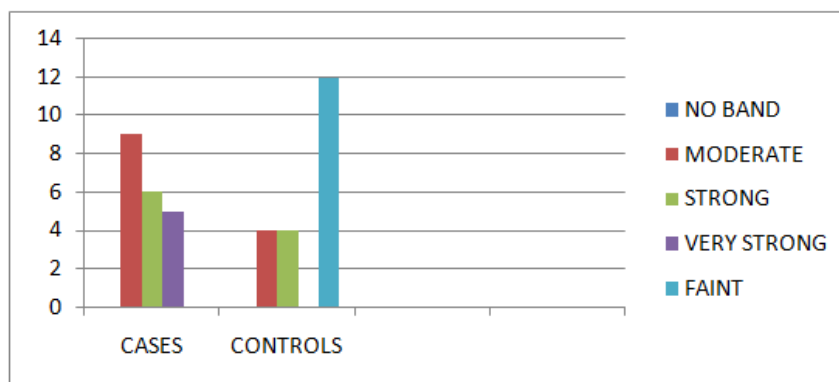


Fig (A): Showing Comparison of Albumin Bands between KCOT and KNOC

Table 2: Pre albumin Bands

	NO BAND	MODERATE	STRONG	VERY STRONG	FAINT
20 CASES OF KCOT	00	06	03	03	08
20 CONTROLS OF KNOC	00	00	00	00	00

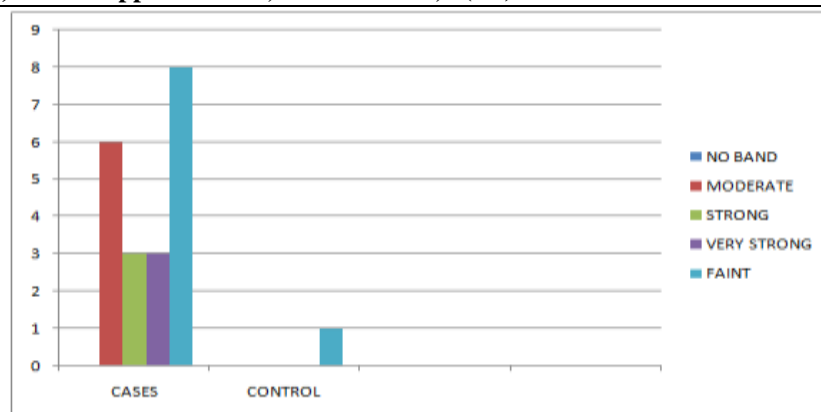


Fig (B): Showing Comparison of Pre albumin Bands in KCOT and KNOC

Table 3: Showing Protein Content

	PROTEIN CONTENT
20 CASES OF KCOT	2.35 -5.75gm/dl
20 CONTROLS OF KNOC	5.87-10.92gm/dl

DISCUSSION

In the present study an evaluation of various parameters in the fluids of KCOT in comparison to other KNOCs showed remarkable differences. The difference in the composition of the cystic fluid of KCOTs, RC and DC. And DC supported the view that the pathogenesis of these lesions is different [11]. Levels of Albumin, prealbumin, total protein in KCOT were compared with those of NKOCs. A significant difference ($p < 0.01$) was seen when a comparison of albumin was made between KCOT and NKOCs [Table1/Fig-a]. Electrophoresis showed the presence of an albumin band in cystic aspirates from both the study and control groups. When compared to the control group, the study group showed higher albumin levels and within the control group, DCs contained more amount of albumin than RCs. Shear found that RCs contain lower levels of albumin and higher levels of β and γ globulin. The presence of inflammatory changes in the cyst wall and abundant inflammatory cells in cyst fluid make it likely that the proteins are derived as inflammatory exudates [6]. Toller concluded that the fluid of OKC composed of predominately albumin with relatively small quantities of immunoglobulins [7]. The wall of OKC is characteristically free from signs of inflammation and thus the formation of inflammatory exudates and local synthesis of immunoglobulins would be expected to be low [7, 8]. Even if these did occur to any extent, the continuous layer of keratinized epithelium lining the cysts forms a less readily penetrable barrier than the frequently discontinuous, non-keratinized epithelium lining RCs and DCs, and thus lower levels of proteins would accumulate in the cystic fluid [9]. In another study by Southgate *et al.*, cystic fluid from OKCs was analyzed and they concluded that the major protein fraction with mobility anodal to albumin on electrophoresis was shown not to be albumin or prealbumin but a non-serum protein 8.

Kramer and Toller reported on the combined use of epithelial cells and protein estimation of the cystic fluid in the preoperative diagnosis of cysts and also found that examination of the smears achieved comparable diagnostic accuracy to that achieved by use of the protein estimation [8, 9, 10]. Voorsmit reported a diagnostic accuracy of 100% when the combined techniques were used, using a total protein level in the cyst fluid of less than 4.8gm/100ml as an indication that the lesion was an OKC. Hence the present study showed that the decrease total protein, a distinct prealbumin band, increased albumin in the cyst fluid are diagnostic of KCOT and provides helpful values in appropriately planning the treatment of KCOT and other odontogenic cysts thus providing a relatively non-invasive technique preceding to surgery.

CONCLUSION

Hence it was concluded that a preoperative diagnosis of KCOT might be made by aspirating the cystic fluid and estimate the levels of albumin, prealbumin and protein level.

REFERENCES

1. Browne RM; The odontogenic keratocyst. Brit Dent J, 1970; 3(2): 252-238.
2. Shear M; Developmental odontogenic cysts. An update. J Oral Pathol Med, 1994; 23: 1-11.
3. Brannon RB; The odontogenic keratocyst. A clinico pathological study of 312 [3] cases. Part I. Clinical features. Oral Surg Oral Med Oral Path Oral Radiol Endod, 1976; 42(1):54-72.
4. Leon Barnes, John W. Eveson, Peter Reichart, David Sidransky; Pathology and [4] Genetics of Head and Neck Tumours, IARC Press Lyon, 2005; 306-307.

5. Stoelting PJ; Long-term follow-up on keratocysts treated according to a defined protocol. *Int J Oral Maxillofacial Surg*, 2001; 30: 14–25.
6. Toller PA; Permeability of cyst walls in vivo: Investigations with radioactive tracers. *Proceedings of the Royal Society of Medicine*, 1966; 59(8):724-29.
7. Smith AJ, Smith G, Browne RM; Analysis of odontogenic cyst fluid aspirates. *IRCS Med Sci*, 1986; 14: 304.
8. Mervyn Shear, Paul Speight; *Cysts of the Oral and Maxillofacial Regions*, 4[19] Th Edition, Blackwell Munksgaard, 2007; 6-58.
9. Douglas CWI, Craig GT; Recognition of protein apparently specific to odontogenic keratocyst fluids. *Journal of Clinical Pathology*, 1986; 39(10): 1108-15.
10. Shear M; The aggressive nature of the odontogenic keratocyst: is it a benign cystic neoplasm? Part III. Immuno cyto chemistry of cytokeratin and other epithelial cell markers. *Oral Oncol*, 2002; 38: 407–415.
11. Browne RM; The pathogenesis of odontogenic cystic fluids. *Journal of Oral Pathology and medicine*, 1976; 5(2): 74-87.