

## Original Research Article

**Clinicopathological correlation of Hansen's disease – A study of 75 cases**Kallol Banerjee<sup>1</sup>, S. Srikanth<sup>2</sup><sup>1</sup>Consultant Pathologist, Kalitala Diagnostics, Burdwan<sup>2</sup>Associate Professor, Department of Pathology, Prathima Institute of Medical Sciences, Karimnagar, Telangana, India.**\*Corresponding author**

Dr Kallol Banerjee

Email: [kallolbanerjee@rediff.com](mailto:kallolbanerjee@rediff.com)

**Abstract:** Leprosy (Hansen's disease) is a chronic disease caused by *Mycobacterium leprae* (*M.leprae*). It is infectious in some cases and affects peripheral nerves, skin and certain other organs (muscles, eyes, bones, testis, and internal organs). It is considered as a disease of global importance. The objective of this study is to review the morphology of 75 diagnosed cases of Hansen's disease. Seventy five clinically diagnosed cases of leprosy having macular and plaque lesions from the department of Dermatology, from January 2005 to July 2007 were studied. Skin biopsy specimens from the lesions were taken from all the patients under local anaesthesia. Out of 75 clinically diagnosed cases there was no histological evidence of Hansen's disease in 5 cases (possibly biopsies taken from non-representative sites) and 70 cases were proved histopathologically as Hansen's disease. Precise assessment of the status of leprosy both clinical and histopathological examination should be carried out apart from bacteriological examination.

**Keywords:** Hansen's, tuberculoid, lepromatous, histiod.

**INTRODUCTION**

India accounts for one third of the total leprosy patients in the world and it is a major health and social problem because of its chronic course, permanent disabilities and social stigmata. Leprosy manifests itself in different forms like lepromatous, tuberculoid, borderline, indeterminate and pure neurotic forms depending upon the host immune response to infections. Various types of lesions occur in leprosy like macular, plaque and nodular lesions. The exact diagnosis of the type of leprosy according to Ridley – Jopling classification is based on clinical, histopathological, bacteriological and immunological findings [1].

Leprosy has a wide distribution in the world and is most prevalent in the tropics and subtropics but less common in temperate regions. Most of the cases occur in South East Asia, Africa and western pacific. In Northern Europe, Japan and USA there have been progressive 'natural declines' in the incidence of leprosy.

**MATERIALS & METHODS**

Skin biopsy specimens from the lesions were taken from all the patients under local anaesthesia. Biopsies were small elliptical pieces of skin extending down to the subcutaneous tissue, measuring 0.5 to 1 cm x 0.4 to 0.6 cm in size. They were fixed in 10%

formalin and processed routinely. Then 5 um sections were taken and stained with Haematoxylin & Eosin and Fite Faraco stain. All the slides were examined under light microscope and analysis were carried out with respect to clinical features and histopathological findings in all cases according to Ridley-Jopling classification.

**RESULTS**

Out of 75 Clinically diagnosed cases there was no histological evidence of Hansen's disease in 5 cases and 70 cases were proved histopathologically as Hansen's disease.(Figure 1) The present study was carried out on those 70 histopathologically proved cases of Hansen's disease who presented with different types of skin lesions.

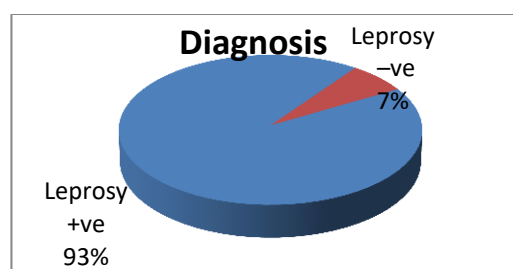


Fig 1: Showing final diagnosis

Table 1 shows the age distribution of all 70 cases. It is seen in all age group starting from 1<sup>st</sup> decade to 8<sup>th</sup> decade of life. Maximum cases i.e., 30 cases (42.8%) were seen among the age of 21-30 years (3<sup>rd</sup> decade).

**Table 1: Age distribution of cases**

Age	Number of cases	Percentage
10-20	10	14.3
21-30	30	42.8
50-60	20	28.5
70-80	10	14.3

Among these 70 positive cases 56 cases (80%) were male and 14 cases (20%) were female (Table 2).

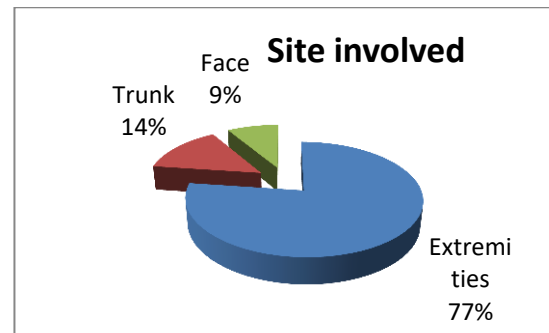
**Table 2: Sex distribution**

Sex	Number of cases	Percentage
Male	56	80
Female	14	20
Total	70	100

The most common site (54 cases or 77.24%) of these lesions was the extremities, other sites were trunk (10 cases or 14.3%) and face (6 cases or 8.5%). [Table 3, Figure 2]

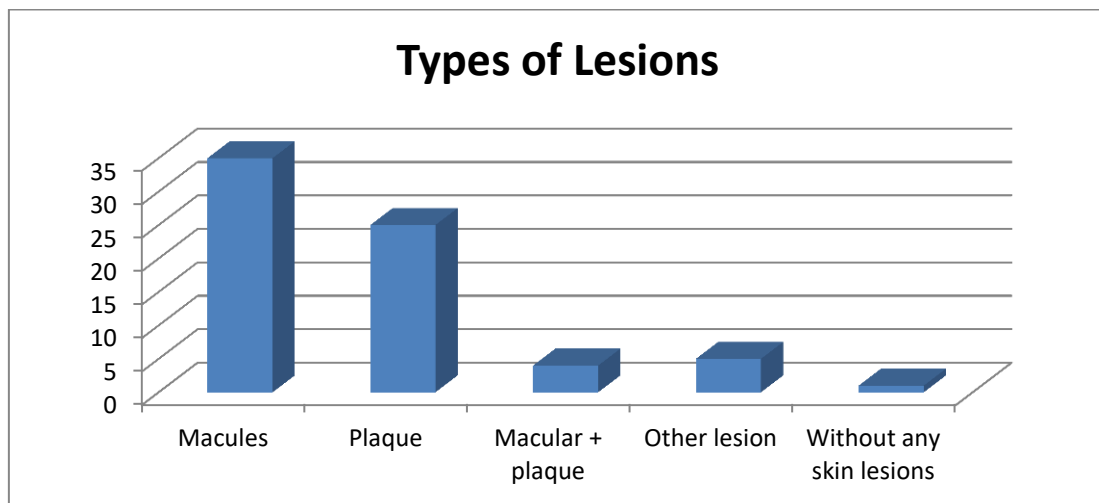
**Table 3: Showing site involvement**

Site	Number of cases	Percentage
Extremities	54	77.24
Trunk	10	14.3
Face	6	8.5



**Fig 2: Site involvement**

Of these 70 positive cases 35 (50%) cases were having macular lesions and 25 (35.7%) cases having plaque or elevated lesions, 4 (5.7%) cases having both macular and plaque lesions, 5 (7.2%) cases having other lesions, 1 (1.4%) case without any skin lesion (pure neural leprosy) [Figure 3].

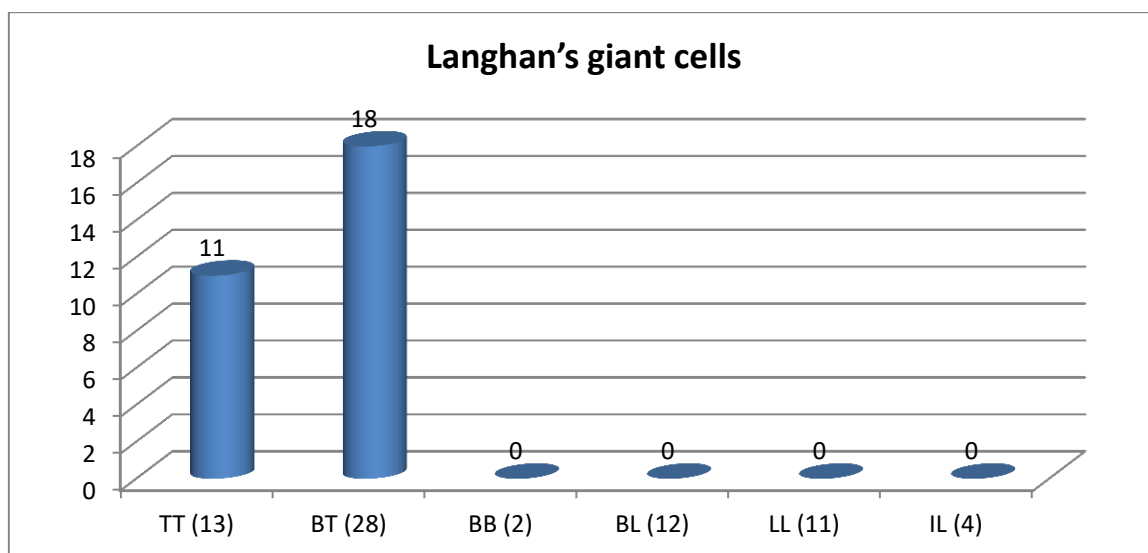


**Fig 3: Type of lesion involved**

**Histopathological findings (Positive cases)  
Subepithelial clear zone**

Sub epidermal clear zone: no sub epidermal clear zone was seen in cases of TT, BT, IL and BB, whereas 8 cases out of 12 cases (66.6%) of BL and 10

cases out of 11 cases (90.9%) of LL showed sub epidermal zone. 11 cases out of 13 cases (84.6%) of TT and 18 cases out of 28 cases (64.2%) of BT showing Langjan’s giant cells (LGC). Not seen in cases of BL, LL, BL, BB and IL. [Figure 3].



**Fig-4: Showing percentage of LGC**

One case out of 11 cases (9%) of LL, 2 cases out of 13 cases (15.3%) of TT, 1 case out of 28 cases (3.5%) of BT, 1 case out of 4 cases (25%) IL show nerve thickening. No evidence of nerve thickening in cases of BL and BB. [Table 4]

**Table 4: Showing nerve thickening**

Types	Nerve thickening	Percentage
TT (13)	2	15.3
BT (28)	1	3.5
BB (2)	0	0
BL (12)	0	0
LL (11)	1	9
IL (4)	1	25

Type I reaction was seen in 1 case out of 11 cases (90.9%) of LL, and Type II reaction was seen in 4 cases out of 11 cases (36.3%) of LL. Among these cases Fite Faraco stain was positive in 4 IL cases out of 4 (100%), 3 BT cases out of 28 (10.7), 11 BL cases out of 12 (91.6%), 11 LL cases out of 11 (100%) [Table 5].

**Table 5: Showing Fite Faraco staining**

Types	Fite faraco staining	Percentage
TT (13)	0	0
BT (28)	3	10.7
BB (2)	0	0
BL (12)	11	91.6
LL (11)	11	100
IL (4)	4	100

By clinical examination, these 75 cases were classified as TT in 13, BT in 31, BL in 13, LL in 11, IL in 4 and BB in 3 cases [Table 6].

**Table 6: Showing clinically diagnosed cases**

Type	No of cases	Percentage
TT	13	17.3
BT	31	41.3
BB	3	4.0
BL	13	17.3
LL	11	14.6
IL	4	5.3

Histopathologically among them there were 13 cases of TT, 28 cases of BT, 12 cases of BL, 11 cases of LL, 4 cases of IL, 2 cases of BB and 5 cases without any evidence of leprosy.[Table 7]

**Table 7: Showing HP diagnosed cases**

Type	No of cases	Percentage
TT	13	17.3
BT	28	3.3
BB	2	2.6
BL	12	16.0
LL	11	14.6
IL	4	5.3
Negative cases	5	6.6

**Table 8: Showing correlation between clinical and histopathology**

Clinical Type	No. of cases	Histopathological type						Negative cases	% of parity
		TT	BT	BB	BL	LL	IL		
TT	13	13	-	-	-	-	-	-	100%
BT	31	-	28	-	-	-	-	3	90.32%
BB	3	-	-	2	-	-	-	1	66.66%
BL	13	-	-	-	12	-	-	1	92.30%
LL	11	-	-	-	-	11	-	-	100%
IL	4	-	-	-	-	-	4	-	100%
<b>Total</b>	<b>75</b>	<b>13</b>	<b>28</b>	<b>2</b>	<b>12</b>	<b>11</b>	<b>4</b>	<b>5</b>	<b>93.33%</b>

Excluding 5 negative cases correlation between pathological and clinical diagnosis was good. Correlation is highly significant with p value of 0.

## DISCUSSION

Leprosy is a slowly progressive infection that mainly affects the skin and peripheral nerves. Despite its low communicability, leprosy remains endemic among people living in several developing tropical nations. The source of infection and route of transmission are not known, however human respiratory secretions or soil are likely origins. *M. leprae* is taken up by macrophages and disseminates in the blood, but it replicates primarily in relatively cool tissues of the skin and extremities.

It proliferates best at 32° to 34°C, the temperature of the human skin. Cell mediated immunity is manifested by delayed type hypersensitivity reactions to dermal injections of a bacterial extract called lepromin. In the present study, the histopathological features of 70 cases (excluding 5 cases clinically diagnosed as Leprosy but on histopathologically showing no evidence of leprosy) were consistent with the clinical features in 60 cases (85.7%). Disparity was noted in 14.3% of cases. B Niranjana Moorthy *et al.*[7]; 1999 in a study of correlation of the clinicopathological features of leprosy found correlation in 233 cases (62.63%) out of 372 cases. Disparity was noted in 37.3% of cases.

In present study, out of 13 clinically diagnosed cases of BL there were 12 cases proved histologically as BL (parity was 92.3%) and 1 case showed no evidence of leprosy. Shanker NP *et al*[7].; in 2001 study showed out of 15 clinically diagnosed cases of BL 12 cases proved histologically as BL (parity was 93.3%), 3cases as BB. Kar PK *et al.*; study showed out of 13 clinically diagnosed cases of BL there was 7 cases proved histologically as BL (parity was 53.8%), 4cases as BT, 1 case as BB and 1 case as LL. In this study all the 11 clinically diagnosed cases of LL were confirmed histopathologically as LL. So the parity was 100%.

In leprosy the histopathological features indicate the accurate response of the tissues while the clinical features indicate only the gross morphology of the lesions which is due to underlying pathological change. Since there is a variable tissue response in the disease spectrum due to variability of CMI, it is logical to expect some disparity between clinical and histopathological features while studying various types of leprosy, irrespective of the nature of lesions whether macular or plaque.

So to achieve a correct diagnosis of the spectrum of leprosy histopathological examination should be done along with clinical examination and bacteriological examination.

Clinically lesions were numerous, small, ill defined, symmetrically distributed, hypo pigmented, smooth and shining and without sensory loss. Skin smear were positive for bacilli in all cases. On histopathological examination, there was clear sub epidermal zone and in the dermis there was diffuse granuloma composed of foamy macrophages and few lymphocytes. Nerves were clearly recognized. Acid fast bacilli were seen throughout the section by Fite Faraco stain.

## CONCLUSION

The present study was done to demonstrate the correlation between clinical diagnosis and histopathological diagnosis of leprosy. Tuberculoid leprosy, Lepromatous leprosy and indeterminate leprosy showed good (100%) parity between clinical and histopathological diagnosis. Amongst the borderline leprosy marked disparity was observed.

In Indeterminate leprosy clinical assessment was proved more important in early diagnosis as its histopathological changes were nonspecific. Diagnostic value of Fite Faraco stain was also proved in this study particularly for borderline lepromatous, lepromatous and indeterminate leprosy.

**REFERENCES**

1. K. Park. Park's Textbook of Preventive and Social Medicine – 20<sup>th</sup> Ed. Jabalpur, India: Banarsidas Bhanot Publishers; 2009: 276.
2. WHO Tech .Rep.Ser.No; 1988, 768.
3. Britton WJ, Lockwood. DNJ. Leprosy. Lancet 2004; 363: 1209-1219.
4. Dhople AM. Search for newer anti-leprosy drugs. Ind J Lepr 2000; 72(1): 5-19.
5. El-Darouti MA, Hussein S, Marzouk SA, Nabil N, Hunter NS, Mahgoub D, El-Eishi NH, Abdel-Halim MR. Histopathological study of apparently normal skin of patients with leprosy. International journal of dermatology. 2006 Mar 1; 45(3):292-6.
6. Jena S, Swain JP, Mishra S. Fnc study of histoid nodule: an early tool for diagnosis. Indian journal of leprosy. 2004 Dec; 77(2):135-9.
7. Nair SP, Moorthy KP, Suprakasan S, Jayapalan S, Mini G. Histoid leprosy–unusual presentation. International journal of dermatology. 2006 Apr 1; 45(4):433-4.
8. Girdhar BK. Skin to skin transmission of leprosy. Indian Journal of Dermatology, Venereology, and Leprology. 2005 Jul 1; 71(4):223.
9. Suneetha S, Sigamoni A, Kurian N, Chacko CJ. The development of cutaneous lesions during follow-up of patients with primary neuritic leprosy. International journal of dermatology. 2005 Mar 1; 44(3):224-9.
10. Lever's. Histopathology of the Skin 19thEd. Philadelphia: David Ed. Elder; 2005: 574-576.
11. Majumdar S.et all. Clinicopathological disparity in leprosy. Int J Lepr 2003; 69: 178-179.