

Original Research Article

## A Clinical, Etiological and Histopathological Study of Acquired Facial Melanosis

Shah AN<sup>1</sup>, Patel D<sup>2</sup>, Kasundara V<sup>3</sup>, Shah K<sup>4</sup>

<sup>1</sup>Assistant Professor, <sup>2</sup>4<sup>TH</sup> Year Resident, <sup>3</sup>3<sup>RD</sup> Year Resident, <sup>4</sup>2<sup>ND</sup> Year Resident, V. S. General hospital, Ahmedabad, Gujarat, India

### \*Corresponding author

Dr Aarti N. Shah

Email: [skhushali88@yahoo.in](mailto:skhushali88@yahoo.in)

**Abstract:** Acquired facial melanosis is a common presentation in Indian patients, causing cosmetic disfigurement with considerable psychosocial impact. This study was conducted to correlate the clinical, etiological and histopathological features of disease process. Total 25 patients presenting with acquired facial melanosis were included in the study. Detailed history, clinical examination, wood's lamp examination and dermatoscopy were carried out and clinical diagnosis was made. A 4 mm punch biopsy from the lesion for the histopathological examination was taken. Key histopathological features on hematoxylin and eosin stain were assessed. 12 patients belonged to age group of 20-29 years. 18 patients were female. 11 (44%) patients were on oral medications and 08 (32%) patients had history of topical application of creams. (80%), 23 (92%) patients had bilateral lesions. Accentuation of lesions on Wood's lamp examination was present in 07 (28%) patients and there was no accentuation in 18 (72%) patients. Dermatoscopy examination showed reticular pigmentation in 08 patients (32%) followed by reticular pigmentation with follicular sparing in 05 patients (20%). Clinical and Histopathological diagnosis was concordant in 23 (92%) patients while discordant in 02 (08%) patients. Melasma was the most common cause followed by PIH, Exogenous ochronosis, Riehl's melanosis, Lichen planus pigmentosus (LPP), Acanthosis nigricans(AN) and Acquired Nevus of Ota. Although reliable diagnosis can be made clinically in cases of acquired facial melanosis, histopathology is a useful tool and must be carried out where diagnosis is in doubt clinically for proper management and better prognosis.

**Keywords:** Acquired facial melanosis, Dermatoscopy, Exogenous ochronosis, LPP, AN.

### INTRODUCTION

Acquired facial melanosis is a common presentation in Indian patients, causing cosmetic disfigurement with considerable psychological impact. Most of the acquired facial melanosis are commoner in darker races with both light and photosensitizing chemicals (occupational/cosmetics) playing an important role. Some of the well-defined causes of facial melanosis include Melasma, Riehl's melanosis, Lichen planus pigmentosus, Erythema dyschromicum perstans (EDP), Erythromelanosis follicularis faciei et colli, Exogenous ochronosis, Poikiloderma of civatte, Acquired Nevus of Ota, Acanthosis nigricans, Post inflammatory hyperpigmentation, Drug induced facial hyperpigmentation, Addison's disease, Phototoxic dermatitis and Periorbital hyperpigmentation. These cases are frequently encountered in dermatology outpatients department. But there is considerable overlap in features amongst the clinical entities. Etiology in most of the cases is unknown, but some factors such as ultraviolet radiation in melasma,

exposure to chemicals in EDP, exposure to allergens in Riehl's melanosis are implicated [1].

Unlike most internal illnesses, skin diseases especially those on face are often immediately visible to others and, therefore, may lead to significant psychosocial consequences, and consequent dermatological consultations, thus explaining the growing importance of these disorders [2-4].

Diagnosis is generally based on clinical features and helped by wood's lamp examination, Dermatoscopy, skin biopsy. There are hardly any studies correlating the clinical, etiological and histopathological features of acquired facial melanosis and the present study is taken up to fill that lacuna.

### MATERIAL AND METHODS

The study was conducted in outpatient Department of Dermatology, Venereology & Leprology of a tertiary care hospital. It was started after taking due permission from the Institutional Review Board.

Total 25 patients presenting with acquired facial melanosis were included in the study. Written consent of all patients was taken and confidentiality of all the data and photographs were maintained.

Detailed history and clinical examination including wood's lamp examination and dermatoscopy were carried out in each patient. Clinical diagnosis was made.

In all patients, a 4 mm punch biopsy from the lesion for the histopathological examination was taken. The biopsy was performed under local anaesthesia using 2% lignocaine with all aseptic precautions.

The specimens were fixed in 10% neutral buffered formalin for at least 24 hours to ensure ideal fixation.

Key histopathological features on hematoxylin and eosin stain were assessed in all the cases.

#### **INCLUSION CRITERIA**

- Patients with the acquired facial melanosis above 18 years of age

#### **EXCLUSION CRITERIA**

- Any active skin infection at local site like
  - Herpes Simplex in active phase
  - Bacterial infection
  - Fungal infection
- Bleeding abnormalities/ Patient on anticoagulant therapy
- Patients with unrealistic expectations
- Patients not giving consent for the study/biopsy
- Patients having congenital facial melanosis
- Pregnant and lactating females

#### **RESULTS AND DISCUSSION**

The present cross sectional descriptive study was conducted for a period of one and half year from June 2014 to November 2015 revealed the following results.

Among 25 patients 8 patients belonged to age group of 20-29 years (32%) followed by 7 patients in age groups of 30-39 years and 40-49 years (28% each). 18 patients were female (72%).

12 patients were having disease duration of 00 - 01 years (48 %) followed by 11 patients > 01 - 03 years (44 %). One patient had disease since 10 years.

21 (84%) patients were married while 04 (16%) were unmarried.

13 (52%) patients were having progressive lesions while 12 (48%) patients were having non progressive lesions.

02 (08%) patients were having positive family history.

Out of 25 patients, 08 (32%) patients had associated diseases. Among them 04 (16%) patients had hypertension while diabetes mellitus and hypothyroidism were present in 02 (08%) patients each.

11 (44%) patients were on oral medications for various reasons and 08 (32%) patients had history of topical application of creams which contained Modified Kligman's formula (Hydroquinone 2%/4% + Tretinoin 0.025 / 0.05% + Mometasone furoate 0.1%/ Fluocinolone acetonide 0.01%). Topical hydroquinone and topical steroids were used by 06 (24%) and 03 (12%) patients respectively.

Amongst 25 patients, 06 (24%) patients had acne followed by 02 (08%) patients who had eczema. Photosensitivity was associated with 12 (48%) patients.

Maximum number of patients (80%) i.e 20 out of 25 had multiple patches and only 01(04%) patient had single patch.

23 (92%) had bilateral lesions out of which 16 (64%) patients had symmetrical lesions while 07 (28%) patients had asymmetrical lesions. Only 02 (08%) patients had unilateral asymmetrical lesions.

The most common site of involvement was reported as both malar regions in 10 (40%) patients followed by forehead and both malar regions in 08 (32%) patients. Entire face was involved in 04 (16%) patients while only forehead was involved in 03 (12%) patients.

Involvement of other body areas was present in 03 (12%) patients. There was involvement of axilla and neck in 02 patients and involvement of back in 01 patient.

Pruritus was present in 06 (24%) patients. Pruritus was most common among the patients having PIH. Xerosis was present in 03 (12%) patients. Xerosis was found in patients of Melasma, LPP, Riehl's melanosis.

In the present study amongst 25 cases of acquired facial melanosis, accentuation of lesions on Wood's lamp examination was present in 07 (28%) patients suggesting epidermal pigmentation while there

was no accentuation of lesions in 18 (72%) patients suggesting dermal pigmentation.

Dermatoscopy examination showed reticular pigmentation in maximum 08 patients (32%) followed by reticular pigmentation with follicular sparing in 05 patients (20%). Pseudo reticular pigmentation and brown globules were seen in 03 patients each (12%) while pseudo network and accentuated pigment was seen in 02 patients each (08%). Blue grey amorphous areas and black arciform structures were seen in 01 patient (04%) each.

Among the melasma patients (N=12) characteristic histological findings included epidermal thinning, increased melanin as well as melanocytes in all the layers of epidermis, increased melanocytes and melanophages in dermis, mild lymphohistiocytic infiltrate and solar elastosis (figure 1)

Characteristic histological findings in exogenous ochronosis patients (N=03) included hyperkeratosis, pigment incontinence, Banana shaped fibres in papillary dermis, mild histiocytic infiltrate and solar elastosis. [Table 3] (Figure 2)

Characteristic histological findings among the PIH patients (N=03) included normal epidermis, increase in epidermal melanin and melanocytes, pigment incontinence and mild lymphocytic infiltrate. [Table 3]

Characteristic histological findings in the Riehl's melanosis patients (N=02) included normal or thinned epidermis, basal layer degeneration, increased melanophages in dermis and lymphohistiocytic infiltrate. [Table 3] (Figure 3)

Among the LPP patients (N=02) characteristic histological findings included thinning of epidermis, basal layer degeneration, few melanophages in dermis, pigment incontinence and solar elastosis. [Table 3] (Figure 4)

Among the Acanthosis nigricans patients (N=02) characteristic histological findings included hypertrophic epidermis, pigment incontinence, interface changes, lymphocytic infiltrate. [Table 3]

Characteristic histological findings in Acquired Nevus of Ota (N=01) included normal epidermis, increased melanin deposits in dermis, increase in both dermal melanocytes and melanophages. [Table 3]

Clinical and Histopathological diagnosis was concordant in 23 (92%) patients while discordant in 02 (08%) patients.

Acquired facial Melanoses are a group of heterogeneous entities, sharing a common clinical feature of altered pigmentation of the face. An accurate diagnosis is achieved through a careful clinical and histopathology evaluation.

In the present study, Melasma was reported as the most common cause of acquired facial melanosis consisting of 12 (48%) cases. This was higher than that reported by Hassan *et al.* [8] (35%). According to our study among Melasma patients mean age was 40.25 years while it was 34.22 years by Hassan *et al.* [8], 33.45 years in the study done by Achar and Rathi [9] and 42.3 years in the study by Goh and Dlova [10]. Among melasma patients 11 (91.66%) patients were female and 01 (8.33%) patient was male. This is less than 15% [8], 19% [9] and 10% [11] involvements of men found in previous studies. Among melasma patients mean duration was 11.6 months.

PIH was found in 03 (12%) of patients which was less than that reported by previous study [8] (16.34%). In our study all the patients were male (100%). Hassan *et al.* [8] also showed male predominance. Mean age was 32.33 years and mean duration was 16.6 months in present study.

Exogenous ochronosis (EO) was found in 03 (12%) cases. Mean age was 36.33 years while mean duration was 26 months.

Riehl's melanoses (RM) was found in 02 (08%) patients. This was more than that (5.7%) reported by Hassan *et al.* [8]. Mean age was 40 years in our study which was similar to 42.4 years reported by Hassan *et al.* [8] and mean duration was 30 months. Study done by Hassan *et al.* reported disease duration of 38 months [8].

In the present study, LPP, a rare variant of lichen planus, was found in 02 (08%) of cases which was more than that reported by previous study [8]. Our study reported equal gender distribution which was similar to Bhutani *et al.* [7] who also showed no difference in gender distribution in their patients. Mean age was 32 years in our study and mean duration was 18 months.

Acanthosis nigricans (AN) was found in 02 (08%) patients with equal gender distribution. Mean age was 38 years and mean duration was 30 months in the present study. Acquired Nevus of Ota was found in 01 (04%) patient with 10 years duration in 28 year old female. [Table 1]

About 66.7% of our patients with Melasma described sun exposure as aggravating factor, similar to study done by Hassan *et al.* [8] and Sanchez *et al.* [12].

Pregnancy and oral contraceptive pills (OCPs) caused aggravation in 36.4% of female patients which is higher as compared to previous studies [12, 13].

Associated hypothyroidism was present in 16% of patients with Melasma which is higher as compared to Hassan *et al.* [8] and study done by Achar and Rathi [9].

About 58.33% of our patients with Melasma had history of association with the application of various cosmetic products and topical steroids, available as over the counter fairness cream which is slight lower as compared to Hassan *et al.* [8]. This association of melasma with cosmetic products has also been reported by Achar and Rathi [9], and Grimes [14]. In our study centrofacial pattern was the most common which was similar to Katsambas *et al.* [6] and Kang *et al.* [5], but in contrast to Hassan *et al.* [8] and Goh and Dlova *et al.* [10], which reported malar pattern to be most common. This can be explained by regional and environmental variations. [Table 2]

Among PIH patients (N=03) 66% had multiple bilateral and 33% had multiple unilateral asymmetrical lesions respectively. There was no accentuation of lesions in any patient of PIH on wood's lamp examination. Pruritus was present in 66% of patients with PIH. [Table 2]

33% of patients had multiple bilateral lesions while 66% had lesions involving entire face among Exogenous ochronosis (EO) patients (N=03). There was no accentuation of lesions in any patient of EO on wood's lamp examination suggesting dermal pigmentation. History of application of topical hydroquinone was present in 100% of cases with EO. Pruritus was present in 33% while photosensitivity was present in 66% of patients. [Table 2]

In the present study both LPP patients (N= 02) had multiple bilateral lesions. There was no accentuation of lesions in any patient of LPP on wood's lamp examination suggesting dermal pigmentation. Although lesions are generally asymptomatic mild

pruritus was present in 50% of patients. In the study done by Hassan *et al.* [8] pruritus was present in 48% of patients which is similar to our study. In earlier reported series, pruritus was present in 50% to 62% of the patients [7, 15]. Forehead and malar region was the predominant site involved in our study while Hassan *et al.* [8] reported forehead and temples as predominant sites involved in LPP. Bhutani *et al.* and Vega *et al.* also noted similar findings in their patients [7, 15]. [Table 2]

Both RM patients (N= 02) had diffuse bilateral and asymmetrical lesions. There was no accentuation of lesions in any patient of RM on wood's lamp examination suggesting dermal pigmentation. In our study lesions in both patients involved entire face sparing eyes and nose while study by Hassan *et al.* [8] showed that lesions were more pronounced over forehead, temporal, and cheeks. [Table 2]

All the acanthosis nigricans patients (N= 02) had multiple bilateral symmetrical lesions involving both malar areas and periorbital region. There was no accentuation of lesions in any patient of AN on wood's lamp examination suggesting dermal pigmentation. Both of them had involvement of other body areas also. [Table 2]

There was one case of Acquired Nevus of Ota in female patient who had single lesion on the left side of forehead since 10 years. Our patient had onset of lesion in second decade of life which is comparable to study by Sekar *et al.* [16] who also reported that 26% of patients of Acquired Nevus of Ota had onset of their lesion in second decade. [Table 2]

Although reliable diagnosis can be made clinically in cases of Acquired facial melanosis, histopathology is a useful tool and must be carried out where diagnosis is in doubt clinically for proper management and better prognosis. This improves both, diagnostic ability and the chances of detecting cases early in the stage, thus increasing the likelihood of a better response to treatment.

**Table-1: Summary of mean age and mean duration among the patients of Acquired Facial Melanosis**

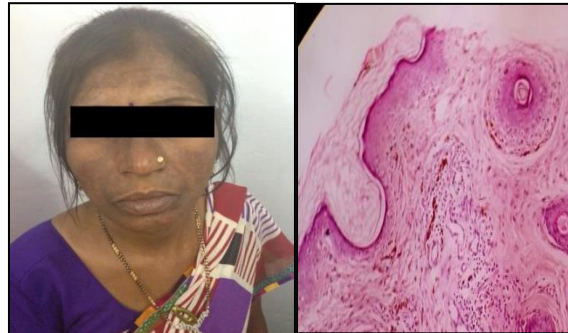
Diagnosis	No. of cases (%)	Gender		Mean Age (Yrs)	Mean Duration (months)
		Female	Male		
Melasma	12 (48)	11	01	40.25	11.6
Exogenous ochronosis	03 (12)	02	01	36.33	26
Riehl's melanosis	02 (08)	02	00	40	30
PIH	03 (12)	00	03	32.33	16.6
Acanthosis nigricans	02 (08)	01	01	38	30
LPP	02 (08)	01	01	32	18
Acquired Nevus of Ota	01 (04)	01	00	28	120

**Table-2: Summary of clinical findings among the patients of Acquired Facial Melanosis**

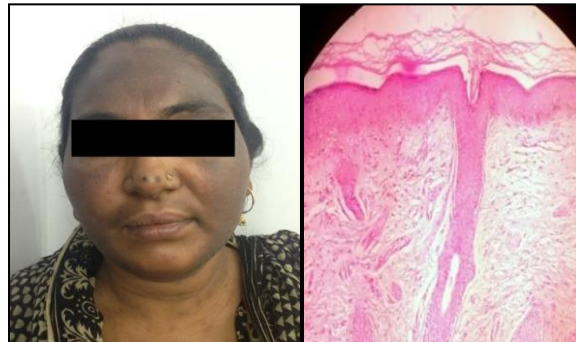Clinical findings		Melasma N=12	EO N=3	RM N=2	PIH N=3	AN N=2	LPP N=2	NOON =1	Total (%)
Gender	Female	11	2	2	0	1	1	1	18 (72)
	Male	1	1	0	3	1	1	0	7 (28)
No. of patches	Multiple	12	1	0	3	2	2	0	20 (80)
	Single	0	0	0	0	0	0	1	1 (4)
	Diffuse	0	2	2	0	0	0	0	4 (16)
Involvement of other body areas		0	0	0	1	2	0	0	3 (12)
Progression		9	1	0	0	0	2	0	12 (48)
Associated Dermatoses		6	2	1	3	1	1	0	14 (56)
Aggravating factors	Sunlight	8	2	0	0	0	2	0	12 (48)
	Pregnancy	4	0	0	0	0	0	0	5 (20)
	OC pills	4	0	0	0	0	0	0	4 (16)
Associated symptoms	Pruritus	2	1	0	2	0	1	0	6 (24)
	Xerosis	1	0	1	0	0	1	0	3 (12)
Symmetry		12	2	0	0	2	0	0	16 (64)
Asymmetry		0	1	2	3	0	2	1	9 (36)
Distribution	Bilateral	12	3	2	2	2	2	0	23 (92)
	Unilateral	0	0	0	1	0	0	1	2 (8)
Wood's Lamp findings	Accentuation	7	0	0	0	0	0	0	7 (28)
	No Accentuation	5	3	2	3	2	2	1	18 (72)
Treatment History	Hydroquinone	2	3	1	0	0	0	0	6 (24)
	Modified Kligman's formula	4	0	1	2	1	0	0	8 (32)
	Topical steroids	1	0	0	0	1	1	0	3 (12)

**Table-3: Summary of Histopathological features of Acquired Facial Melanosis**

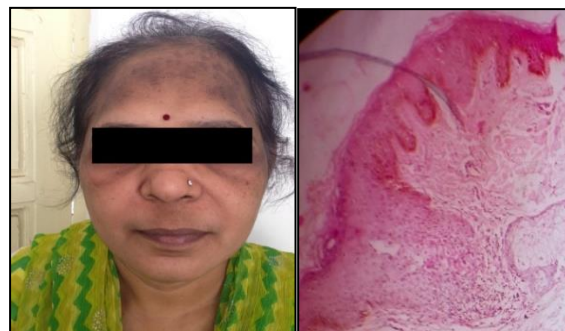Histopathological features		Melasma N=12	EO N=3	RM N=2	PIH N=3	AN N=2	LPP N=2	NOO N=1	Total (%)
Epidermis	Hyperkeratosis	0	2	0	0	0	0	0	2 (8)
	Thinning	3	0	1	0	0	2	0	6 (12)
	Hypertrophic	0	0	0	0	2	0	0	2 (8)
↑ed melanocytes in epidermis		12	0	0	3	0	0	0	15 (60)
↑ed melanin in epidermis		12	0	0	3	0	0	0	15 (60)
Basal layer degeneration		0	0	2	0	0	2	0	4 (16)
Pigment incontinence		0	3	0	3	2	2	0	10 (40)
Banana shaped fibres in papillary dermis		0	3	0	0	0	0	0	3 (12)
Interface changes		0	0	2	0	2	2	0	6 (24)
Melanin in dermis		4	0	0	0	0	0	1	5 (20)
Melanocytes in dermis	Few	6	0	0	0	0	0	0	6 (24)
	Many	6	0	0	0	0	0	1	7 (28)
Melanophages in dermis	Few	5	0	0	0	0	2	0	7 (28)
	Many	7	0	2	0	0	0	1	10 (40)
Type of Infiltrate	LH	7	0	2	0	0	2	0	11 (44)
	LC	2	0	0	3	2	0	0	7 (28)
	LP	0	1	0	0	0	0	0	1 (4)
	HC	0	2	0	0	0	0	0	2 (8)
Solar Elastosis		8	3	0	0	0	2	0	13 (52)



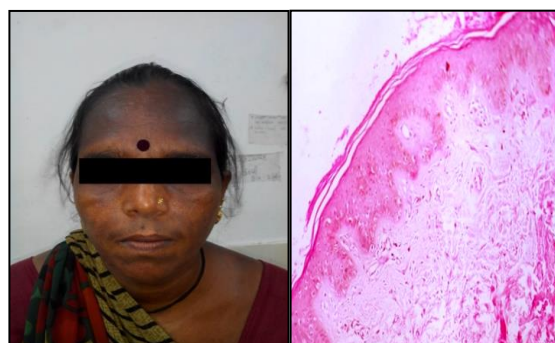**Fig-1: Clinical and Histopathological images showing Melasma**



**Fig-2: Clinical and Histopathological images showing Exogenous ochronosis**



**Fig-3: Clinical and Histopathological images showing Riehl's melanosis**



**Fig-4: Clinical and Histopathological images showing Lichen planus pigmentosus**

## CONCLUSION

Acquired facial Melanoses are a group of heterogeneous entities, sharing a common clinical feature of altered pigmentation of the face and thus easily visible cosmetic disfigurement. Unlike most internal illnesses, skin diseases especially those on face

are often immediately visible to others and, therefore, may lead to significant psychosocial consequences, and consequent dermatological consultations, thus explaining the growing importance of these disorders. An accurate diagnosis is achieved through a careful clinical and histopathology evaluation.

In the present study, Melasma was reported as the most common cause of acquired facial melanosis and is more common among middle aged females.

Among 25 patients maximum number of patients belonged to age group of 20-29 years (32%) followed by age groups of 30-39 years and 40-49 years (28% each). In the present study, maximum numbers of patients were female (72%).

Disease duration of 00 - 01 years was present in maximum number of patients (48%) followed by > 01 - 03 years (44 %). One patient enrolled had disease since 10 years.

In the present study, Clinical and Histopathological diagnosis was concordant in 23 (92%) patients while it was discordant in 02 (08%) patients.

Although reliable diagnosis can be made clinically in cases of Acquired facial melanosis, histopathology is a useful tool and must be carried out where diagnosis is in doubt clinically for proper management and better prognosis. This improves both, diagnostic ability and the chances of detecting cases early in the stage, thus increasing the likelihood of a better response to treatment.

Limitation of this study is the small number of patients. A more detailed Histopathological examination needs to be done with special stains and immunohistochemistry.

## REFERENCES

1. Khanna N, Rasool S. Facial melanoses: Indian perspective. *Indian Journal of Dermatology, Venereology, and Leprology*. 2011 Sep 1;77(5):552.
2. Pichardo R, Vallejos Q, Feldman SR, Schulz MR, Verma A, Quandt SA, Arcury TA. The prevalence of melasma and its association with quality of life in adult male Latino migrant workers. *International journal of dermatology*. 2009 Jan 1;48(1):22-6.
3. Pawaskar MD, Parikh P, Markowski T, Mcmichael AJ, Feldman SR, Balkrishnan R. Melasma and its impact on health-related quality of life in Hispanic women. *Journal of dermatological treatment*. 2007 Jan 1;18(1):5-9.
4. Freitag FM, Cestari TF. What causes dark circles under the eyes?. *Journal of cosmetic dermatology*. 2007 Sep 1;6(3):211-5.
5. Kang WH, Yoon KH, Lee ES, Kim J, Lee KB, Yim H, Sohn S, Im S. Melasma: histopathological characteristics in 56 Korean patients. *British journal of dermatology*. 2002 Feb 1;146(2):228-37.
6. Katsambas A, Antoniou CH. Melasma. Classification and treatment. *Journal of the*

- European Academy of Dermatology and Venereology*. 1995 Jun 1;4(3):217-23.
7. Bhutani LK, Bedi TR, Pandhi RK, Nayak NC. Lichen planus pigmentosus. *Dermatology*. 1974 Jul 1;149(1):43-50.
8. Hassan I, Aleem S, Bhat YJ, Anwar P. A clinico-epidemiological study of facial melanosis. *Pigment International*. 2015 Jan 1;2(1):34.
9. Achar A, Rathi SK. Melasma: a clinico-epidemiological study of 312 cases. *Indian journal of dermatology*. 2011 Jul 1;56(4):380.
10. Goh CL, Dlova CN. A retrospective study on the clinical presentation and treatment outcome of melasma in a tertiary dermatological referral centre in Singapore. *Singapore medical journal*. 1999 Jul;40:455-8.
11. Katsambas A, Lotti T, Dessinioti C, D'Erme AM, editors. *European handbook of dermatological treatments*. Springer; 2015 Apr 28.
12. Sanchez NP, Pathak MA, Sato S, Fitzpatrick TB, Sanchez JL, Mihm MC. Melasma: a clinical, light microscopic, ultrastructural, and immunofluorescence study. *Journal of the American Academy of Dermatology*. 1981 Jun 30;4(6):698-710.
13. Pathak MA. Clinical and therapeutic aspects of melasma: an overview. *Brown Melanoderma*. Fitzpatrick, TB; Wick, MM; Toda, K.(eds). Tokyo, Japan. 1986:161-71.
14. Grimes PE. Melasma: etiologic and therapeutic considerations. *Archives of dermatology*. 1995 Dec 1;131(12):1453-7.
15. Vega ME, Waxtein L, Arenas R, Hojyo MT, Dominguez-Soto LU. Ashy dermatosis and lichen planus pigmentosus: a clinicopathologic study of 31 cases. *International journal of dermatology*. 1992 Feb 1;31(2):90-4.
16. Sekar S, Kuruvila M, Pai HS. Nevus of Ota: a series of 15 cases.