

Original Research Article

Incidence of Methicillin resistance in *Staphylococcus* species and their antibiotic susceptibility pattern, in ocular samples at a tertiary care eye hospital, Hyderabad

Pallati Alekhya¹, C. Aruna sunder², Prathibha³¹PG-3rd MD Microbiology, Osmania medical college, Hyderabad²Professor of Microbiology, Osmania medical college, Sarojini Devi Eye Hospital, Hyderabad³Assistant professor, Osmania medical college, Sarojini Devi Eye Hospital, Hyderabad

*Corresponding author

Pallati Alekhya

Email: chakrambala88@gmail.com

Abstract: The aim of this study is to find the cause of increase in number of cases with methicillin resistance in *Staphylococcus* isolates. A retrospective analysis was done on all *Staphylococcus* isolates which were reported at Sarojini Devi Eye Hospital, Hyderabad from January 2016 to June 2016. Total of 468 samples were tested out of which *Staphylococcus* isolates were 218. Among them, methicillin resistance was seen in 47 (21.5%) of samples. 35 (74.4%) samples were collected on outpatient basis and rest 12 (25.6%) were from inpatient. 36 patients were males and 11 patients were females. 95.74% sensitivity was seen for Moxifloxacin. Methicillin resistance in *Staphylococcus* is becoming increasingly prevalent, and ophthalmologists will see more ophthalmic MRSA infections. Microbiologist must identify Methicillin resistance in *Staphylococcus* isolates, and Ophthalmologists must adjust empirical treatment regimens where Methicillin resistance is endemic, and take steps to control emergence of resistant organisms in both inpatient and outpatient practices.

Keywords: MRSE, ocular, antibiotic susceptibility, MRSA, Cefoxitin.

INTRODUCTION:

Historically, the genus *Staphylococcus* was included with the genus *Micrococcus* in the family Micrococcaceae. There are approximately 39 species and 21 subspecies within the genus *Staphylococcus*. *Staphylococcus* species are gram positive cocci, which are catalase positive, nonmotile and non-spore forming. Several of the coagulase-negative *Staphylococci* (CoNS) species listed may be encountered in clinical specimens[1].

The most common organism in normal and infective eye is *Staphylococcus*[2]. Methicillin-resistant *Staphylococcus aureus* (MRSA) was first reported in 1960, the same year that methicillin was developed, and it is still a bacterium that is frequently detected in hospitals worldwide. In the field of ophthalmology, ocular infections such as dacryocystitis, conjunctivitis and keratitis are often reported. Infectious keratitis and endophthalmitis caused by MRSA are increasing problems throughout the world. In recent years, the number of multidrug-resistant MRSA strains showing resistance to other antibiotics such as

aminoglycosides, minocycline and fluoroquinolones has been on the rise[3]. In addition to being a nosocomial pathogen MRSA has become a community pathogen. Ocular Methicillin resistance *Staphylococcus* infections can be aggressive and cause severe ophthalmic disease including blindness[4]. *Staphylococcus epidermidis* has developed the same bacterial resistance as *S. aureus* and has now been termed as methicillin-resistant *S. epidermidis* (MRSE). Moreover, reports have shown that MRSE can cause ophthalmic infections and blindness[3]. The aim of this study is to see the incidence of Methicillin resistance in *Staphylococcus* isolates in a tertiary care eye hospital and its antibiotic susceptibility from ocular samples.

MATERIAL AND METHODS:

From January 2016 to June 2016, various ocular samples were collected under aseptic conditions. The different samples were conjunctival swab, corneal scraping, AC tap, vitreous tap, etc. The samples were inoculated on Blood agar, MacConkey agar, and Brain Heart infusion agar. *Staphylococcus* isolates were identified by cultural characteristics, gram stain,

catalase, and tube and slide coagulase. Routine antibiotic susceptibility testing was done by Kirby-Bauer disc diffusion method for the following antibiotics disc: Chloromphenicol(30µg), Ceftazidime(30µg), Ciprofloxacin(5µg), Ofloxacin(5µg), Gatifloxacin(5µg), Gentamycin(10µg), Moxifloxacin(5µg), and Tobramycin(10µg). A 0.5 Mc Farland standard suspension of isolate was made and lawn culture done on Muller Hinton Agar. Plates were incubated at 37°C for 18hrs and zone diameters were measured. All isolates were tested for methicillin resistance by cefoxitin (Cx-30µg) disc.

RESULTS:

Total of 468 samples were collected during six months period. Out of which *Staphylococcus* isolates were 218. Among them, methicillin resistance was seen in 47 (21.5%) of samples (table1).

Table-1: Incidence of methicillin resistance

	S.aureus	CONS	Total
Methicillin resistance	3 (1.3%)	44 (20.19%)	47 (21.5%)

35 (74.4%) samples were collected on outpatient basis and rest 12(25.6%) were from inpatient. 36(76.5%) patients were males and 11(23.5%) patients were females (%).

DISCUSSION:

Approximately 20% of the population carries *S.aureus* persistently, 60% are intermittent carriers, and 20% are non-carriers who rarely harbor *S.aureus*. Historically, MRSA pathogens were Antibiotic susceptibility pattern of Cefoxitin resistance *Staphylococcus*

Table-2: Antibiotic susceptibility of methicillin resistant *Staphylococcus*.

Antibiotic	Sensitive	Resistance
C Chloromphenicol (30µg)	91.48%	8.52%
Caz Ceftazidime (30µg)	19.14%	80.86%
Cip Ciprofloxacin (5µg)	46.8%	53.2%
Of Ofloxacin (5µg)	29.78%	70.22%
Gat Gatifloxacin (5µg)	31.91%	68.09%
Gen Gentamycin (10µg)	82.9%	17.1%
Mo Moxifloxacin (5µg)	95.74%	4.26%
Tob Tobramycin (10µg)	80.85%	19.15%

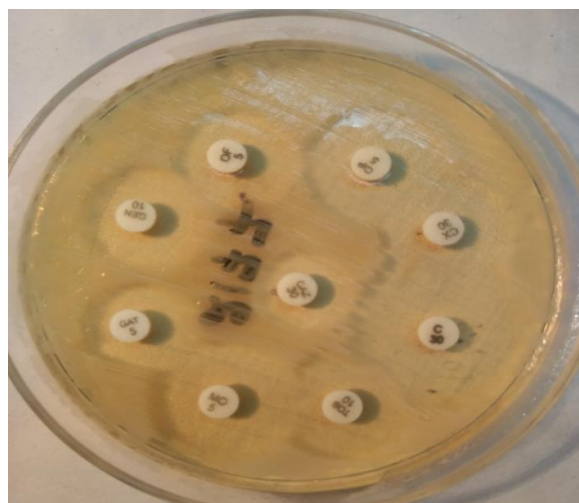


Fig-1: AST on MHS showing Cx sensitive

Almost exclusively isolated from hospitals or hospital-associated facilities. However, an increasing number of MRSA cases have been reported in individuals with no known risk factors for MRSA colonization, such as admission to a hospital, surgery, and contact with a MRSA-colonized patient, intravenous drug use, or previous antibiotic exposure. These isolates, termed community acquired MRSA.

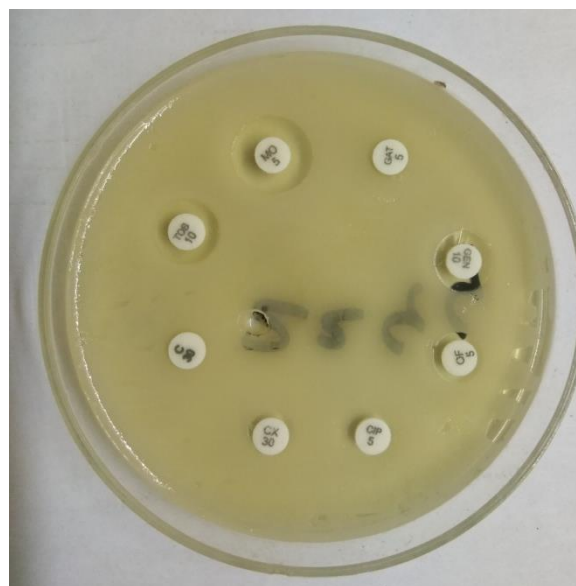


Fig-2: AST on MHA showing Cx resistance, other drug resistance

Have become a global concern and have been found worldwide, not only in the community setting but also in healthcare facilities. The prevalence of MRSA colonization seems to vary by community[5]. Reports of MRSA ophthalmic infections are increasing in the literature.

Staphylococcus aureus is reported to be the second most common pathogen causing bacterial

keratitis across the world. Of special concern are increasing reports of postoperative MRSA infection. MRSA keratitis, a serious and increasing complication following ophthalmic surgery, has been found after laser in situ keratomileusis and photorefractive keratectomy (PRK)[6, 7].

Coagulase-negative *Staphylococci* are the indigenous flora of our skin and mucous membrane. Coagulase-negative *Staphylococci* are isolated in large numbers from diverse ophthalmic conditions like chronic blepharitis, purulent conjunctivitis and suppurative keratitis. As they form the part of the normal flora, effective management may not be aimed at curtailing coagulase-negative *Staphylococci* (CoNS)[10].

Staphylococcus epidermidis has been reported with increasing frequency as a cause of bacterial endophthalmitis[11-15]. In the present study, the incidence of ocular Methicillin resistant *Staphylococcus* was 21.5%. Conjunctivitis is the most commonly reported manifestation and has been associated with long-term care units, especially in patients with neurologic impairment, nurseries and neonatal ICUs; and healthcare workers[16-18].

In South Florida by Cavuoto *et al.* showed increased prevalence of MRSA and MRSE in conjunctivitis from 4.4 % (1994-5) to 42.9% (2002-3) [19, 20]. ChingHsi Hsiao *et al.*; reported the average rate of MRSA in *S. aureus* infections was 52.8% with a stable trend, whereas the annual ratio of CA-MRSA in ocular MRSA infections averaged 66.1% and tended to increase over the 10 year interval[21]. Aravind eye hospital reported 26% of Methicillin resistant *Staphylococcus* during the year 2012(January to December)[22]. Penny *et al.* reported increase of *S. aureus* infections culture positive for methicillin resistant *S. aureus* (MRSA) from 29.5% in 2000 to 41.6% in 2005[23]. Malathi *et al.*; reported 4.5% Methicillin resistant *Staphylococcus* from post-operative endophthalmitis[24].

Sotozono *et al.*; detected Methicillin-resistant *S. aureus* or MRSE was from 30 cases with ocular diseases over 5 year period from January 1996 to December 2000[25]. The *S. epidermidis* strains from conjunctivitis, CU, and endophthalmitis exhibited 46, 33.9, and 34.1% of oxacillin resistance respectively in a study conducted by Juárez *et al.*:[26].

Antibiotic susceptibility pattern of these isolates showed resistance to Ceftazidime 80.86%, Ofloxacin 70.22%, Gatifloxacin 68.09%, Ciprofloxacin 53.2%, Gentamycin 17.1%, and Chloramphenicol 8.52%. Manikandan *et al.*; reported resistance of Gentamycin

74.2%, Chloramphenicol 54.2%, Ciprofloxacin 40.0% and Ofloxacin 31.4%[10].

Bharathi *et al.*; reported the resistance in (CoNS) as Gatifloxacin 95%, Chloramphenicol 70%, Ofloxacin 43%, Gentamycin 41%, Ciprofloxacin 41%, and Ceftazidime 22%[27]. Vancomycin is known to be effective for treating MRSA/MRSE infections. MRSA isolated from ocular infections is often susceptible to chloramphenicol, fourth-generation fluoroquinolones and other antibiotics. Thus, it is preferable to use Vancomycin Ophthalmic Ointment 1% only for a short period of time and only for patients who specifically require this new drug[28].

Blanco *et al.*; studied Susceptibility of methicillin-resistant *Staphylococci* clinical isolates to Netilmicin and other antibiotics commonly used in ophthalmic therapy and reported 27.9% MRSE and in MRSE group, 25% of the strains tested were resistant to C and MXF while 33%, 42% and 58% of the strains were resistant to LEV, AZM and TOB, respectively[29].

CONCLUSION:

MRSE infection accounts for 20.19% of *Staphylococcus* isolates in ocular samples in this study. They showed resistance to other drugs-Ceftazidime, Ofloxacin, Gatifloxacin and sensitive to Moxifloxacin, Chloramphenicol and Tobramycin. The incidence of Methicillin resistance in ocular samples is increasing. Antibiotic resistance among ocular pathogens is a challenge to the ophthalmologist. Vancomycin, a glycopeptide antibiotic, is known to be effective for treating methicillin resistance *Staphylococcus* infections.

REFERENCES:

1. Partica M. Tille. Bailey and Scott's Diagnostic Microbiology. 13 edition, St. Louis, Mosby: Elsevier; 2014. pg -232.
2. Saxena H, Goswami P. Bacterial and fungal flora of the normal eye. Indian journal of ophthalmology. 1971 Sep 1; 19(3):130.
3. Sotozono C, Fukuda M, Ohishi M, Yano K, Origasa H, Saiki Y, Shimomura Y, Kinoshita S. Vancomycin ophthalmic ointment 1% for methicillin-resistant *Staphylococcus aureus* or methicillin-resistant *Staphylococcus epidermidis* infections: a case series. BMJ open. 2013 Jan 1; 3(1):e001206.
4. Walvick MD, Khan A. Ophthalmic methicillin-resistant *Staphylococcus aureus* infections: Sensitivity and resistance profiles of 65 isolates in central California. Advances in Bioscience and Biotechnology. 2013 Feb 1; 4(2A):263.

5. Mah FS, Davidson R, Holland EJ, Hovanesian J, John T, Kanellopoulos J, Shamie N, Starr C, Vroman D, Kim T, ASCRS Cornea Clinical Committee. Current knowledge about and recommendations for ocular methicillin-resistant *Staphylococcus aureus*. *Journal of Cataract & Refractive Surgery*. 2014 Nov 30; 40(11):1894-908.
6. Tuft SJ, Matheson M. In vitro antibiotic resistance in bacterial keratitis in London. *British journal of ophthalmology*. 2000 Jul 1; 84(7):687-91.
7. Schaefer F, Bruttin O, Zografos L, Guex-Crosier Y. Bacterial keratitis: a prospective clinical and microbiological study. *British Journal of Ophthalmology*. 2001 Jul 1; 85(7):842-7.
8. Shanmuganathan VA, Armstrong M, Buller A, Tullo AB. External ocular infections due to methicillin-resistant *Staphylococcus aureus* (MRSA). *Eye*. 2005 Mar 1; 19(3):284-91.
9. Deramo VA, Lai JC, Winokur J, Luchs J, Udell IJ. Visual outcome and bacterial sensitivity after methicillin-resistant *Staphylococcus aureus*-associated acute endophthalmitis. *American journal of ophthalmology*. 2008 Mar 31; 145(3):413-7.
10. Manikandan P, Bhaskar M, Revathy R, John RK, Narendran K, Narendran V. Speciation of coagulase negative *Staphylococcus* causing bacterial keratitis. *Indian journal of ophthalmology*. 2005 Jan 1; 53(1):59.
11. O'Day DM, Jones DB, Patrinely J, Elliott JH. *Staphylococcus epidermidis* endophthalmitis. Visual outcome following noninvasive therapy *Ophthalmology*. 1982 Apr;89(4):35460
12. Fass RJ, Helsen VL, Barnishan J, Ayers LW. In vitro susceptibilities of four species of coagulase-negative staphylococci. *Antimicrobial agents and chemotherapy*. 1986 Oct 1; 30(4):545-52.
13. Bannerman TL, Rhoden DL, McAllister SK, Miller JM, Wilson LA. The source of coagulase-negative staphylococci in the Endophthalmitis Vitrectomy Study: a comparison of eyelid and intraocular isolates using pulsed-field gel electrophoresis. *Archives of ophthalmology*. 1997 Mar 1; 115(3):357-61.
14. Bohigian GM, Olk RJ. Factors associated with a poor visual result in endophthalmitis. *American journal of ophthalmology*. 1986 Mar 31; 101(3):332-41.
15. Heaven CJ, Mann PJ, Boase DL. Endophthalmitis following extracapsular cataract surgery: a review of 32 cases. *British journal of ophthalmology*. 1992 Jul 1; 76(7):419-23.
16. Ribner BS. Endemic, multiply resistant *Staphylococcus aureus* in a pediatric population: Clinical description and risk factors. *American Journal of Diseases of Children*. 1987 Nov 1; 141(11):1183-7.
17. Ross J, Abate MA. Topical vancomycin for the treatment of *Staphylococcus epidermidis* and methicillin-resistant *Staphylococcus aureus* conjunctivitis. *DICP: the annals of pharmacotherapy*. 1990 Nov; 24(11):1050-3.
18. Fukuda M, Ohashi H, Matsumoto C, Mishima S, Shimomura Y. Methicillin-Resistant *Staphylococcus aureus* and Methicillin-Resistant Coagulase-Negative *Staphylococcus* Ocular Surface Infection: Efficacy of Chloramphenicol Eye Drops. *Cornea*. 2002 Oct 1; 21:S86-9.
19. Cavuoto KM, Zutshi D, Miller D, Karp C, Feuer WJ. Update on Bacterial Conjunctivitis in South Florida. *Investigative Ophthalmology & Visual Science*. 2006 May 1; 47(13):1907-.
20. Sharma S. Antibiotic resistance in ocular bacterial pathogens. *Indian journal of medical microbiology*. 2011 Jul 1; 29(3):218.
21. Chuang CC, Hsiao CH, Tan HY, Ma DH, Lin KK, Chang CJ, Huang YC. *Staphylococcus aureus* ocular infection: methicillin-resistance, clinical features, and antibiotic susceptibilities. *PLoS one*. 2012 Aug 7; 7(8):e42437.
22. Annual report 2012-2013. Basic research in ophthalmology. Pg.no-12
23. Chandravanshi SL, Sutrarakar SK, Bajaj N. Community-acquired methicillin-resistant *Staphylococcus aureus* bilateral acute dacryocystitis in a neonate. *Indian journal of ophthalmology*. 2012 Mar 1; 60(2):155.
24. Jambulingam M, Parameswaran SK, Lysa S, Selvaraj M, Madhavan HN. A study on the incidence, microbiological analysis and investigations on the source of infection of postoperative infectious endophthalmitis in a tertiary care ophthalmic hospital: an 8-year study. *Indian journal of ophthalmology*. 2010 Jul 1; 58(4):297.
25. Sotozono C, Inagaki K, Fujita A, Koizumi N, Sano Y, Inatomi T, Kinoshita S. Methicillin-resistant *Staphylococcus aureus* and methicillin-resistant *Staphylococcus epidermidis* infections in the cornea. *Cornea*. 2002 Oct 1; 21:S94-101.
26. Juárez Verdayes, Reyes López, CancinoDíaz, MuñozSalas S, RodríguezMartínez S, de la Serna FJ, HernándezRodríguez CH, CancinoDíaz JC. Isolation, vancomycin resistance and biofilm production of *Staphylococcus epidermidis* from patients with conjunctivitis, corneal ulcers, and

- endophthalmitis. *Rev Latinoam Microbiol.* 2006 Jul-Dec;48 (34):23846.
27. Bharathi MJ, Ramakrishnan R, Shivakumar C, Meenakshi R, Lionalraj D. Etiology and antibacterial susceptibility pattern of community-acquired bacterial ocular infections in a tertiary eye care hospital in south India.
 28. Sotozono C, Fukuda M, Ohishi M, Yano K, Origasa H, Saiki Y, Shimomura Y, Kinoshita S. Vancomycin ophthalmic ointment 1% for methicillin-resistant *Staphylococcus aureus* or methicillin-resistant *Staphylococcus epidermidis* infections: a case series. *BMJ open.* 2013 Jan 1; 3(1):e001206.
 29. Blanco AR, Sudano Roccaro A, Spoto CG, Papa V. Susceptibility of methicillin-resistant *Staphylococci* clinical isolates to netilmicin and other antibiotics commonly used in ophthalmic therapy. *Current eye research.* 2013 Aug 1; 38(8):811-6.