

## **Case Report**

### **Metastatic Seminoma Presenting As Enlarged Neck Node: Diagnosis by Fine Needle Aspiration Cytology**

**Dr. Swagata Dowerah, Dr. Aseema Das, Dr. Mondita Borgohain**

Department of Pathology, Assam Medical College, Dibrugarh, Assam, India

#### **\*Corresponding author**

Dr. Swagata Dowerah

Email: [swagatadowerah@gmail.com](mailto:swagatadowerah@gmail.com)

---

**Abstract:** In testicular malignancy, the incidence of neck metastases range from 4.5 to 15% and in an estimated 5% of these cases, a neck mass is the initial presentation. We present a case of testicular seminoma which presented with a neck mass. Initial diagnosis was offered from FNAC of the neck node(left supraclavicular) and later confirmed on histopathological examination of the inguinal testis. A 27 year old male presented with swelling in the neck of 2 months duration. CT scan of the neck reported a necrotic nodal lesion. FNAC from the cervical node showed highly cellular smear comprising of pleomorphic cells arranged singly and in clusters in a tigroid background along with few mature lymphocytes and possibility of seminoma was suggested. USG abdomen was done and revealed a testicular mass with retroperitoneal nodes. On histopathological examination, diagnosis of seminoma was confirmed. Metastatic seminoma must be kept in mind in the differential diagnosis of cervical lymphadenopathy in a male patient as it may aid in the diagnosis of an unsuspected primary testicular tumor in many cases.

**Keywords:** seminoma, metastasis, cervical node.

---

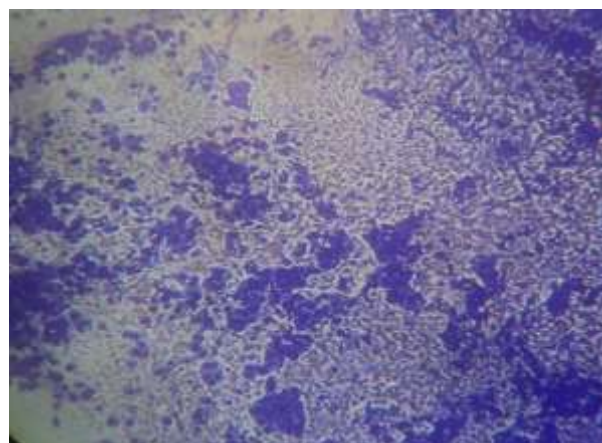
#### **INTRODUCTION**

Testicular tumors represent only 1 % of all cancers in males, yet they are the most common malignancy in age group of 15 to 35 year with a median age at diagnosis of 34 years [1, 2]. In testicular malignancy, the incidence of neck metastases range from 4.5 to 15% and in an estimated 5% of these cases, a neck mass is the initial presentation [3, 4]. We present a case of testicular seminoma who presented with a neck mass and initial diagnosis was offered from FNAC of the neck node(left supraclavicular) and later confirmed on histopathological examination of the inguinal testis.

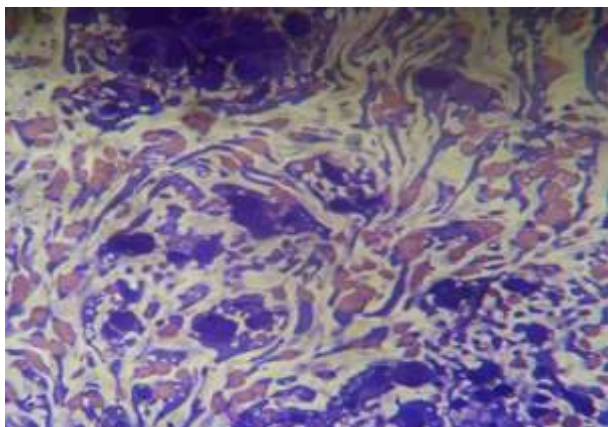
#### **CASE HISTORY**

A 27 year old male presented with swelling in the neck of 2 months duration. Swelling was present on the left side of the neck, was hard, non-tender, measuring 3.5x3.5cms. Blood evaluation of the patient was within normal limit. However, T4 was low with rise in TSH levels. CT scan of the neck was done and reported as a necrotic nodal lesion. FNAC was performed from the cervical node which showed highly cellular smear comprising of pleomorphic cells arranged singly and in clusters in a tigroid background along with few mature lymphocytes. Individual cells showed high nucleocytoplasmic ratio with vesicular

nuclei, prominent nucleoli and vacuolated cytoplasm and possibility of seminoma was suggested(Fig 1,2).



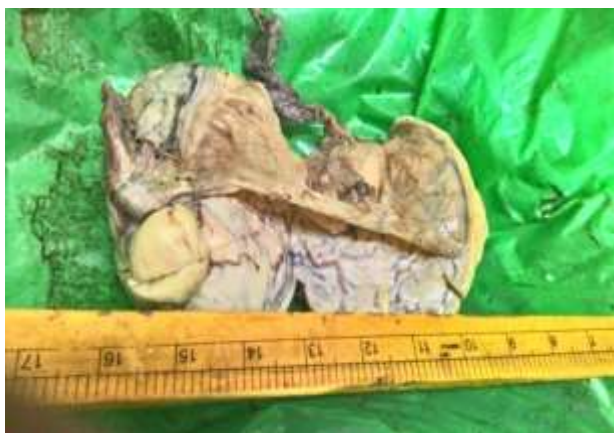**Fig. 1: showing malignant cells in a tigroid background ( 10X) – FNA cervical node**



**Fig. 2: showing seminoma cells both dispersed and in loose clusters against a tigroid background (40X) - FNA cervical node**

Serum AFP was done and found to be within normal limit. USG abdomen was done and revealed a testicular mass with retroperitoneal nodes.

The mass was excised and sent for histopathological examination. Gross examination revealed a 5x4x3 cm mass which was whitish in colour. Cut surface was solid and lobulated (Fig 3). H&E stained sections showed histopathological features suggestive of testicular seminoma.



**Fig. 3: showing gross appearance of testicular mass**

## DISCUSSION

Germ cell tumors account for 98% of all testicular malignancies. The most important division in germ cell tumors, both conceptually and practically, is between two major categories: seminoma and all the others, which are collectively referred to as nonseminomatous germ cell tumors (NSGCT) [5]. Cytologic diagnosis of seminoma relies on the tigroid appearance due to the fragile nature of seminoma cells and on the presence of prominent nucleoli in the viable [6].

Most patients present with a painless testicular lump. Patient may present with a hydrocoele and uncommonly, testicular pain may be present. When a neck mass is found to be a metastatic germ cell tumor, it is usually in the setting of a known primary tumor [7]. Although some authors have estimated that as many as 5% of germ cell tumors initially manifest as a neck mass, case reports of such an occurrence are rare [3, 4]. Involvement of cervical nodes signifies advanced disease. Rarely the neck mass is the only manifestation, primary being either occult or neglected. In our case, the primary tumor was neglected and patient came to medical attention owing to appearance of the neck mass.

## CONCLUSION

It therefore needs to be emphasised that although cervical node metastasis of seminoma as a presenting feature is rare, metastatic seminoma must be kept in mind in the differential diagnosis of cervical lymphadenopathy in a male patient as it may aid in the diagnosis of an unsuspected primary testicular tumor in many cases. This needs to be differentiated from other metastatic tumors like lymphoma, adenocarcinoma, amelanotic melanoma based on characteristic cytomorphologic features.

## ACKNOWLEDGEMENTS

We would like to thank Dr. Projnan Saikia, Professor & In charge of Histopathology section for his valuable inputs in this case.

## REFERENCES:

1. Cooper DE, L'Esperance JO, Christman MS, Auge BK; Testis cancer: a 20-year epidemiological review of the experience at a regional military medical facility. *J Urol.*, 2008; 577-582.
2. Ries LA, Melbert D, Krapcho M, et al; SEER Cancer Statistics Review. [Online].; 1975-2005 [cited 2008 November 20. Available from: [http://seer.cancer.gov/csr/1975\\_2005/](http://seer.cancer.gov/csr/1975_2005/).
3. See WA, Laurenzo JF, Dreicer R, Hoffman HT; Incidence and management of testicular carcinoma metastatic to the neck. *J Urol.*, 1996; 590-2.
4. Zeph RD, Weisberger EC, Einhorn LH, Williams SD, Lingeman RE; Modified neck dissection for metastatic testicular carcinoma. *Arch Otolaryngol.*, 1985; 667-72.
5. Bahrami A, Ro JY, Ayala AG; An overview of testicular germ cell tumors. *Arch Pathol Lab Med.*, 2007; 1267-1280.
6. Orell SR, Sterrett GF, Whitaker D; Male and Female genital organs. 4th ed. Darrel Whitaka SROaGFS, editor. New Delhi: Elsevier; 2005.
7. Lynch DF Jr, Richie JP; Supraclavicular node biopsy in staging testis tumors. *J Urol.*, 1980; 39-40.