

Case Report**An Unusual Cause of Unilateral Proptosis****Dr. Mrudul. R. Nair¹, Dr. Rekha. N.H², Dr. Shivakumar Swamy. S³, Dr. Bharath. M.S⁴**¹Post Graduate student, ²Associate Professor, ⁴Assistant Professor, Department of General Medicine, Rajarajeswari Medical College & Hospital, Bengaluru, Karnataka³Chief Radiologist, Department of Radiodiagnosis and Interventional Radiology, HCG, Sampangirama Nagar, Bengaluru, Karnataka***Corresponding author**

Dr. Rekha. N. H

Email: drrekhanh@gmail.com

Abstract: Carotid Cavernous Fistula (CCF) is a spontaneous or acquired communication between the carotid artery and cavernous sinus. The cavernous segment of the carotid artery is unique. It is the only location in the body where an artery is completely surrounded by a venous structure. Here we are reporting a 50 year old diabetic normotensive female who presented with headache, pain, swelling and redness of her right eye, finally diagnosed for caroticocavernous fistula after ruling out other causes of proptosis.

Keywords: Unilateral proptosis, caroticocavernous fistula

INTRODUCTION

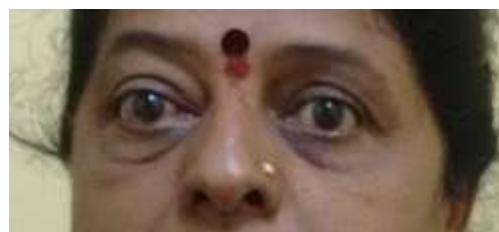Proptosis is defined as forward displacement of the eyeball beyond the orbital margins. It can be classified into: unilateral proptosis, bilateral proptosis, acute proptosis, intermittent proptosis and pulsating proptosis [1]. When the globes appear asymmetric, the clinician must first decide which eye is abnormal. Is one eye recessed within the orbit (enophthalmos) or is the other eye protuberant (exophthalmos or proptosis)? The position of the eyes is measured by using a Hertel exophthalmometer. Clinically, relative eye position can be judged by bending the patient's head forward and looking down upon the orbits. A proptosis of only 2 mm in one eye is detectable from this perspective. The development of proptosis implies a space-occupying lesion in the orbit and usually warrants CT or MR imaging [2].

Causes of unilateral proptosis include cystic lesions, orbital haemorrhage, retained intraorbital foreign body, acute inflammatory lesions like orbital cellulitis, abscess, thrombophlebitis, panophthalmitis, cavernous sinus thrombosis (proptosis is initially unilateral) and chronic inflammatory lesions which include pseudotumours, tuberculoma, gumma and sarcoidosis. Vascular lesions such as orbital varix and aneurysms also cause unilateral proptosis. Other common causes are tumours of the orbit, mucoceles of paranasal sinuses and Graves' thyrotoxicosis.

Caroticocavernous fistula is a rare cause of unilateral proptosis.

CASE DESCRIPTION

A 50 year old diabetic normotensive female presented with headache, progressive swelling, pain and redness of her right eye of 2 months duration. She also gave a history of trauma to the right cheek 5 months ago following which she took medications for pain after consulting a nearby doctor and ruling out external injuries over the head. She had no history suggestive of weight loss, palpitation, fever or visual disturbances. She had attained menopause. Patient had normal vital parameters and systemic examination was normal. Local examination revealed swelling of right eye and conjunctival congestion (Photo1). Patient had normal bilateral extraocular movements and bilateral fundus examination was normal. Right eye intraocular pressure was increased. We found bruit over the right eye.

**Photo-1: Right eye proptosis**

Patient was diagnosed for unilateral proptosis and possibilities of thyrotoxicosis, vascular disease and orbital pseudotumor were considered. Her blood investigations including thyroid function tests and workup for connective tissue disorders were normal.

MRI Brain was normal. MRI orbits and TOF MR Angiogram revealed right orbital proptosis with dilatation of the right superior ophthalmic vein and arterialization of the same (Figures 1 & 2). MRV was normal and hence ruled out thrombosis.

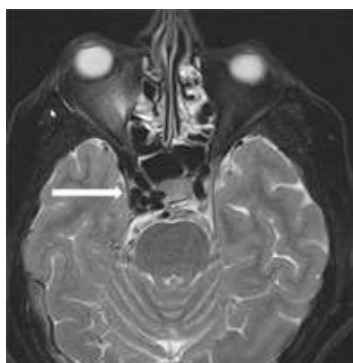


Fig-1: Axial T2W image shows serpiginous flow voids in the right cavernous sinus (arrow).

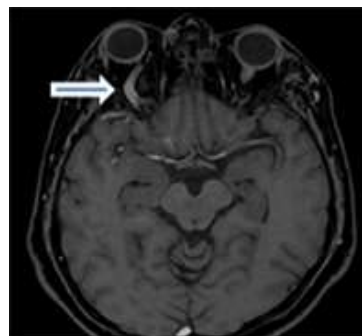


Fig-2: 2D TOF MR Angiogram axial source image shows dilated right superior ophthalmic vein, suggestive of arterialization of the same

As MR Angiogram was suggestive of CCF (figures 3a, 3b, 3c) Digital Subtraction Angiography (DSA) was performed which revealed high flow direct CCF Type A (figure 4). Neurosurgeon opinion was sought and patient was planned for coil embolization of the fistula. Post coil embolization DSA showed complete resolution of the CCF (figure 5).

24 hours following coil embolization, congestion in the right eye completely resolved and 48 hours later, swelling of the right eye reduced. She had an uneventful post-operative period.

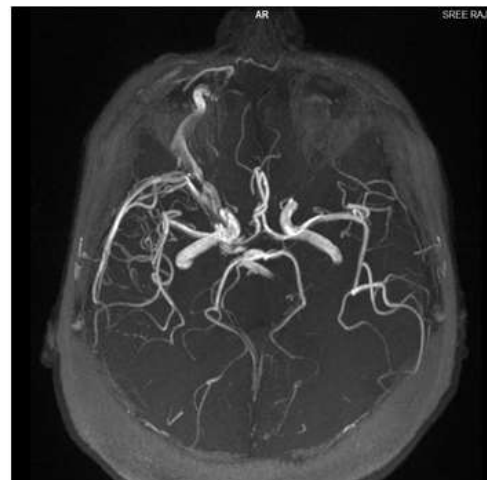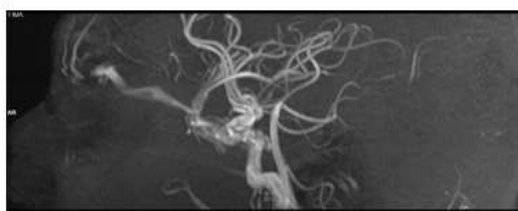
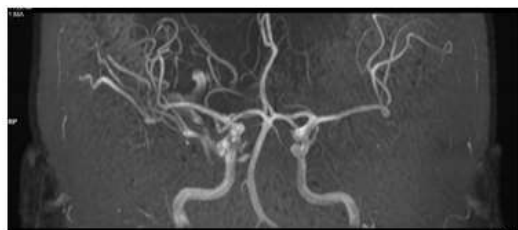


Fig-3a, 3b, 3c (clockwise from right): 3D TOF MRA of the Circle of Willis shows fistulous communication between the cavernous segment of the right ICA and the cavernous sinus. The right superior ophthalmic vein and the cortical veins are dilated in the middle cranial fossa.

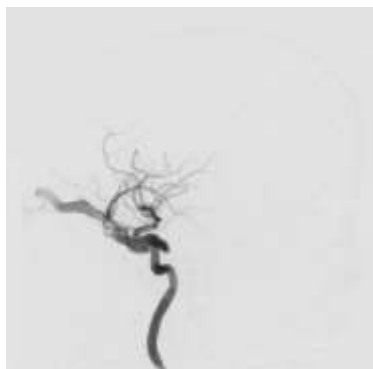

Fig-4: DSA, ICA injection. Lateral view shows fistulous communication between the cavernous segment of the right ICA and the cavernous sinus, suggestive of CCF Type A.

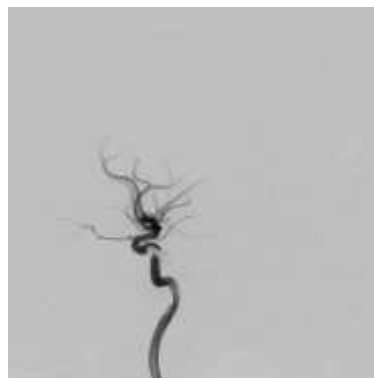

Fig-5: DSA, lateral view post coil embolization

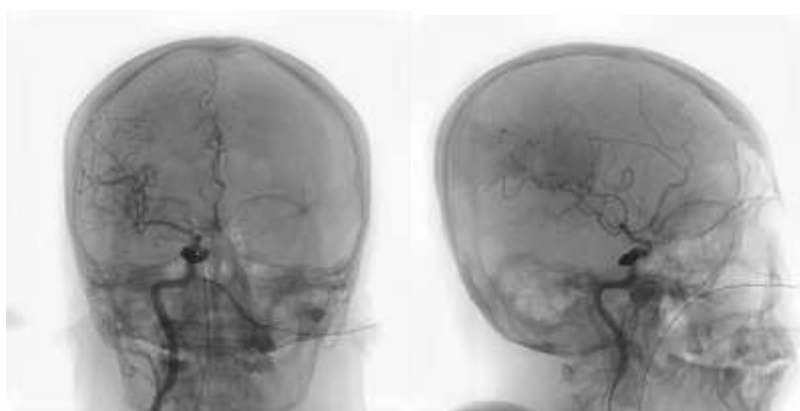


Fig-6a, 6b: 3D reconstruction cerebral angiogram acquisition AP & oblique views - post coil embolization

Patient was discharged and asked to follow up after 1 month during which examination of the patient

revealed normal right eye with normal extraocular movements bilaterally (Photo 2).



Photo-2: Normal right eye on follow up

DISCUSSION

A carotid cavernous fistula is a type of arteriovenous fistula that results from an abnormal communication between the arterial (i.e. internal carotid artery and branches of external carotid artery) and venous systems within the cavernous sinus in the skull. As arterial blood under high pressure enters the cavernous sinus, the normal venous return to the cavernous sinus is impeded and this results in engorgement of the draining veins.

Elevated pressure inside the cavernous sinus and altered venous drainage leads to clinical signs such as conjunctival redness, proptosis, decreased visual acuity, elevated intraocular pressure and cranial nerve palsies by causing pressure on 3rd, 4th and 6th cranial nerves which can result in ophthalmoplegia [3].

CCFs are caused by the laceration of the inter-cavernous portion of the carotid artery or one of its inter-cavernous branches leading to arterialisation of blood within the cavernous sinus. A CCF allows

shunting of blood from the high pressure internal carotid artery to a low pressure system which results in the engorgement of the ophthalmic venous system with congestion and oedema of the orbital tissue. It can occur spontaneously (25%) or following trauma (75%). It can also be classified as Direct (Type A) and Indirect (Type B, C & D). Direct type occurs following trauma as found in our case. Direct fistulas have high pressure and high flow. Indirect types occur due to spontaneous rupture of dural branches of the intracavernous arteries usually causing low-flow fistulae, and are often associated with connective tissue disorder or vascular disease. Indirect fistulas have slower progression of signs and symptoms. Severe blunt trauma is a more common mechanism to cause CCF than severe penetrating injuries. Symptoms can present suddenly in direct fistula but can also develop even weeks after injury. Chemosis, pulsatile exophthalmos and ocular bruit are the triad of symptoms. However, these features can also be absent in indirect fistula. They can present as unilateral chronic red eye due to tortuous arterIALIZATION of conjunctiva. MRI of brain and orbit are the choice of diagnosis [4].

It has been found that nearly 80% of cases of superior ophthalmic vein dilatation as found on imaging, were the result of carotico-cavernous fistula as found in our case, whereas only 12% were the result of Graves' disease and many fewer were the result of other aetiologies. History taking and clinical examination help in pointing out the correct diagnosis [5].

Digital Subtraction Angiography (DSA) provides superior capability to accurately localize lesions for endovascular management. DSA helps in estimating the size, associated cavernous carotid aneurysm and also to differentiate between direct and indirect types. Prompt treatment is required in cases of CCF with progressive symptoms, since visual loss occurs in approximately 90% of untreated patients [6].

Conservative treatment is indicated for small, asymptomatic or stable fistulae since they may close spontaneously. The goal of treatment is to obliterate the fistula and maintain the patency of internal carotid artery. Embolization is most often carried out using detachable balloons, though platinum coils, liquid embolizing agents, stents or a combination may be used [7]. In case an endovascular approach turns out to be ineffective, surgical management by direct repair of the fistula within the cavernous sinus is possible [8]. With timely intervention, patients generally have good prognosis after treatment as observed in our patient.

CONCLUSION:

CCFs that have principal drainage into the superior and inferior ophthalmic vein present with predominant orbital symptoms. There should be a high

index of suspicion when a patient presents with orbital symptoms after head injury. But the low flow at the shunt and non-specific nature of the symptoms makes indirect CCF even more difficult to diagnose.

Primary care physicians and ophthalmologists should suspect the possibility of CCF in patients presenting with unilateral swelling of orbit as found in this case report. Early diagnosis and treatment can prevent life threatening complications. Though our patient presented 5 months after the trauma, slow progression of symptoms, detailed evaluation and timely intervention helped our patient recover without any sequelae.

REFERENCES

1. Khurana AK. Comprehensive ophthalmology. New Age International Ltd; 2007.
2. Horton JC. Harrison's principles of internal medicine.
3. Kin-ming Cheng. Neuro-endovascular Therapy of Carotid-Cavernous Fistula. The Hong Kong Medical Diary. 2006; 11(12):13-14.
4. KH Lau, CP Ng, CH Chung. Carotid-cavernous fistula: an uncommon and easily missed complication of head trauma. Hong Kong Journal of Emergency Medicine. 2005; 12(2):95-98.
5. Wei R, Cai J, Ma X, Zhu H, Li Y. Imaging diagnosis of enlarged superior ophthalmic vein. Zhonghua Yan Ke Za Zhi. 2002; 38:402-404.
6. Naesens R, Mestdagh C, Breemers M, Defreyne L. Direct carotid-cavernous fistula: a case report and review of the literature. Bulletin de la Societe Belge d Ophthalmologie. 2006; 43-54.
7. Tjoumakaris SI, Jabbour PM, Rosenwasser RH. Neuroendovascular management of carotid cavernous fistulae. Neurosurgery Clinics of North America. 2009; 20:447-452.
8. Tu YK, Liu HM, Hu SC. Direct surgery of carotid cavernous fistulae and dural arteriovenous malformations of the cavernous sinus. Neurosurgery. 1997; 41:798-805.