

Original Research Article

The use of three dimensional hysterosonography in recurrent implantation failure prior to in vitro fertilization cycles

Ashraf Talaat Youssef¹, Wessam Deeb²¹Department of Radiology²Department of Obstetrics and Gynecology,
Faculty of Medicine, Fayoum University, Egypt

*Corresponding author

Ashraf Talaat Youssef

Email: ashraftalaat1@yahoo.com

Abstract: Recurrent implantation failure can be due to endometrial cavity abnormalities or abnormal endometrial thickness, hysteroscopy and hysterosonography can be used to evaluate the presence of endometrial polyps, submucous myomas, endometrial cavity adhesions and abnormal endometrial thickness. The current study aimed to evaluate the value of performing 3D hysterosonography prior to in vitro fertilization cycle as an alternative tool to hysteroscopy. Referred 250 patients suffered from recurrent implantation failure and all were examined with 3D transvaginal ultrasound followed by 3D hysterosonography at day 8-10 of non-stimulated cycle prior to in vitro fertilization cycle. 116 patients (43%) were detected with endometrial cavity abnormalities and abnormal endometrial thickness. All patients except 10 patients, (8 patients with thin endometrium and 2 patients with large mixed mural-submucosal myomas) were subjected to hysteroscopy treatment and showed complete agreement between the findings of 3D hysterosonography and hysteroscopy. 3D hysterosonography is a valuable alternative tool to hysteroscopy in evaluating endometrial cavity abnormalities and abnormal endometrial thickness in patients suffered from recurrent implantation failure of in vitro fertilization cycles.

Keywords: Three dimensional: Hysterosonography: Hysteroscopy: In vitro fertilization cycle, implantation failure

INTRODUCTION:

Intracytoplasmic sperm injection (ICSI) is an in vitro fertilization procedure in which a single Sperm is injected directly into an egg. The defective sperm function remains the most single important cause of human infertility [1]. Sometimes the sperm can't penetrate the outer layer of the egg, it may be thick or hard to penetrate or the sperm cannot swim. In these cases, a process called intra cytoplasmic Sperm injection (ICSI) can be done.

Pregnancy rate following one cycle of ICSI can be as high as 60%. Although the success rate of ICSI is increasing over the last few years, however many couples are frustrated by ICSI failure. Successful embryo implantation is a process which requires both asynchronous development and interaction between hatched blastocyst and the endometrium. According to Coughlam *et al.*; The term "implantation failure" refers to different types of cases, those in whom there has never been evidence of implantation (no detectable HCG production) and those who have evidence of

implantation (detectable HCG) but it didn't proceed beyond the formation of gestational sac seen by ultrasound[2].

Etiology of implantation failure:

1) Factors related to decreased endometrial receptivity

A: Uterine cavity abnormalities eg: septate, Sub septate uterus, arcuate uterus.

B: Endometrial polyp and submucous myomas.

C: Inadequate endometrial thickness and uterine adhesions.

D: Modified expression of adhesion molecules

E: Immunologic disorders and thrombophilia

2) Factors related to a defective embryonic development

A: Genetic abnormalities affecting partners, gametes, or embryos

B: Hardening of zona pellucida

3) Multifactorial e.g. Endometriosis, presence of hydrosalpinges [3].

In our study we are concerned about investigations to assess the uterine cavity and the endometrial thickness. Hysterosalpingography (HSG), transvaginal ultrasonography, saline infusion sonography and hysteroscopy are the tools to assess the inner architecture of the uterus [4]. Hysterosalpingography is sensitive, but its specificity for detection of uterine abnormalities is low (23%) with a false positive rate of (44%) and false negative rate of (10%) [5]. Transvaginal sonography is more specific (96.3%) and sensitive (81.8%) than HSG with negative (97.6%) and positive (73.8%) predictive values for detection of intrauterine abnormalities [6,7]. Accordingly, saline infusion sonohysterography is an accurate and safe method of evaluation of the uterine cavity [8].

The aim of the work:

The study aimed to evaluate the role of 3D hysterosonography in evaluating patients with recurrent implantation failure prior to in vitro fertilization cycle

METHODOLOGY:

- Referred 250 female patients to the ultrasound clinic of IVF /ICSI center in Fayoum city – Egypt.
- All were given a history of 2 consecutive cycles of IVF/ICSI with implantation failure after transfer of >3 good quality embryos with subsequent pregnancy failure.
- Pregnancy failure was considered if no detectable HCG production or no gestational sac with viable fetus was seen intra uterine after 35 days of the embryo transfer.
- Biochemical pregnancy with no intrauterine sac at 35 days from embryo transfer was considered as transient elevation in pregnancy hormones.
- Cases showed blighted ovum and ectopic pregnancy were excluded from the study.
- Their age ranged from 25 To 35 years with the mean age was 28 years.
- All were subjected to base line 3 D transvaginal ultrasound exam at day 8-10 of non stimulated cycle using an endocavitary multifrequency volume probe, GE Logic 7 ultrasound machine (Milwaukee, WI, USA) .
- All were examined by a single operator experienced in Gynecologic ultrasound.
- The base line three dimensional (3D) transvaginal ultrasound was used to evaluate the total endometrial thickness, uterine anomalies , the presence of myomas as regard to its site ,number and sizes as regard to the myomas mean diameter ,which was equal to the summit of the length , width and height in cm and divided by 3.
- The myomas were classified into submucous, mural, sub serous, mixed mural-submucous and mixed mural-sub serous.
- The adnexal regions were scanned for the presence of hydrosalpinx, ovarian cysts, polycystic ovaries and any solid adnexal masses.
- 3D hysterosonography was performed after the baseline 3D transvaginal ultrasound by introducing speculum into the vagina.
- The cervix was cleaned, then a pediatric Foley catheter (No 5) was introduced into the lower uterine corpus and the balloon was inflated with 1-2 ml sterile saline.
- After catheter fixation, a sterile saline was injected slowly until the uterine cavity became distended.
- The 3D endocavitary volume probe was introduced into the vagina after removing the speculum.
- 3D ultrasound volume analysis to the endometrial cavity was performed with subsequent multiplanar image analysis and volume rendering.
- Measurements were taken as required.
- The data were analyzed.
- Polyps appeared as echogenic structures with pedicles protruding into the uterine cavity, the polyps were evaluated as regard the mean diameter, the site within the endometrial cavity, and the number.
- Submucous myomas appeared as well defined masses that project into or compressing the cavity from outside with no line of cleavage between the myoma and the endometrial surface and they were evaluated for the mean diameter, the number and the degree of encroachment on the uterine cavity.
- Uterine adhesions were seen as echogenic band or bands of variable thickness seen traversing the inside of the uterine cavity and connected to the inner surface of the endometrium. As to our knowledge, no sonographic classification of the severity of adhesions was done, we purposed a classification close to that given by the hysteroscopy and hystero salpingraphy, and adhesions were classified by hysterosonography into mild, moderate and severe. Mild uterine adhesions were defined as fine septa occupying less than 1/3 of the cavity, moderate adhesions were fine septa occupying less than 2/3 of the cavity or few thick septa, severe adhesions were numerous fine septa or thick septa occupying most of the uterine cavity and may cause agglutinated walls.

RESULTS:

- Among 250 female patients suffered from implantation failure on 2 consecutive cycles of IVF / ICSI and were subjected to 3D hysterosonography evaluation an day 8-10 of the non-stimulated cycle, uterine cavity abnormalities and abnormal endometrial thickness were detected in 116 patients with an estimated % 43 % of patients suffered from pregnancy failure(table 1).
- All patients except 10 patients, (8 patients with thin endometrium and 2 patients with large mixed mural-submucosal myomas) were subjected to hysteroscopy treatment and showed complete agreement between the findings of 3D hysterosonography and hysteroscopy.
- Normal endometrial cavity (Fig.1): should show no endocavitary masses or bands with no abnormal displacement from outside and regular smooth inner and outer surface.
- -Endometrial polyps (fig.2a,b) :- 13 cases were detected with endometrial polyps , among them 5 cases with polyps > 1.5 cm in mean diameter and 8 cases with polyps <1.5 cm in mean diameter and according to the site of polyps , 5 cases showed polyps arising at the posterior endometrial surface , 4 cases with polyps at uterotubal junction and 2 cases with polyps seen arising from the superior surface and 2 cases showed polyps at the lateral endometrial surface .
- Uterine myomas (Fig.3) :- 11 cases with uterine myomas casting distortion or bulging into the uterine cavity were observed , among them 6 submucous myomas <2 cm, 3 submucous myomas >2cm and 2 large myomas 5 cm , 4 cm in mean diameter of mixed mural- submucous type .
- Uterine adhesions (Fig.4 a, b):- 6 cases detected with uterine adhesions, among them 3 cases with mild adhesion, 2 cases with moderate adhesions, and a case with severe adhesions.
- Thin endometrium: - 8 cases showed thin endometrium less than 7 mm in thickness at day 8-10 of cycle.
- Abnormal endometrial pattern with thickness>7mm:- 5 cases showed an abnormal endometrial pattern with no triple line appearance
- Uterine anomalies: - 7 cases were detected with partial uterine septum, in 5 patients the septum was thick with detected vascularity inside and in 2 patients the septum was short and thin.

Table1: Number and % of cases detected with abnormalities in hysterosonography and their diagnosis.

Number	%	The Diagnosis
13	11.2 %	Polyps
11	9.4 %	Myomas
5	4.3 %	Thick endometrium
8	7 %	Thin endometrium
6	5.1 %	Uterine adhesions
7	6 %	Sub septate uterus
66	57 %	No detectable abnormality
116	100 %	

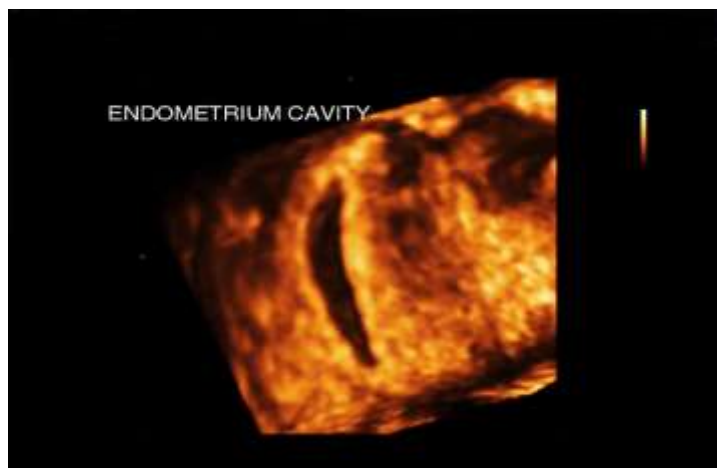


Fig.1: 3D hysterosonography with volume rendering of normal endometrial cavity

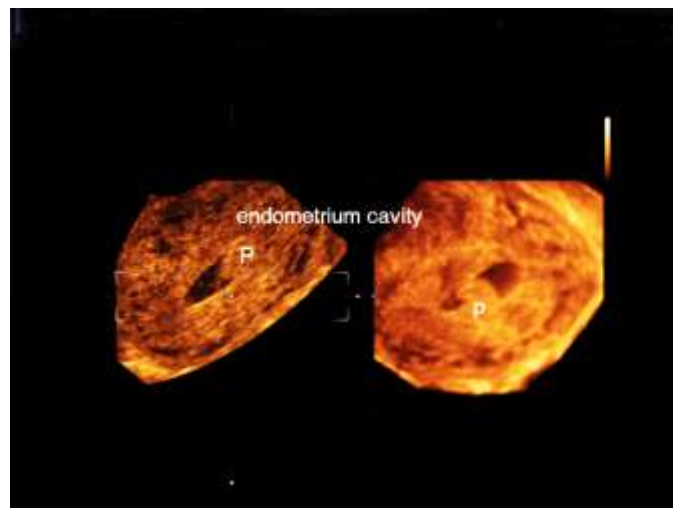


Fig.2a: 2D and 3D ultrasound surface rendering of small endometrial polyp.

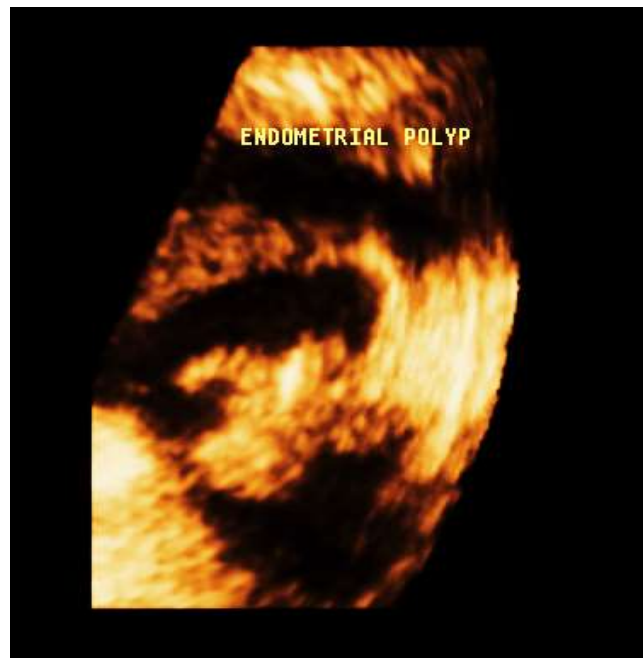

Fig.2b: 3D ultrasound surface rendering of large endometrial polyp

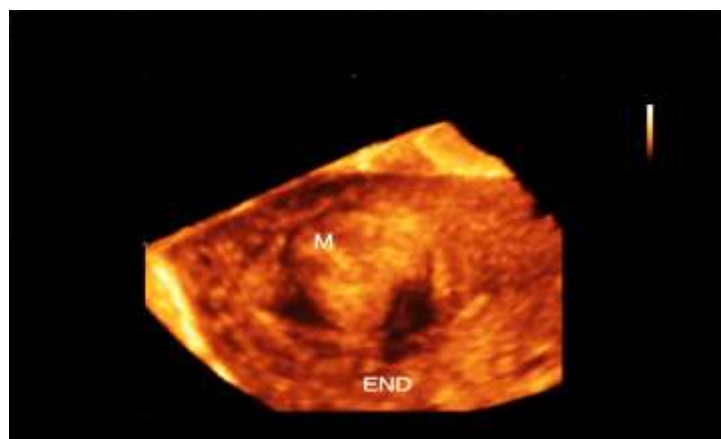


Fig.3: 3D ultrasound surface rendering of large submucosal myoma.

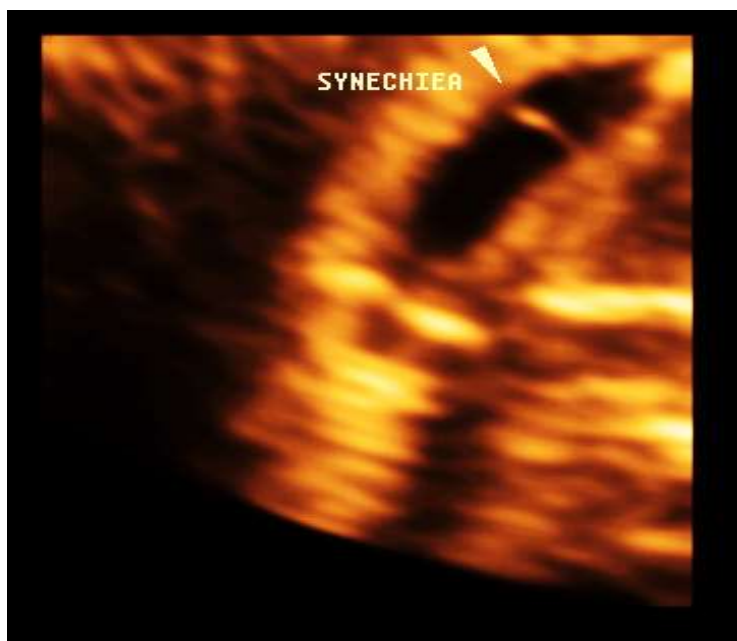


Fig.4a: 3D ultrasound surface rendering of mild endometrial cavity adhesions.

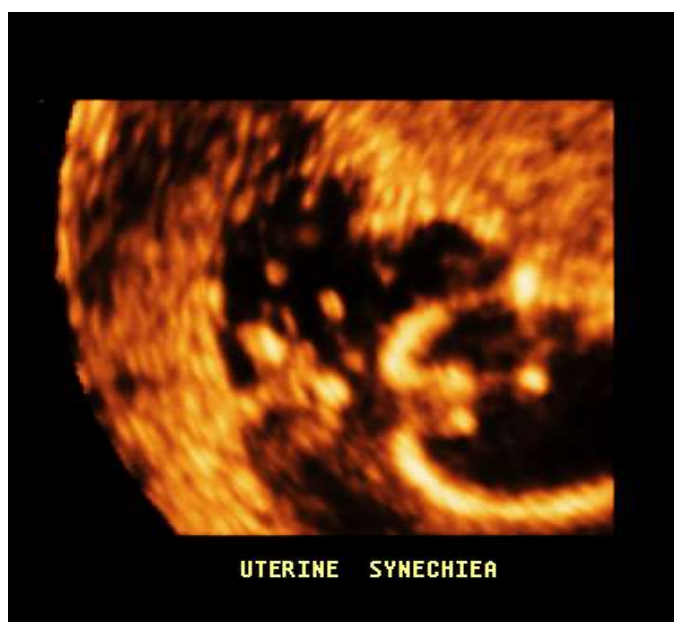

Fig.4b: 3D ultrasound surface rendering of severe endometrial cavity adhesions

DISCUSSION:

43% of our patients suffered from implantation failure were due to endometrial cavity abnormalities and abnormal endometrial thickness, both hysteroscopy and hysterosonography were used in diagnosing endometrial cavity abnormalities [8] however hysterosonography was easily available, of little cost, less invasive and less painful than hysteroscopy however hysteroscopy offers the advantage of taking biopsy and performing management in an outpatient sitting [9].

Many studies had compared the accuracy of both techniques and were found to have similar accuracy [8-11], what was in agreement with the current study. Among 43 of cases suffered from implantation failure in our current study, 11.2% were diagnosed with endometrial polyps .polyps< 1.5m were found In 8 out of 13 cases and >1.5 cm were found in 5 cases. Significant polyps are those larger than 1.5 cm in diameter, however smaller polyps had been linked up to implantation failure. Hysteroscopy polypectomy was found to increase the pregnancy rate and the living birth rate [12-14], however another study showed that small

polyps don't decrease the pregnancy rate but increase the miscarriage rate [15]. Polyps commonly observed at the posterior endometrial surface but polypectomy of those situated near the uterotubal junction (were 4 cases in our study) were found to increase the pregnancy rate, so not only the size of polyp important but also the location [16].

Polyps were associated with low levels of mid-secretory IGFBP-1 and glyodelin and both were increased after polypectomy. Which may explain why endometrial receptivity can be impaired in association with polyps [17]. 9.4 % of our patient were detected with myomas among them 9 with submucous myomas and 2 cases were presented with mixed mural submucous myomas > 4 cm, previous studies showed that submucous myomas and any myoma distorting the endometrial cavity were associated with significantly decreased pregnancy rate and were linked up to implantation failure and hysteroscopic removal of submucous myoma had significantly improved the pregnancy rate and the pregnancy outcome [18-20], mural myoma especially if > 4 cm had negative impact on the IVF outcome [21-23], and large subserous myoma > 7 cm were linked up to implantation failure [23]. However, small mural myomas < 4cm which doesn't distort the uterine cavity needs no surgical removal [24].

- 5.1 % of our cases (6 cases) were detected with uterine adhesions, 3 cases with mild adhesions, 2 cases with moderate adhesions and 1 case with severe adhesions. Adhesions may lead to implantation failure through endometrial damage subsequent of endometritis, extensive adhesions may lead to damage to the basal layer of endometrium [25].
- 6 % of our cases suffered implantation failure were diagnosed with uterine septum. Previous studies showed that partial uterine septum may lead to implantation failure and its hysteroscopy resection may lead to improve the pregnancy rate and pregnancy outcome [2-5]. In our current study 2 cases out of 7 cases with partial septum, the septum was thin and short. Transvaginal hysterosonography can be able to separate cases with a deep arcuate uterus from cases with small septum that recommend hysteroscopic resection.

The abnormal Endometrium pattern was found in 4.3 % of our patients and previous study showed that abnormal endometrium pattern with no triple line in the follicular phase was associated with low pregnancy rate and high miscarriage rate [26]. Thin endometrium was found in 7 % of our patients with implantation failure and measures to increase the endometrial thickness may improve the pregnancy rate in the absence of uterine adhesions. Increased endometrial receptivity through

local endometrial injury was found to double the pregnancy rate in patients with recurrent implantation failure, and increase the live birth rate [27-28].

Authors Opinion based on the above mentioned referenced data and the results of the current study which needs to be expanded on large scale of patients: Hysteroscopy when available is the preferred method for evaluating the endometrium cavity as it offers both complete diagnosis though imaging and taking biopsy and therapeutic capabilities in one sitting and the patient discomfort had been significantly reduced using the newly introduced hysteroscopy machines. however this well not alleviate the need for transvaginal ultrasound which offers evaluation of myometrium and the adnexal regions for the presence of any significant abnormalities.

In cases suffered from implantation failure in 2 consecutive cycles of IVF despite of the transfer of at least 3 good quality embryos with no maternal cause rather than uterine abnormalities. Endometrial polyps of any size should be removed if no other uterine abnormalities observed and if the mean diameter of polyp >1.5cm in the presence of other abnormality. Any myoma seen bulging or distorting the uterine cavity of whatever size. Mural myoma >4cm especially in young females and multiple variable sizes uterine myomata if they were the sole abnormality should be managed. Partial uterine septum whether thin or thick should undergo hysteroscopy resection. Thin endometrium < 7mm should be treated with measures that increase the endometrial thickness (hormonal or stem cells). The abnormal endometrial pattern may lead to implantation failure and its exact etiology is not known and needs further studies to confirm its value and to evaluate its pathogenesis. Endometrial cavity adhesions whether mild, moderate or severe should be resected to clean the cavity, measures to prevent the recurrence of adhesions and to restore the endometrial thickness should be taken.

CONCLUSION:

3D hysteronography is a valuable alternative tool to hysteroscopy in evaluating endometrial cavity abnormalities and abnormal endometrial thickness in patients suffered from recurrent implantation failure of in vitro fertilization cycles.

Conflict of interest: The author declares that he has no conflict interest.

Sources of Funding: not present

Informed Consent

All procedures performed were in accordance with the ethical standards of the responsible committee on human experimentation (institutional and national)

and with the Helsinki Declaration of 1975 (revised version of 2000) [5]. All patients provided written informed consent to the enrollment in the study and to the publication of information that could potentially lead to their identification

REFERENCES:

1. Osmanagaoglu K, Tournaye H, Camus M, Vandervorst M, Van Steirteghem A, Devroey P. Cumulative delivery rates after intracytoplasmic sperm injection: 5 year follow-up of 498 patients. *Human Reproduction*. 1999 Oct 1;14(10):2651-5.
2. Coughlan C, Ledger W, Wang Q, Liu F, Demirel A, Gurgan T, Cutting R, Ong K, Sallam H, Li TC. Recurrent implantation failure: definition and management. *Reproductive BioMedicine Online*. 2014 Jan 31; 28(1):14-38.
3. Margalioth EJ, Ben-Chetrit A, Gal M, Eldar-Geva T. Investigation and treatment of repeated implantation failure following IVF-ET. *Human reproduction*. 2006 Dec 1; 21(12):3036-43.
4. Bozdogan G, Aksan G, Esinler I, Yarali H. What is the role of office hysteroscopy in women with failed IVF cycles? *Reproductive biomedicine online*. 2008 Jan 1; 17(3):410-5.
5. Golan A, Ron-El R, Herman A, Soffer Y, Bukovsky I, Caspi E. Diagnostic hysteroscopy: its value in an in-vitro fertilization/embryo transfer unit. *Human Reproduction*. 1992 Nov 1; 7(10):1433-4.
6. Shalev J, Meizner I, Bar-Hava I, Dicker D, Mashiach R, Ben-Rafael Z. Predictive value of transvaginal sonography performed before routine diagnostic hysteroscopy for evaluation of infertility. *Fertility and sterility*. 2000 Feb 29; 73(2):412-7.
7. Hauge K, Flo K, Riedhart M, Granberg S. Can ultrasound-based investigations replace laparoscopy and hysteroscopy in infertility? *European Journal of Obstetrics & Gynecology and Reproductive Biology*. 2000 Sep 30; 92(1):167-70.
8. Kroon CD, Bock GH, Dieben SW, Jansen FW. Saline contrast hysterosonography in abnormal uterine bleeding: a systematic review and meta-analysis. *BJOG: An International Journal of Obstetrics & Gynaecology*. 2003 Oct 1; 110(10):938-47.
9. Heleen van Dongen, Anne Timmermans, Cathrien E. Jacobi. Diagnostic hysteroscopy and saline infusion sonography in the diagnosis of intrauterine abnormalities: an assessment of patient preference. *Gynecol Surg*. 2011 Feb; 8(1): 65-70.
10. Khan F, Jamaat S, Al-Jaroudi D. Saline infusion sonohysterography versus hysteroscopy for uterine cavity evaluation. *Annals of Saudi medicine*. 2011 Jul; 31(4):387.
11. Sconfienza LM, Lacelli F, Caldiera V, Perrone N, Piscopo F, Gandolfo N, Serafini G. Three-dimensional sonohysterography for examination of the uterine cavity in women with abnormal uterine bleeding: Preliminary findings. *Journal of ultrasound*. 2010 Mar 31; 13(1):16-21.
12. Pérez-Medina T, Bajo-Arenas J, Salazar F, Redondo T, Sanfrutos L, Alvarez P, Engels V. Endometrial polyps and their implication in the pregnancy rates of patients undergoing intrauterine insemination: a prospective, randomized study. *Human Reproduction*. 2005 Jun 1; 20(6):1632-5.
13. Kalampokas T, Tzanakaki D, Konidaris S, Iavazzo C, Kalampokas E, Gregoriou O. Endometrial polyps and their relationship in the pregnancy rates of patients undergoing intrauterine insemination. *Clinical and experimental obstetrics & gynecology*. 2011 Dec; 39(3):299-302.
14. Shokeir TA1, Shalan HM, El-Shafei MM. Significance of endometrial polyps detected hysteroscopically in eumenorrhic infertile women. *J ObstetGynaecol Res*. 2004 Apr; 30(2):84-9.
15. LassA1, Williams G, Abusheikha N, Brinsden P. The effect of endometrial polyps on outcomes of in vitro fertilization (IVF) cycles. *J Assist Reprod Genet*. 1999 Sep; 16(8):410-5.
16. Yanaihara A1, Yorimitsu T, Motoyama H, Iwasaki S, Kawamura T. Location of endometrial polyp and pregnancy rate in infertility patients. *Fertil Steril*. 2008 Jul; 90(1):180-2. Epub 2007 Sep 24.
17. Elbeheri MM, Nouh AA, Mohamed ML, Alanwar AA, Abd-Allah SH, Shalaby SM. Insulin-like growth factor binding protein-1 and glycodelin levels in uterine flushing before and after hysteroscopic polypectomy. *Clinical laboratory*. 2011 Jan 1; 57(11):953.
18. Pritts EA. Fibroids and infertility: a systematic review of the evidence. *Obstetrical & gynecological survey*. 2001 Aug 1; 56(8):483-91.
19. Eldar-Geva T, Meagher S, Healy DL, MacLachlan V, Breheny S, Wood C. Effect of intramural, subserosal, and submucosal uterine fibroids on the outcome of assisted reproductive technology treatment. *Fertility and sterility*. 1998 Oct 31; 70(4):687-91.
20. Donnez J, Jadoul P. What are the implications of myomas on fertility? A need for a debate?. *Human reproduction*. 2002 Jun 1; 17(6):1424-30.
21. Check JH, Choe JK, Lee G, Dietterich C. The effect on IVF outcome of small intramural fibroids not compressing the uterine cavity as determined by a prospective matched control study. *Human Reproduction*. 2002 May 1; 17(5):1244-8.
22. Hart R, Khalaf Y, Yeong CT, Seed P, Taylor A, Braude P. A prospective controlled study of the effect of intramural uterine fibroids on the outcome of assisted conception. *Human reproduction*. 2001 Nov 1; 16(11):2411-7.

23. Oliveira FG, Abdelmassih VG, Diamond MP, Dozortsev D, Melo NR, Abdelmassih R. Impact of subserosal and intramural uterine fibroids that do not distort the endometrial cavity on the outcome of in vitro fertilization–intracytoplasmic sperm injection. *Fertility and sterility*. 2004 Mar 31; 81(3):582-7.
24. Vimercati A, Scioscia M, Lorusso F, Laera AF, Lamanna G, Coluccia A, Bettocchi S, Selvaggi L, Depalo R. Do uterine fibroids affect IVF outcomes?. *Reproductive biomedicine online*. 2007 Jan 1; 15(6):686-91.
25. Conforti A, Alviggi C, Mollo A, De Placido G, Magos A. The management of Asherman syndrome: a review of literature. *Reproductive Biology and Endocrinology*. 2013 Dec 27; 11(1):118.
26. Chen SL, Wu FR, Luo C, Chen X, Shi XY, Zheng HY, Ni YP. Combined analysis of endometrial thickness and pattern in predicting outcome of in vitro fertilization and embryo transfer: a retrospective cohort study. *Reproductive Biology and Endocrinology*. 2010 Mar 24; 8(1):30.
27. Kovacs P, Matyas SZ, Boda K, Kaali SG. The effect of endometrial thickness on IVF/ICSI outcome. *Human Reproduction*. 2003 Nov 1; 18(11):2337-41.
28. Timeva T, Shterev A, Kyurkchiev S. Recurrent implantation failure: the role of the endometrium. *Journal of reproduction & infertility*. 2014 Oct 14; 15(4):173-83.