

Original Research Article

Role of Lateral Thoracic Flap for Reconstruction of Defects of Upper Limb (Peri Elbow Region)

Dr. N. Naga Prasad*¹, Dr. Palukuri Lakshmi**¹, Dr. Sreedharala Srinivasa Satyanarayana², Dr. Praveen Harish¹,
Dr. Baliram C¹

¹*Prof &HOD, ¹** Asso. Prof, ²Incharge Professor

¹Department of Plastic & Reconstructive Surgery, Osmania Medical College, Hyderabad, Telangana, India

²Department of Neurosurgery, Gandhi Medical College, Secunderabad, Telangana, India

*Corresponding author

Dr. Palukuri Lakshmi

Email: lakshmi_ahlad@yahoo.co.in

Abstract: Reconstruction of defects around elbow and upper arm is a challenging task for reconstructive plastic surgeon. Local tissues will not be adequate to cover the large defect. The lateral thoracic artery flap provides good skin cover for the defects of elbow and upper arm. The objective is to study the feasibility and therapeutic effect of lateral thoracic flaps for the defects of upper extremities (around elbow) This is a clinical, prospective study conducted between 2012 and 2014 at Osmania General Hospital / Osmania Medical College, Hyderabad. Ten cases with soft tissue defects in the upper extremities exposing bone were included in the study and re-constructed with lateral thoracic artery flap. In this study there were 250 patients with Upper limb defects with either trauma or burns as the causative factor admitted to the department of Plastic Surgery. Ten Peri-Elbow defects selected for this study constituted 4 % of Upper limb defects admitted to Plastic Surgery department. The mode of injury is due to electrical injuries in 8 cases (80%) and 2nd common cause is road traffic accidents in 2 cases (20%). All patients are male (100%) and belong to young and middle age group ranging from 8 years to 48 years. The most common site of defect is upper arm seen in four cases (40%) upper arm & elbow in 3 cases (30%) and elbow in 3 cases (30%). The lateral thoracic flap was used to reconstruct the defects of upper arm (upper, middle, lower third) involving antero-medial aspect in five cases and postero-lateral aspect in four cases & 3/4th circumference in one case. Anteriorly based lateral thoracic flap used in four cases and posteriorly based in four cases. Lateral thoraco epigastric flap used to reconstruct the elbow defects in two cases. The wounds healed well in all cases, except in one case which is used to cover the defect on the elbow developed partial necrosis which was debrided and covered with skin grafting. The lateral thoracic flap is a flexible alternative with good therapeutic results for covering the defects in the upper extremities, with a reliable blood supply, without any donor site morbidity.

Keywords: Lateral thoracic flaps, peri elbow defect, thoraco-dorsal flap, thoraco- epigastric flap

INTRODUCTION

Elbow joint is an important joint that allows working, playing and performing everyday activities. Elbow motion is essential for upper extremity function to position the hand in space. This is an important joint which supports the function of the upper limb depends upon the integrity and function of the related ligaments, tendons, muscles, joints and bones. Problems in any of these can affect upper extremity function – from the fingertips to the shoulder blades. The treatment of soft tissue problems about the elbow should be directed toward early coverage and functional rehabilitation to

prevent major disruptions at home and at work and negatively impacting quality of life.

Reconstruction of defects around elbow & upper arm is a challenging task for reconstructive plastic surgeon. Local tissues will not be adequate to cover the large defect. Fasciocutaneous flaps of local and regional areas were not adequate and available. Latissimus dorsi muscle flap provides good cover but is a major flap with donor muscle functional deficit. Hence, though it is a two-staged procedure, lateral thoracic flap provides good coverage to the upper arm and elbow defects without any functional deficit and

donor site of the flap in the hidden area of the body [23, 24].

AIM:

The aim of this study is to study the feasibility and therapeutic effect of lateral thoracic flaps for the defects of upper extremities (around elbow region).

OBJECTIVE:

To determine the feasibility, versatility and usefulness of Lateral thoracic flap cover. For Peri-Elbow defects. To understand the complications if any present. To assess the extent of restoration of range of elbow movements & the compliance of patients to this type of flap cover.

Literature review about Lateral Thoracic region as fascio cutaneous flap:

Jun Shi *et al.*; [2] conducted a study aimed to present surgical techniques and their experience in using free Lateral Thoracic cutaneous, myocutaneous and conjoint flaps for oral and maxillofacial reconstruction. Concluded that it is a reliable technique for reconstruction of maxillofacial defects with minimal donor site morbidity and favourable aesthetic outcomes.

Whereas Stephen J Mc Culley *et al.*; [3] have studied the Lateral Thoracic artery perforator (LTAP) flap as a valuable option from the lateral chest wall for partial breast reconstruction. Concluded that this flap is reliable and can be raised on its pedicle allowing greater mobilization in the use of the flap. Furthermore, Do yup Kim [4] and others had studied the Lateral thoracic artery perforator flap as a propeller flap for reconstruction of the chest wall for a radiation ulcer on the anterior chest.

Similarly, Wan-Lin-Teo [5] and others in their study titled Radical Surgical Excision and Use of Lateral Thoracic Flap for Intractable Axillary Hidradenitis Suppurativa have performed. The flap raised reached about 30 * 15 cm in dimensions. The flap was subjected to delay to enhance the survival of the periphery. This study concluded that with delay it could be raised to bigger dimensions which improved the quality of the patients.

In another study involving the Lateral thoracic region conducted by Baghaki [6] and others who have studied the Locoregional use of Lateral Thoracic Artery Perforator Flap as a Propeller Flap, In their case series, Lateral Thoracic artery flap was used for reconstruction as an islanded or propellar flap in Axilla, Pectoral

region and Arm. The range of motion of affected extremities returned to normal after reconstruction.

Similarly, Kim JT *et al.*; [7] studied using Lateral Thoracic perforator flap for defects in the head and neck region and lower limbs which resulted due to tumour extirpation, crush injuries and chronic wound with Osteomyelitis. The flaps were raised in a chimeric fashion and have concluded that Lateral thoracic region is a universal donor site. In an interesting study by Hui Chai Fong [8] and others to study for an appropriate recipient vessel in microsurgical breast reconstruction using deep inferior epigastric perforator flap – transverse rectus abdominis myocutaneous flap they found that the Lateral Thoracic vessels are useful alternative due to their central position and intraoperative exposure in a skin sparing mastectomy, the other usual alternatives being internal mammary and Thoracodorsal vessels.

Anatomy of the Lateral Trunk (Lateral Thoracic Region)

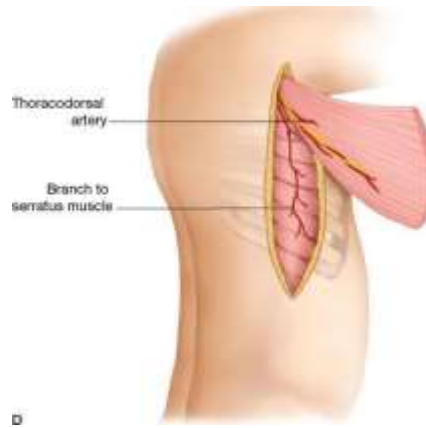
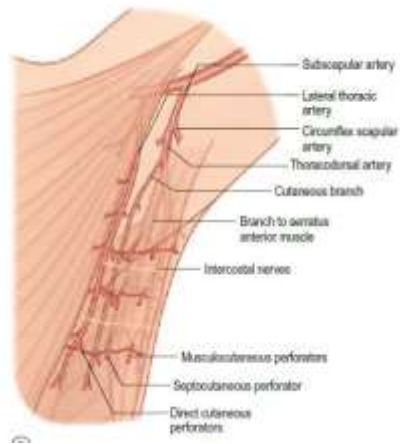This region extends from the mid scapular line to the anterior axillary line. Inferiorly it is bounded by the iliac crest. Down to the level of the fifth or sixth rib the skin is supplied by branches of the axillary artery, namely the Thoraco-dorsal and Lateral Thoracic vessels below this level by the Intercostal and Lumbar artery perforators. The skin of the axilla and lateral thoracic wall is supplied by perforators originating from three vessels, namely the Lateral thoracic, Thoracodorsal, and accessory lateral thoracic arteries. Cutaneous branches from the thoracodorsal and lateral thoracic artery were first mentioned by de Coninck *et al.*; and the flaps based on these arteries have been known as thoracodorsal skin flaps, thoracodorsal axillary flaps, and lateral thoracic flaps [9].

The Thoracodorsal Artery:

This arises where the subscapular artery divides, within 3 - 4 cms of its origin from the third part of the axillary artery, into thoracodorsal and circumflex scapular arteries. The Thoraco dorsal artery together with Thoraco dorsal nerve forms the principal neuro - vascular pedicle of the Latissimus dorsi muscle and the skin over the upper part of the muscle is supplied by musculocutaneous perforators arising from the branches of the artery. It is significant practical point that one of these branches lies in a constant position 2.5 cm behind the anterior border of the muscle and runs parallel to this free edge. Cutaneous branches of the Thoraco dorsal artery are crucial for the Lateral Thoracic flap in the study. The cutaneous supply is shared between The

Thoracodorsal artery and Serratus artery and Axillary

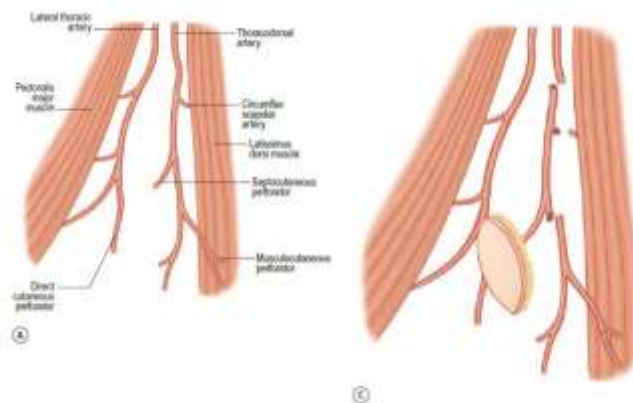
artery, their contribution varies in different individuals.



Anatomy of the lateral Thoracic flap:

A modified Type B fasciocutaneous flap can be safely raised in the lateral thoracic region due to its rich vascularisation. The anatomical territory of the lateral thoracic artery was demonstrated by Manchot [10] and Salmon [11], the dynamic territory of the vessel was mapped by Nakajima *et al.*; [12] and a free flap based on the lateral thoracic artery was used by Harii *et al.*; [13]. A dependable pedicled fasciocutaneous flap based on this and adjacent direct cutaneous vessels has not to date been used. This is a study on the fasciocutaneous pedicled flap either anterior based or posterior based raised from the Lateral Thoracic region which is uncommon in the international literature and would be one of the reliable and sturdy flaps. The vessels nearby include the thoraco dorsal artery, accessory lateral thoracic artery posteriorly and a pectoral branch of the acromino-thoracic axis anteriorly. Anatomy several small vessels originating from either the lateral thoracic vessels or the cutaneous branch of the thoracodorsal vessels supply this axial pattern island fasciocutaneous flap. Depending on the distance of

advancement or transposition, the vessels may be dissected more proximally, close to the branching from the major vessels, or even based on them. Baudet *et al.*; described the successful transfer of this flap as a free thoracodorsal axillary flap [14], but due to an in constant vessel supply this flap has not gained popularity as a free flap [15-18]. However, as a pedicled island flap, based on several branches, there is no concern about the origin of neighbouring vessels that arise from the axillary region to which the flap should be transferred. Between the lateral border of the pectoralis major anteriorly and the lateral border of the latissimus dorsi posteriorly lies a well-defined layer of deep fascia covering the serratus anterior and external oblique muscles which is known as the 'lateral thoracic fascia'. Lying superficial to this fascia and supplying it are multiple direct cutaneous perforators. The two most constant direct cutaneous perforators are from the thoracodorsal artery and the lateral thoracic artery. The lateral thoracic artery was less constant than the direct cutaneous branch of the thoraco dorsal artery [19]



Advantages:

Reduced donor site morbidity Controlled resurfacing with a thin flap. Various patterns and compositions can be harvested and used to reconstruct. Defects requiring different tissue arrangements and tissue types. Components of the flap can be arranged in the recipient site without restriction.

Disadvantages:

- **Initial temporary vascular insufficiency.** Initial temporary flow disturbance, including flap ischemia and flap congestion, has been observed.
- **Deviation of the breast.** In female patients, primary closure of the donor site may result in deformity of the breast with the thoracodorsal or lateral thoracic perforator flap; however, this can be released over time.

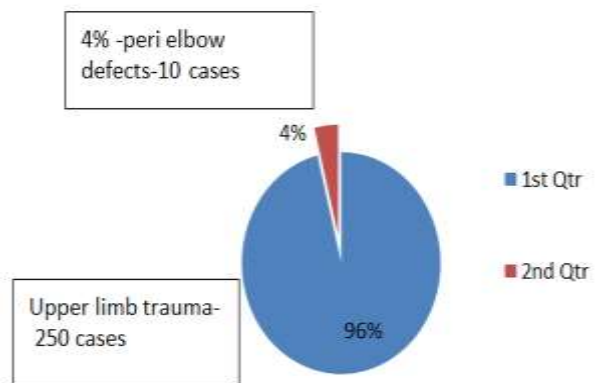
PATIENTS AND METHODS

This is a clinical, prospective study conducted between 2012 and 2014 at Osmania General Hospital/Osmania Medical College, Hyderabad. Ten cases with soft tissue defects in the upper extremities exposing bone were included in the study and reconstructed with lateral thoracic flap.

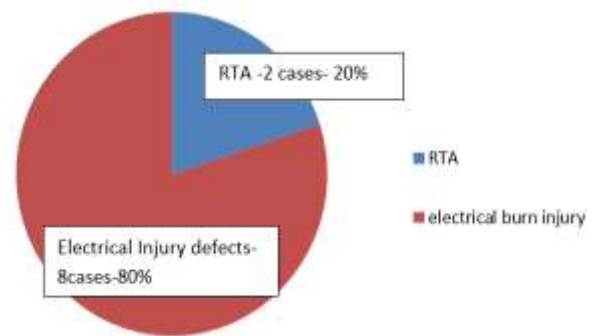
These were admitted to the plastic surgery Intensive Care Unit in the Department of Plastic Surgery. After adequate resuscitation and surgical workup of cases and anesthesia evaluation for fitness for surgery, the patients were taken up for surgical wound debridement and flap cover for the exposed bone or joint. Depending on the size, site, position of the soft tissue defect, the lateral thoracic flap or lateral thoracoepigastric flap was planned. Posterior lateral thoracic flap based on thoraco-dorsal artery perforators and subscapular artery perforators were performed for the defects on postero-lateral aspect of the upper arm and elbow. For antero-medial defects of the upper arm, direct cutaneous perforator, inter costal arteries-based anterior lateral thoracic flap was used. Thoraco-epigastric flap based on direct cutaneous perforators and epigastric system was used for covering the posterior and lateral defects of elbow region. After surgical debridement, defect size was measured and the flap was planned on the lateral thoracic region with 2:1 and 3:1 length-breadth ratio. The flap was raised in the subfascial plane and given inset to the defect keeping the defect near to the chest wall. Donor site of flap covered with split-thickness skin graft or closed primarily. Forearm and arm fixed to the chest wall with Elastoplast. Patients are discharged 1 week after flap surgery with advice to do breathing exercise and take

antibiotics and come for Stage 2 after 3–4 weeks. The flap was delayed and divided from the chest wall in the 2nd stage. Patients were advised to do physiotherapy to elbow, shoulder, and breathing exercises.

RESULTS



Pie chart -1: Magnitude of the problem



Pie chart -2: Etiology

Table – 1: Part involved

Part involved	No. of cases
Upper arm –middle or lower	4
Upper arm & elbow	3
Elbow region	3

Table- 2- Site of the defect

Site of defect	No. of cases
Anteromedial & anteolateral	5
Posteromedial & posterolateral	4
¾ th circumference	1

Table 3: Base of the lateral thoracic artery flap

Base of the flap	No. of cases
Anteriorly based LTF	6
Posteriorly based LTF	3

Table 4: demographic details of 10 cases reconstructed with lateral thoracic flap

S. NO	Subject No.	AGE/SEX	MODE OF INJURY	SITE OF DEFECT	SIZE OF THE DEFECT	FLAP	RECOVERY
1	Case-1	M/40	EBI	Antero-medial aspect of upper arm & elbow	12x 10cm	Anteriorly based LTF	GOOD
2	Case-2	M/30	EBI	Upper half of antero-medial aspect upper arm	10 x 8 cm	Anteriorly based LTF	GOOD
3	Case-3	M/48	EBI	Antero-Medial aspect of middle of upper arm	6x4 cm	Anteriorly based LTF	GOOD
4	Case-4	M/14	RTA	Antero-lateral aspect of elbow	7x4 cm	Anteriorly based LTF	GOOD
5	Case-9	M/9	EBI	Antero Medial aspect of middle of upper arm	9x7 cm	Posteriorly based LTF	GOOD
6	Case-5	M/26	EBI	Postero-lateral aspect of lower upper arm& elbow	7x5 cm	Thoraco-epigastric flap	GOOD
7	Case-7	M/20	RTA	Postero-lateral aspect of Elbow	6x4 cm	Thoraco-epigastric flap	Partial necrosis SSG →
8	Case-6	M/20	EBI	Postero-lateral aspect of middle of upper arm& elbow	6x4cm	Posteriorly based LTF	GOOD
9	Case-8	M/8	EBI	¾th Circumference defect of upper arm	8x 9 cm	Posteriorly based LTF	GOOD
10	Case-10	M/25	EBI	Postero lateral aspect of Elbow	5x4 cm	Posteriorly based LTF	GOOD

- EB- Electrical burn Injury
- RTA- Road Traffic Accident
- SSG- split thickness skin graft

Anatomical Basis of Flap and Coverage

Lateral thoracic flap is a fasciocutaneous flap which can be safely raised in the lateral thoracic region due to its rich vascularization. The multiple direct cutaneous perforators which supply this region were found to be fairly constant [19, 20]. The lateral thoracic flap is based at the level of the 3rd rib on multiple direct cutaneous perforators. It has an excellent vascularity with a dependable length/width ratio of 3:1. The donor area, which lies in a concealed region, can often be closed primarily. The flap is hairless and can be used to cover raw areas anteriorly over the breast and axilla and posteriorly over the scapula and chest wall. However, the skin over the lateral thoracic region is vascularized by three rows of perforators of varied vascular dominance. Two perforator flaps from this region based on the middle and the posterior row of perforators from the thoracodorsal artery have been described. The lateral thoracic perforator flap based on the anterior row of perforators is another useful option[21,22]. The

blood supply for posteriorly based lateral thoracic flap is perforators of thoracodorsal artery or subscapular artery and direct cutaneous perforators of intercostal or epigastric system when based anteriorly.

DISCUSSION

Elbow and peri-elbow wounds range from those caused by congenital anomalies, contracture release, tumour excision, and burns, to autoimmune disease, trauma, infection, and exposed prostheses [1]. The treatment of soft issue problems about the elbow should be directed toward early coverage and functional rehabilitation. They are often irregular with exposed nerves, tendons, bones/joint, and implants. Skin grafts, though possible in some cases, must be avoided, as it requires prolonged splintage and physiotherapy to prevent recurrence and elbow stiffness. Distant flaps require multiple stages, and free flaps are rarely indicated for elbow defects. Muscle flaps are bulky.

Each of these techniques has advantages as well as hazards and limitations. The ideal material for coverage of defects created should be thin, supple, large, healthy tissue with same texture, colour and thickness without the possibility of subsequent contracture, available in abundance and easy to harvest with least donor site morbidity.

Upper extremity reconstruction is very challenging due to the unavailability of expendable local muscles. This region is covered by thin and mobile tissues that respond to its increased mobility. Elbow and forearm wounds require a stable and durable solution. The wounds also have the unique requirement of a pliable, yet well-padded reconstruction. These characteristics promote early mobilization to prevent contracture and stiffness. As local tissues are frequently involved in the zone of injury or lack characteristics necessary to achieve an optimal outcome, the surgeon often must choose from the myriad of available flap options.

Local tissues will not be adequate to cover the large defect. Fasciocutaneous flaps of local and regional areas were not adequate and available. Latissimus dorsi muscle flap provides good cover but is a major flap with donor muscle functional deficit. Hence, though it is a two-staged procedure, lateral thoracic flap provides good coverage to the upper arm and elbow defects without any functional deficit and donor site of the flap in the hidden area of the body [23, 24].

Though the exact epidemiological statistics of this defect are not found in the literature, it has been one of the important defect which have been seen in our institute which needed a reliable and sturdy flap cover that would mimic the original tissue without the cumbersome and multiple staged either muscle flaps like Latismudorsi muscle flap or free flaps which increase the morbidity of the procedure.

In this study there were 250 patients with Upper limb defects with either trauma or burns as the causative factor admitted to the department of Plastic Surgery. Ten Peri-Elbow defects selected for this study constituted 4 % of Upper limb defects admitted in Plastic Surgery admissions in our department (Pie chart-1). The mode of injury is due to electrical injuries in 8 cases (80%) and 2nd common cause is road traffic accidents in 2 cases (20%) (Pie chart-2). All patients are male (100%) and belong to young and middle age group ranging from 8 years to 48 years.(table-4) The most common site of defect is upper arm seen in four cases

(40%) upper arm & elbow in 3 cases (30%) and elbow in 3 cases (30%).(table-1). Fig 1, 2, 3



Fig 1: upper arm defect

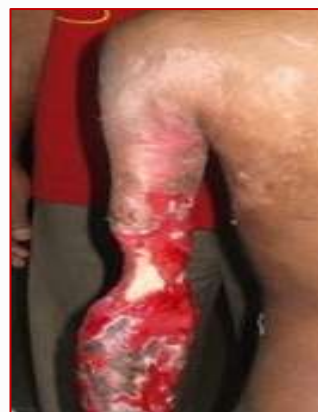

Fig 2: upper arm & elbow

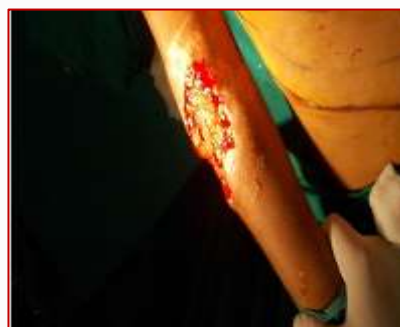

Fig 3: elbow defect

In all cases, the bone is exposed and surrounded by the raw area in all electrical burn patients (Fig 1, 2). The size of the defect ranging from 5 cm × 4 cm to 12 cm × 10 cm. The size of the flap ranging from 8 cm × 6 cm to 20 cm × 14 cm. In this study, lateral thoracic flap was used to reconstruct the defects of upper arm (upper, middle, lower third) involving

antero-medial aspect in five cases and postero-lateral aspect in four cases & 3/4th circumference in one case(table-2&3).[fig 1,2]. Anteriorly based lateral thoracic flap [fig.4] done four cases and posteriorly based in four cases. [Fig .5, 11, 12]Lateral thoraco epigastric flap [fig 13, 14] used to reconstruct the *elbow defects in two cases (table-3).

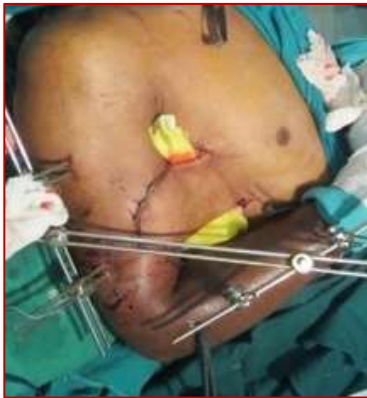

Fig 4: anteriorly based LTF

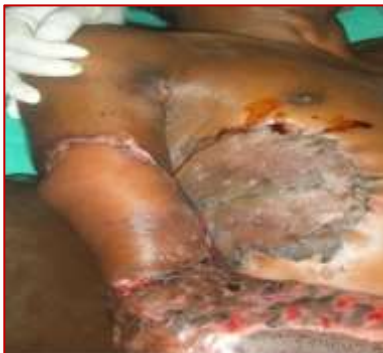

Fig 5: posteriorly based LTF

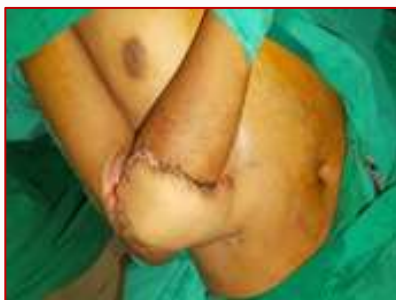

Fig 6: lateral thoraco epigastric flap

The wounds healed well in all cases, except in one case which is used to cover the defect on the elbow developed partial necrosis [Fig.7] which was debrided and covered with skin grafting [Fig.8].

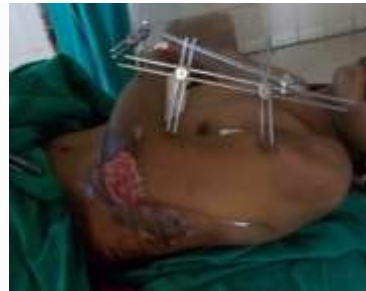

Fig 7: partial necrosis of Lateral thoracic flap

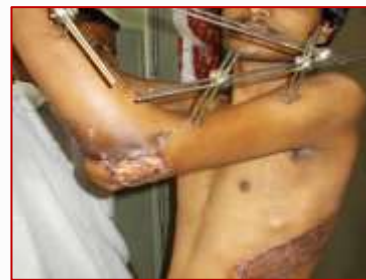

Fig 8: Post op debridement & ssg

Ninety percent of cases went well without any complication. Our results are similar to that of the study by Baghaki *et al.*; [6] All cases were taken up for delay and division of flap after 1 month, except one 8-year-old patient with electrical burns with 3/4th circumference defect of the middle of upper arm which we did 2nd stage after 2 months [fig 9&10].

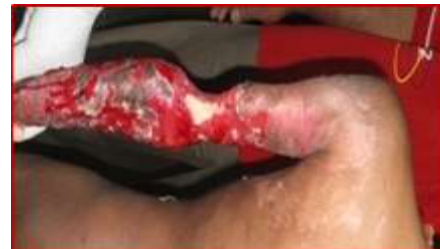

Fig 9: Pre op 3/4 th circumference defect of upper arm

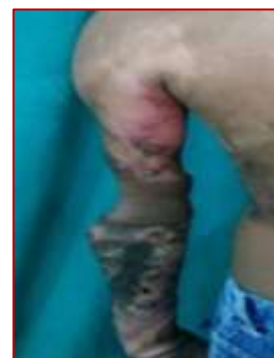

Fig 10: post op LTF

In all cases, wounds healed well. Cosmetic and functional recovery is good. Our results are similar to that of the study by Baghaki *et al.*; [6]. The color, texture, and thickness of the flaps were also satisfactory.



Fig 11: Pre op defect upper arm

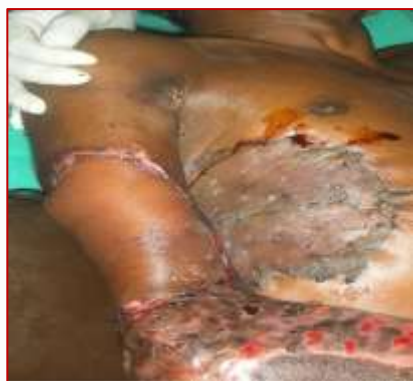

Fig 12: post op posteriorly based Lateral thoracic flap

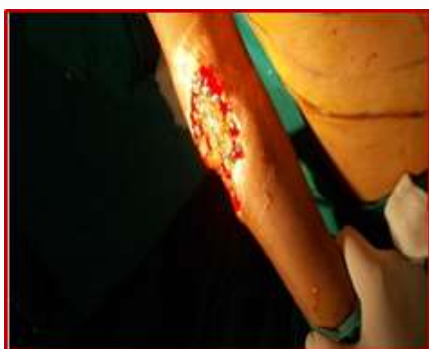

Fig 13: Pre op defect elbow

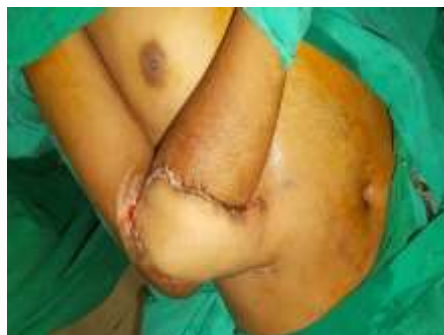

Fig 14: post op lateral thoraco epigastric flap

CONCLUSIONS:

This study concludes that Lateral thoracic artery flap is a reliable, sturdy, robust, versatile and supple cover for peri-elbow defects, with least donor site morbidity. Though the most common complication seen in few flaps was marginal necrosis which can be reduced by tension free inset and proper post-operative posture management and patient compliance. The functional & cosmetic recovery of elbow and upper limb is good.

Conflicts of Interest

There are no conflicts of interest.

ACKNOWLEDGEMENT

I express my sincere thanks to my post graduates, parents, Sons Ahlad. S, Ashish. K. My thanks to I thank computer operators Raju, Prashanth, Fahad for helping me in preparation of this paper

REFERENCES

1. Giele H. Soft tissue coverage around the elbow. Operative Elbow Surgery: Expert Consult. Churchill Livingstone. 2012:719.
2. Shi J, Xu B, Shen GF, Wang XD. Application of lateral thoracic flap in maxillofacial defect reconstruction: experience with 28 cases. Journal of Plastic, Reconstructive & Aesthetic Surgery. 2013 Oct 31; 66(10):1369-75.
3. McCulley SJ, Schaverien MV, Tan VK, Macmillan RD. Lateral thoracic artery perforator (LTAP) flap in partial breast reconstruction. Journal of Plastic, Reconstructive & Aesthetic Surgery. 2015 May 31; 68(5):686-91.
4. Kim DY, Kim HY, Han YS, Park JH. Chest wall reconstruction with a lateral thoracic artery perforator propeller flap for a radiation ulcer on the anterior chest. Journal of Plastic, Reconstructive & Aesthetic Surgery. 2013 Jan 31; 66(1):134-6.
5. Teo WL, Ong YS, Tan BK. Radical surgical excision and use of lateral thoracic flap for

- intractable axillary hidradenitis suppurativa. Archives of plastic surgery. 2012 Nov 1; 39(6):663-6.
6. Baghaki S, Cevirme M, Diyarbakirli M, Tatar C, Aydin Y. Locoregional use of lateral thoracic artery perforator flap as a propeller flap. Annals of plastic surgery. 2015 May 1; 74(5):532-5.
 7. Kim JT, Ng SW, Naidu S, Do Kim J, Kim YH. Lateral thoracic perforator flap: additional perforator flap option from the lateral thoracic region. Journal of Plastic, Reconstructive & Aesthetic Surgery. 2011 Dec 31;64(12):1596-602
 8. Fong HC, Goh T, Chui CH, Rasheed MZ, Ong YS. The Lateral Thoracic Vessels: A Useful Recipient in Immediate Breast Reconstruction. Journal of Reconstructive Microsurgery Open. 2016 Jul; 1(01):002-7.
 9. Wei, Fu-Chan. Flaps and Reconstructive Surgery. UK: SAUNDERS is an imprint of Elsevier Inc. 2009: 574- 580.
 10. Morain WD, Ristic J. The cutaneous arteries of the human body.
 11. Salmon M .Arteries de la peau. Masson, Paris, 1936.
 12. Nakajima H, Maruyama Y, Koda E. The definition of vascular skin territories with prostaglandin E1—the anterior chest, abdomen and thigh-inguinal region. British journal of plastic surgery. 1981 Jul 1; 34(3):258-63.
 13. Harii K, Tori S, Sekiguchi J. The free lateral thoracic flap. Plast Reconstr Surg 1978; 62:212-222
 14. Cormack GC, Lamberty BG. A classification of fascio-cutaneous flaps according to their patterns of vascularisation. British journal of plastic surgery. 1984 Jan 1; 37(1):80-7.
 15. Freeman JL, Walker EP, Wilson JS, Shaw HJ. The vascular anatomy of the pectorals major myocutaneous flap. British journal of plastic surgery. 1981 Jan 1; 34(1):3-10.
 16. Harii K, Torii S, Sekicuchi J. The free lateral thoracic flap. Plastic and reconstructive surgery. 1978 Aug 1; 62(2):212-22.
 17. Morain WD, Ristic J. The cutaneous arteries of the human body. 1983.
 18. Manhot C. Die Hautarterien des menschlichen Körpers. Vogel; 1889.
 19. Bhattacharya S, Bhagia SP, Bhatnagar SK, Chandra R. The lateral thoracic region flap. British journal of plastic surgery. 1990 Mar 1; 43(2):162-8.
 20. Bhattacharya S, Bhagia SP, Bhatnagar SK, Aabdi SM, Chandra R. The anatomical basis of the lateral thoracic flap. European Journal of Plastic Surgery. 1990 Nov 1; 13(6):238-40.
 21. Rowsell AR, Davies DM, Eizenberg N, Taylor GI. The anatomy of the subscapular-thoracodorsal arterial system: study of 100 cadaver dissections. British journal of plastic surgery. 1984 Oct 1; 37(4):574-6.
 22. Cormack GC, Lamberty BG. Lateral thoracic artery, superficial thoracic artery. In: The Arterial Anatomy of Skin Flaps. Edinburgh: Churchill Livingstone; 1994: 371.
 23. Busnardo FF, Coltro PS, Olivian MV, Busnardo AP, Ferreira MC. The thoracodorsal artery perforator flap in the treatment of axillary hidradenitis suppurativa: effect on preservation of arm abduction. Plastic and reconstructive surgery. 2011 Oct 1; 128(4):949-53.
 24. Sebastien C, Regnier M, Lantieri L, Pétoin S, Guérin-Surville H. Anterolateral thoracic fascia: an anatomic and surgical entity. Surgical and Radiologic Anatomy. 1993 Jun 1; 15(2):79-83.