

Original Research Article

A Clinicopathologic Study of Lichen Planus**Dr. Karumbaiah KP¹, Dr Arshiya Anjum², Dr Mallikarjun M³**¹Associate. Prof. of Pathology, Kodagu Institute of Medical Sciences, Madikeri, Karnataka, India²Consultant Pathologist, Cloudnine Hospital, Jayanagar, Bengaluru, Karnataka, India³Prof & Head, Dept. of Dermatology, K.V.G. Medical College, Sullia, D.K., Karnataka, India
Department of Pathology, K.V.G. Medical College, Sullia, D.K., Karnataka, India***Corresponding author**

Dr.K.P. Karumbaiah

Email: karumbaiahkp@yahoo.com

Abstract: Papulosquamous group of skin lesions have certain common clinical presentations and lead to confusion in diagnosis. We undertook this study to analyze the histomorphological findings of lichen planus, one of the most common and important Papulosquamous lesions of skin in detail, and to correlate the clinical findings with histomorphological features. Biopsy of clinically diagnosed/suspected cases of lichen planus lesions were performed in the department of dermatology and sent to the department of pathology in 10% formalin. The specimens obtained were subjected for tissue processing after fixation. Tissue sections are prepared from paraffin block and stained with haematoxylin and eosin, followed by microscopic examination. A total of 17 cases were studied. Lesions occurred in all age groups but were common in middle aged. Males were commonly affected. There is an overlap in morphology and distribution of these lesions leading to difficulty in diagnosis. Distinct histopathological features and clinical correlation gives a conclusive diagnosis. Specific histomorphological diagnosis is important to distinguish these lesions as the treatment and prognosis varies significantly from other lesions with similar clinical presentation.

Keywords: Papulosquamous lesions; Lichen Planus; Histopathology

INTRODUCTION

Lichen planus (Gk. Leichen, tree moss; L.planus, flat) [1] is a common inflammatory, Papulosquamous disorder of unknown aetiology, characterized by small flat topped, shiny, polygonal, violaceous papules that may coalesce into plaque [2]. Eruption similar to lichen planus are observed with certain drugs, heavy metals, photographic chemicals and apparently by certain systemic conditions [3,1,4].

Erasmus Wilson initially coined the term lichen planus in 1869 [5]. Wilson considered this to be the same disease as "Lichen ruber" previously described by Hebra. Wickham noted punctuations and striae atop the lesions that currently bear his name today (Wickham's striae). Lichen planus including the cutaneous form and oral lichen planus, is recognized as a chronic mucocutaneous inflammatory condition of the stratified squamous epithelia [6].

Lichen planus constitute about 1% of all new patient visits to the general dermatologist. Seen in all parts of the world [7]. The other common lesions included in Papulosquamous disease of skin include psoriasis, followed by pityriasis rosea, Para psoriasis, pityriasis rubra pilaris and lichen nitidus. Overlapping of clinical features is very common among these conditions and histopathological study is often conclusive in this group of conditions.

OBJECTIVES

1. To study the histomorphological findings of Lichen planus in detail.
2. To correlate the clinical findings with histomorphological features of Lichen planus.

METHODOLOGY

The study includes clinically diagnosed / suspected and untreated case Lichen planus attending the Department of Dermatology, K.V.G Medical College and Hospital, Sullia, D.K., Karnataka during a

period of 2 years. Biopsy of clinically diagnosed/suspected cases of lichen planus lesions were performed after obtaining brief history and detailed clinical examination and were sent for histopathologic study. Haematoxylin and eosin stained sections were studied for various histological features and analyzed.

RESULTS

Lichen planus may affect all ages and incidence is equal in both sexes but distinctly rare in children. In the present study of 17 cases of lichen

planus, 11(64.70%) were males and 6(35.29%) were females with a peak incidence corresponding to 31-40 years of age.

Violaceous flat topped papules and plaques were the commonest type of clinical patterns seen in lichen planus in this study (Figure.1&2). Most of the cases showed hypergranulosis, irregular acanthosis with saw toothed rete ridges, dermal band like infiltrate (Figure.3).

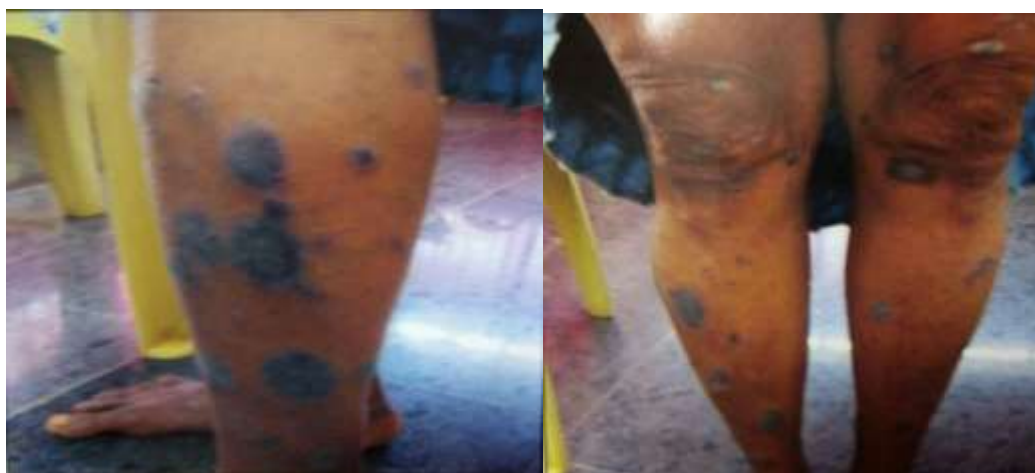

Fig 1&2: Photograph showing violaceous flat topped papules and plaques

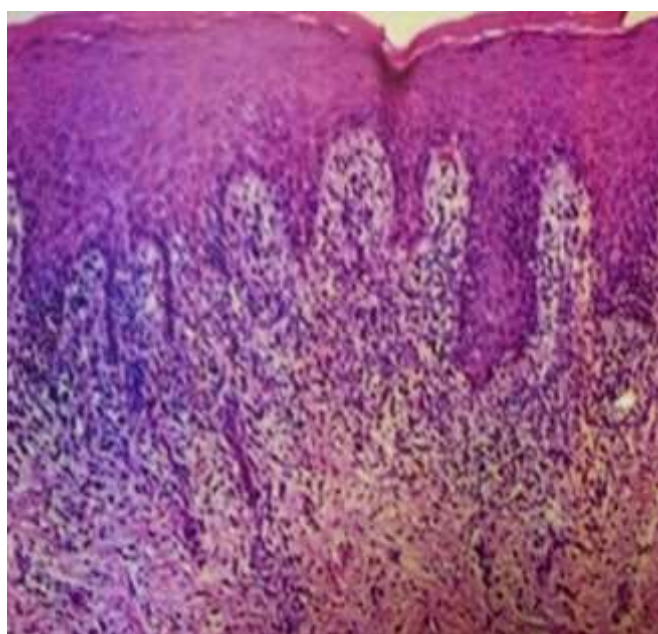


Fig 3: Hypergranulosis, irregular acanthosis with saw toothed rete ridges and dermal band like infiltration [Haematoxylin & Eosin, 10x]

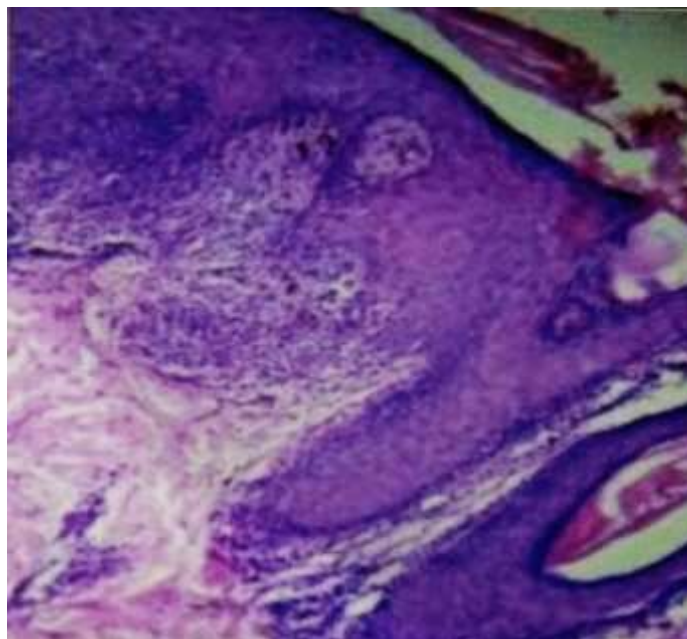


Fig 4: Max Joseph space [Haematoxylin & Eosin, 20x]

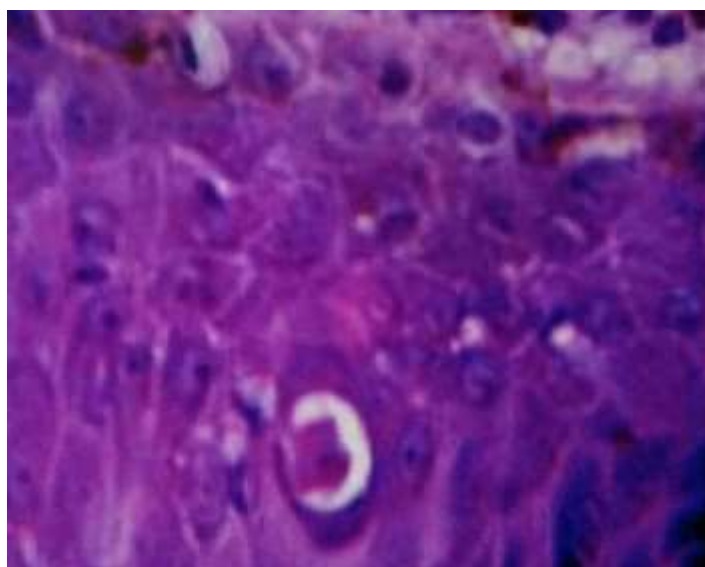


Fig 5: Civatte body [Haematoxylin & Eosin, 40x]

DISCUSSION

Lichen planus may affect all ages and incidence is equal in both sexes but distinctly rare in children [8]. Younas M and Haque A [8] in their analysis of 12 cases of lichen planus found 8(66.66%) to be males and 4(33.33%) females, which is similar to the present study which had 11(64.70%) and 6(35.29%) cases respectively.

Mogaddam MR, Anamzade F [9], found that lichen planus appears in men at a constant rate from the

early 20s through the 60s, whereas in women the rate of new cases continues to increase with increasing age, reaching a peak in the 60s. Rahnama Z, Esfandiarpour L, Farajzadeh S [10], reported most common incidence among the young and middle aged. The mean age of the patients was 39.7 years.

In the present study the age incidence was distributed almost equally from 21 to more than 60 years, with peak incidence corresponding to 31-40 years of age. Of total 17 cases, 31-40 years age group had

7(41.17%), 21-30 years and 41-50 years had 2(11.76%) cases each. The age group of 51-60 years and >60 years had 3(17.64%) cases each.

In the current study, the anatomical distribution of the lesions revealed that the legs (52.9%) were involved in the maximum number of cases (Figure.1), followed by arms (29.4%), trunk, back and presternum showed (5%) each (Table.1).

Table - 1: Clinical pattern in histopathologically diagnosed lichen planus

Serial no	Violaceous to erythematous	Plaque	Scaly plaque	Flat topped Papule/plaque	Scaly patches/macule	Verrucous nodule/plaque	Site
1	+	+	-	+	-	-	Arm
2	+	+	-	+	-	-	Leg
3	+	-	+	-	-	-	Arm
4	-	-	+	-	+	-	Arm
5	+	+	-	+	-	-	Leg
6	+	-	+	+	+	-	Leg
7	+	-	+	-	+	-	Arm
8	+	+	-	+	-	-	Presternum
9	+	-	-	+	-	-	Leg
10	+	-	+	-	+	-	Thigh
11	+	-	+	-	+	-	Trunk
12	+	-	+	-	+	-	Elbow
13	+	-	+	-	+	-	Back
14	+	+	-	+	-	-	Leg
15	+	+	-	+	+	-	Leg
16	+	-	-	+	-	-	Leg
17	+	+	+	+	-	-	Feet
Total=	16	7	9	10	8	-	

Table 2: Histological changes observed in lichen planus

Histological Changes	No. of cases	Percentage
Epidermal changes		
Hyperkeratosis	17	100
Focal Parakeratosis	2	11.76
Irregular acanthosis with saw toothed rete ridges	13	76.47
Hypergranulosis	13	76.47
Vacuolar degeneration of basal cells	17	100
Max Joseph spaces	4	23.52
Civatte bodies	2	11.76
Dermal changes		
Dermal infiltrate		
-Band like	14	82.36
-Spotty	3	17.64
Cell type of infiltrate		
-Mononuclear	17	100
-Epithelioid		

Sigurgeirsson B and Lindelof B [11], in their study found most of the lesions were located below the knee (69%), which is comparable with the present

study. Younas M and Haque A [8] found itchy, raised flat topped to raised crusty erythematous and violaceous

papules over anterior surfaces of legs, forearms, chest, trunk, axillae and neck.

Histomorphological examination in the present study of 17 cases (Table.2) of classical lichen planus, the epidermal changes showed hyperkeratosis and vacuolar degeneration of basal cells in all the cases (100%). 76.47% cases showed irregular acanthosis, with saw toothed ridges and hyper granulositis (Figure.3). Max Joseph spaces were found in 23.52% cases (Figure.4). 11.76% cases showed focal parakeratosis and Civatte bodies (Figure.5). The dermal changes showed band like mononuclear cell infiltrate in 82.36% cases and spotty infiltrate in 17.64% cases.

These findings are consistent with the classic description of lichen planus given by Mobini *et al.*; in 2005 [11] and also comparable with the similar study conducted by Younas M and Haque A [8]. Younas M and Haque A [8] reported that the special variants include drug induced lichenoid reactions and lichen planus - lupus erythematosus overlap.

In the current study of 17 cases of lichen planus, 8 were clinically diagnosed and confirmed by histopathology. Two cases had clinical diagnosis of psoriasis and eczema, which under histopathological study were lichen planus. In 2 cases lichen planus was in the differential diagnosis along with lichenoid drug eruptions, and 3 cases had a differential diagnosis of psoriasis with lichen planus and 1 case each had a differential diagnosis of lichen amyloidosis and lichen planus pigmentosus.

CONCLUSION

There is an overlap of both clinical pattern and distribution of lesions of Lichen planus, one of the most common Papulosquamous skin disorders, which often makes clinical diagnosis difficult. Recognition of these commonly encountered cutaneous problems depends upon the familiarity of clinical presentation and the diagnosis can be confirmed with histopathology. The pathologist's ability to render an accurate diagnosis depends on the available clinical information. Biopsy specimens of these lesions submitted for histopathology with clinical information & differential diagnosis and a clinico-pathological correlation is key to better patient care.

REFERENCES:

1. McNutt NS, Smoller BR, Contreras F. Skin. In: Damjanov I, Linder J, editors. Anderson's pathology. 10th ed. St.Louis: Mosby; 1996: 2416-23
2. Mobini N, Toussaint S, Kamino H. Non-infectious erythematous papular and squamous disorders. In: Elder DE, Elenitsas R, Johnson Ir. BL, Murphy GF, editors. Lever's histopathology of skin. 9th ed. Philadelphia : Lippincott Williams and Wilkins; 2005: 179-214
3. Lewis GM, Wheeler Jr. CE. The maculo Papulosquamous diseases. In: Practical dermatology. 3rd ed. Philadelphia: W.B. Saunders Company; 1967: 207-30
4. Krasowska D, Kozłowicz K, Kowal M, Kurylcio A, Budzynska-Włodarczyk J, Polkowski W, Chodorowska G. Twice malignant transformation of hypertrophic lichen planus. Annals of Agricultural and Environmental Medicine. 2012; 19(4).
5. Boyd AS, Neldner KH. Lichen planus. Journal of the American Academy of Dermatology. 1991 Oct 1; 25(4):593-619.
6. Rhodes NL, Meyers S, Kaimal S. Diagnosis and management of Oral Lichen Planus. Journal of Minnesota Dental Association (Internet Journal) 2003; 82(2) (accessed on 08-09-2013) available from; URL: http://www.mndental.org/archive/march/features/article_2
7. Daoud MS, Pittelkow MR. Lichen planus. In:Freedberg IM, Eisen AZ, Wolff K, Austen KF, Goldsmith LA, Katz SI. Fitzpatrick's dermatology in general medicine. 6th Ed. New York: McGraw Hill; 2003: 463-77
8. Younas M, Haque A. Spectrum of histopathological features in non-infectious erythematous and Papulosquamous diseases. Int J Pathol. 2004; 2(1):24-30.
9. Mogaddam MR, Anamzade F. Survey of relationship between hepatitis C and lichen planus among dermatology outpatients of Imam Hospital of Ardabil city. Journal of Pakistan Association of Dermatology. 2016 Dec 21; 20(1):19-22.
10. Rahnama Z, Esfandiarpour I, Farajzadeh S. The relationship between lichen planus and hepatitis C in dermatology outpatients in Kerman, Iran. International Journal of dermatology. 2005 Sep 1; 44(9):746-8.
11. Sigurgeirsson B, Lindelöf B. Lichen planus and malignancy: an epidemiologic study of 2071 patients and a review of the literature. Archives of dermatology. 1991 Nov 1; 127(11):1684-8.