

Original Research Article

Diagnostic yield and efficacy of FNAC in peripheral lung cancersSandeep Jadhav¹, P Ramesh²^{1,2}Assistant Professor, Department of Pulmonary Medicine, Rajiv Gandhi Institute of Medical Sciences (RIMS), Adilabad***Corresponding author**

Dr Sandeep Jadhav

Email: drsandeepdas@gmail.com

Abstract: Fine needle cytology is a well-established method of diagnosing neoplastic as well as inflammatory conditions of the lung. It has resulted in decrease need of other procedures that are generally more invasive for diagnosis. In this study we tried to evaluate the role of percutaneous fine needle aspiration cytology in suspected peripheral pulmonary cancers and determine the sensitivity and specificity of FNAC to diagnose lung cancers. A total of 52 patients admitted to Chest and tuberculosis ward of Siddhartha Medical College and Govt Hospital Vijayawada were selected. A CT guided percutaneous fine needle aspiration was performed if the lesion was solid and satisfied inclusion criteria. The aspirated material was spread on standard microscopic slides. The slides were stained by Leishman's stain and Haematoxyline and Eosin stain and viewed in high power. Out of the 52 patients 39 (75%) were male and 13 (25%) were female. 42 (80%) of the cases were found to be with malignancy and 10 were determined to be non-malignant. From 42 malignant cases 38 (90.4%) had history of smoking. Most common side of the lung involved was left side 27 (64%) of 42 cases of malignancy. Squamous cell carcinoma was diagnosed in 25 (48.07%) of the cases and other malignant lesions were Adenocarcinoma 14 (26.92%), small cell carcinoma 2 (3.9%) and metastatic in 1 (1.9%). Nonmalignant lesions were found in 5 (9.6%) Diagnosis was inconclusive in 5 (9.6%) of 52 cases. FNAC is generally a well-tolerated procedure with less morbidity and negligible mortality. It is acceptable, simple as well as useful it can be done without need of anesthesia and the results may be obtained within few hours. Use of CT guided FNAC enhances the diagnostic yield of the fine needle aspiration cytology. It lessens the need for other procedures like Fiber Optic Bronchoscopy [FOB] and cutting biopsy.

Keywords: Diagnosis, FNAC, Peripheral Lung Cancers**INTRODUCTION**

Lung cancer is one of the most common cancers and one of the important causes of cancer related deaths all over the world. It accounts for 13% of all new cancer cases and 19% of all cancer related deaths worldwide. About 1.8 million new lung cancer cases have been estimated to have occurred by 2012 [1]. In India lung cancer constitutes 6.9% of all new cancer cases and 9.3% of all cancer related deaths in both sexes. The trends of lung cancer show significant rise in metros like Delhi, Chennai and Bengaluru in both sexes [2]. The peak incidence of lung cancer is seen in between 55-65 years. The most common etiology of lung cancer is smoking and the incidences of lung cancer are now increasing in females with increase in incidence of smoking and changing life styles. The overall 5 year survival rate of lung cancer is 15% in

developed countries and 5% in developing countries [3]. This high risk of mortality makes early diagnosis and treatment essential for survival. [4, 5] Non-small cell lung cancer account for about 80-85% of all lung cancers and is classified according to WHO criteria into three major types: adenocarcinoma, (50%) squamous cell carcinoma (30-35%) and large cell carcinoma (5-10%) [6]. percutaneous fine needle aspiration cytology is the first line of procedure in diagnosis of radiographically demonstrable lung lesions [8, 9]. FNAC is very useful in diagnosing lung lesions that are small and peripherally located in lungs. The FNAC may sometimes cause complications like pneumothorax but methods of effectively dealing with such complications and accuracy of FNAC has got it wide acceptance among radiologists and pathologists [10-13]. The doubt of neoplastic cells getting implanted in the

needle track has been proven wrong [14]. The transthoracic fine needle aspiration cytology is helpful for diagnosis of lung lesions of both infective nature as well suspected malignant lesions particularly when other noninvasive cytological method like sputum cytology fails to yield diagnostic material. All intrathoracic lesions are now routinely and safely sampled by using FNAC under Computerized Tomography [CT] guidance [15-18]. This study was under taken to evaluate the diagnostic yield and efficacy of FNAC in peripheral lung lesions.

MATERIALS AND METHODS

This study was undertaken in Department of Tuberculosis and Chest Diseases, Siddhartha Medical college/Govt Hospital, Vijayawada. Institutional Ethical committee permission was obtained and written consent was taken from the participants of the study after duly explaining the procedure and its expected outcomes. The patients were evaluated by taking complete history followed by clinical examination and Lab tests like complete blood picture with BT and CT. Chest radiographs for PA view and lateral view were obtained. The patients were subjected to Computerized Tomography [CT] scan chest the patients found to have demonstrable radiographic intrathoracic lesions and a strong clinical suspicion of lung cancer, sputum for AFB was negative and cases not amenable to bronchoscopy were selected. Patients with pulmonary hypertension suspected vascular lesions, bleeding disorders and severe emphysema and bullous changes within the region of lung to be biopsied were excluded from this study.

Ct was done before the FNAC to measure the density of the lesion and planning of the biopsy is done

thoroughly studying the axial, sagittal and coronal sections of CT chest and the exact site and depth of the lesion from the skin identified. The site is marked and skin is prepared with aseptic precautions. A disposable 22G needle attached to 20 CC syringe is used. The patients are asked to hold breath and under the CT guidance needle inserted into the lesion. Aspiration is accomplished by creating a vacuum in the needle by drawing the plunger of the syringe. Vacuum was created by pulling plunger to 1ml mark after the needle entered the lesion and needle was moved in and out motions several times within the lesion while suction being applied. Before needle is withdrawn from the lesion suction was released. After the needle removed from the patient the needle and syringe are separated and material from the needle is spread on standard microscopic slide. Few slides were air-dried while other slides were fixed for 20 minutes in a jar (Coplin's Jar) containing methanol. Later methanol fixed slides were dried and all the slides were sent for cytological evaluation. The air dried slides were stained by Leishman's stain and methanol fixed slides were stained by Haematoxylin and Eosin stains and slides examined in high power microscope. Facility for underwater seal was made available for management of patients who develop pneumothorax.

RESULTS

The table 1 shows the characteristics of patients included in the study. The mean age of the patients included in the study was 52 years. The most common age group affected was 41-50 yrs contributing 24(46.1%) of patients, followed by 51-60 yrs age group 14 (26.9%) of the patients. Of the total 52 patients 39 were male and 13 were female giving a male to female ratio of 3:1.

Table 1: Demographic profile of patients involved in the study

Age Group (yrs)	Number of Patients		Total/Percentage
	Male	Female	
21 – 30	1	1	2 (3.8)
31 – 40	5	2	7 (13.4)
41 – 50	19	5	24 (46.1)
51 – 60	10	4	14 (26.9)
61 – 70	4	1	5 (9.5)
Total	39	13	52(100)

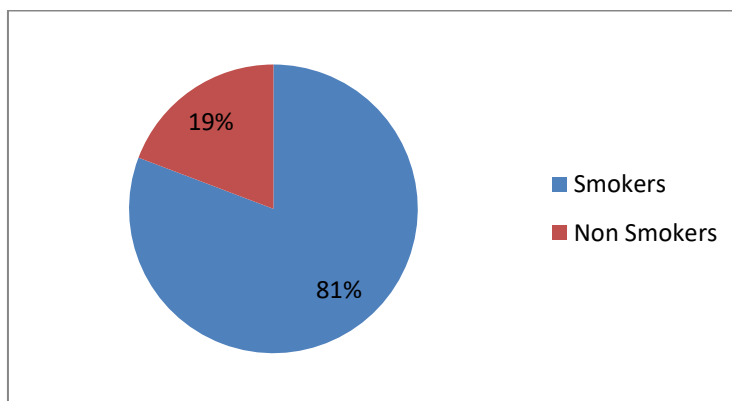


Fig 1: History of the patients involved in the study

In this study it was found that 42 (80.77%) of patients were smokers and malignancy was diagnosed in 38 patients who had history of smoking only 4 nonsmokers were diagnosed with malignancy. The p

values calculated were <0.05 indicating significance and smoking is an important etiological in lung malignancies. See table 2.

Table 2: Diagnosis of cases with history of smoking and correlation

Results	Smoking	Non Smoking	Total/percentage	P value
Malignancy	38	4	42 (80)	p = <0.05 *
Non-Malignancy	4	6	10 (20)	
Grand Total	42	10	52 (100)	

* Significant

The predominant clinical symptom given by the patient was cough found in 82.7% of the patients followed by shortness of breath [SOB] in 80.7 and the other presenting symptoms were weight loss in 75% of the individuals, chest pain 50% of individuals and fever in 30% of the patients. In general examination the

common findings were anaemia in 63.4% of patients followed by clubbing in 38.4% of cases. Associated radiological findings were presence of Hilar lymphadenopathy, diaphragmatic elevation and rib erosion.

Table 3: Clinical symptoms involved in the study

Symptoms	No. of Patients	Percentage
Cough	43	82.7
SOB	42	80.7
Hemoptysis	13	25
Chest pain	26	50
fever	16	30
Weight loss	39	75

The common side involved in the present study was left side of the lung in 32 (61.53%) of cases, right side was involved in 38.47% of cases of the 42 malignant cases 15 cases involved the right side and 27

cases involved the left side of the lung. The non-malignant cases 2 were involved on the right and 3 were having left sided lesions. See table 4.

Table 4: Correlation of Diagnosis with sides involved

Diagnosis	Right	Left	Total/percentage	P value
Malignancy	15	27	42 (80.77)	> 0.8 (NS)
Non Malignancy	2	3	5 (9.61)	
Inconclusive	3	2	5 (9.61)	
Total	20	32	52 (100)	

The cytopathological diagnosis showed the most common malignancy was squamous cell carcinoma in 25 (48.07%) of cases followed by adenocarcinoma in 14 (26.92%) of cases, small cell carcinoma was found in 2 (3.9%) of cases and 5 (9.6%)

each were detected as non-neoplastic and inconclusive diagnosis. One case of metastatic carcinoma was also found in a female patient with the primary located in the breast.

Table 5: Cytopathological diagnosis of the cases involved

Diagnosis	No. of patients	percentage
Squamous cell carcinoma	25	48.07
Adenocarcinoma	14	26.92
Small cell carcinoma	2	3.9
Metastatic carcinoma	1	1.9
Non- Neoplastic	5	9.6
Inconclusive	5	9.6

DISCUSSION

The study was designed to evaluate the diagnostic yield and efficiency of the FNAC in diagnosing suspected lung cancer cases. In the study the male: female ratio was 3:1 for lung pathologies, which is in agreement with Saha *et al.*; [19]. 42 (80.77%) of the patients involved in the study were smokers among them 3 females were having smoking history, the p value (<0.05) which indicate there is a substantial risk of smoking for the etiology of malignancy. In one study by D Behra studied that in addition to smoking occupational exposure to carcinogens and indoor air pollution and dietary factors were implicated in Etiology of lung cancer [20]. Jung KJ *et al.*; studying the role of tobacco in various ethnic races found a significantly greater risk of lung cancer was present among current smokers in Asian countries, the RRs in Asian countries were much lower than those reported in Western countries (range, 9.4 to 23.2). Possible explanations for the smoking paradox included epidemiologic characteristics, such as the smoking amount, age at smoking initiation, and the use of filtered or mild tobacco [21].

Highest number of cases involved in this study was 41-50 years of age group 46.1%, one study by KB Gupta *et al.*; found that most common age group involved was between 41-70 yrs. Right lung was involved in 69.4% of cases however in our study we

found 64.29% of malignant cases involved left side of the lung. In a similar study by SK Jindal *et al* studying 336 patients with bronchogenic carcinoma of lung in Chandigarh Peak frequency was found between age 51-60 years [22]. The differences with our study could be because of our small sample size. In this study the diagnostic yield of FNAC was 90.3% compared with other studies where the transthoracic fine needle aspiration cytology yielded 80-97% [19, 25]. The major clinical presenting symptom was cough in 43 (82.7%) of the patients. Signs of breathlessness, chest pain, hemoptysis, fever and hoarseness of voice were found in decreasing order of frequency. In this study we found that 5 (10%) out of total 52 cases the diagnosis was inconclusive and other diagnostic methods had to be used. Mondal SK *et al* found that the sensitivity of FNAC in patients using 22G needle as 88.4% [26]. M Madan *et al.*; studying diagnostic efficacy of image guided FNAC in various lung lesions found that the diagnostic accuracy was 95% and complications were recorded in 2.5% of cases [27]. In our study we had 3 (5.7%) out of total 52 complication leading to pneumothorax which were successfully managed. In this study we found most common diagnosis was squamous cell 25(48.07%) and Adenocarcinoma in 14 (26.92%) of cases, similar findings were by Saha *et al* studying 57 cases by CT guided FNAC found Squamous cell carcinoma in 42.6% of cases followed by Adenocarcinoma in 29.6% of cases [19].

CONCLUSIONS

FNAC is generally a well-tolerated procedure with less morbidity and negligible mortality. It is acceptable, simple as well as useful it can be done without need of anesthesia and the results can be obtained within few hours. Use of CT guided FNAC enhances the diagnostic yield of the fine needle aspiration by visualization of previously inaccessible tumors. The diagnostic yields of FNAC are within acceptable limits, it lessens the need for other procedures like Fiber Optic Bronchoscopy [FOB] and cutting biopsy.

Conflict of interest: None

Source of support: Nil

Ethical Permission: Obtained

REFERENCES

1. Ferlay J, Soerjomataram I, Ervik M, Dikshit R, Eser S, Mathers C, et al. Lyon, France: International Agency for Research on Cancer; 2013. GLOBOCAN 2012. Cancer Incidence and Mortality Worldwide: IARC Cancer Base No. 11. Available from: <http://globocan.iarc.fr> [accessed on 20/2/2017].
2. Indian Council of Medical Research; 2013. National Cancer Registry Program. Three Year Report of Population Based Cancer Registries: 2009-2011. Available from: <http://www.ncrpindia.org>. [Accessed on 25/2/2017].
3. Parkin DM, Bray F, Ferlay J, Pisani P. Global cancer statistics, 2002. CA: a cancer journal for clinicians. 2005 Mar 1; 55(2):74-108.
4. Travis WD, Brambilla E, Riely GJ. New pathologic classification of lung cancer: relevance for clinical practice and clinical trials. Journal of Clinical Oncology. 2013 Feb 11; 31(8):992-1001.
5. Thunnissen E, Bubendorf L, Dietel M, Elmberger G, Kerr K, Lopez-Rios F, Moch H, Olszewski W, Pauwels P, Penault-Llorca F, Rossi G. EML4-ALK testing in non-small cell carcinomas of the lung: a review with recommendations. Virchows Archiv. 2012 Sep 1; 461(3):245-57.
6. Travis WD, Harris CC. Pathology and genetics of tumours of the lung, pleura, thymus and heart. Feance: IARC Press, 2004; 2004 Sep 20.
7. Iwasaki A, Kamihara Y, Yoneda S, Kawahara K, Shirakusa T. Video-assisted thoracic needle aspiration cytology for malignancy of the peripheral lung. The Thoracic and cardiovascular surgeon. 2003 Apr; 51(02):89-92.
8. Kim HK, Shin BK, Cho SJ, Moon JS, Kim MK, Kim CY, Park SH, Kim KT, In KH, Oh YH, Kang EY. Transthoracic fine needle aspiration and core biopsy of pulmonary lesions. A study of 296 patients. Acta cytologica. 2001 Dec; 46(6):1061-8.
9. Gullon JA, Fernandez R, Medina A, Rubinos G, Suárez I, Ramos C, González IJ. Transbronchial needle aspiration in bronchogenic carcinoma with visible lesions: diagnostic yield and cost. Archivos de Bronconeumologia. 2003 Nov 1; 39(11):496-500.
10. Traill ZC, Gleeson FV. Delayed pneumothorax after CT-guided percutaneous fine needle aspiration lung biopsy. Thorax. 1997 Jun 1; 52(6):581-2.
11. Byrd Jr RP, Fields-Ossorio C, Roy TM. Delayed chest radiographs and the diagnosis of pneumothorax following CT-guided fine needle aspiration of pulmonary lesions. Respiratory medicine. 1999 Jun 1; 93(6):379-81.
12. Santambrogio L, Nosotti M, Bellaviti N, Pavoni G, Radice F, Caputo V. CT-Guided Fine-Needle Aspiration Cytology of Solitary Pulmonary Nodules* A Prospective, Randomized Study of Immediate Cytologic Evaluation. Chest. 1997 Aug 31; 112(2):423-5.
13. Westcott JL, Rao N, Colley DP. Transthoracic needle biopsy of small pulmonary nodules. Radiology. 1997 Jan; 202(1):97-103.
14. Orell SR, Sterett GF, Walters MN-I, Whitaker D: Manual and Atlas of Fine Needle Aspiration Cytology, 3rd ed. Edinburgh, Churchill Livingstone, 1999.
15. Arslan S, Yilmaz A, Bayramgurler B, Uzman O, Unver E, Akkaya E: CT-guided transthoracic fine needle aspiration of pulmonary lesions: accuracy and complications in 294 patients. Med Sci Monit 2002; 8: 493-97.
16. Kushwaha SK, Sachan AS, Gupta A, Gupta R, Sharma RD. Efficacy and safety of unguided percutaneous fine needle aspiration cytology in peripheral lung lesions. Journal of the Indian Medical Association. 1996 Mar; 94(3):105-7.
17. Larscheid RC, Thorpe PE, Scott WJ. Percutaneous transthoracic needle aspiration biopsy: a comprehensive review of its current role in the diagnosis and treatment of lung tumors. Chest. 1998 Sep 30; 114(3):704-9.
18. Huq MH, Talukder SI, Haque MA, Sarker CB, Saleh AF, Debnath CR. Role of fine needle aspiration cytology in the diagnosis of pulmonary lesions. Mymensingh medical journal: MMJ. 2004 Jan; 13(1):16-9.

19. Saha A, Kumar K, Choudhuri MK. Computed tomography-guided fine needle aspiration cytology of thoracic mass lesions: A study of 57 cases. *Journal of cytology*. 2009 Apr 1; 26(2):55.
20. Behera D, Balmugesh T. Lung cancer in India. *Indian J chest Dis Allied Sci* 2004; 46(4): 269-81.
21. Jung KJ, Jeon C, Jee SH. Smoking effect on lung cancer: ethnic difference and smoking paradox. *Epidemiology and Health*. 2016 Dec 20:e2016060.
22. Jindal SK, Malik SK, Dhand R, Gujral JS, Malik AK, Datta BN. Bronchogenic carcinoma in north India. *Thorax* 1982; 37: 343-47.
23. Sareen R, Pandey CL. Lung malignancy: Diagnostic accuracies of bronchoalveolar lavage, bronchial brushing, and fine needle aspiration cytology. *Lung India: Official Organ of Indian Chest Society*. 2016 Nov; 33(6):635.
24. DiBardino DM, Saqi A, Elvin JA, Greenbowe J, Suh JH, Miller VA, Ali SM, Stoopler M, Bulman WA. Yield and Clinical Utility of Next-Generation Sequencing in Selected Patients with Lung Adenocarcinoma. *Clinical lung cancer*. 2016 Nov 30; 17(6):517-22.
25. Prashant RC, Pattbhiraman R, Suresh AV. Feasibility, safety, and efficacy of the CT guided fine needle aspiration cytology (FNAC) of lung lesions. *Indian J Med Paediatr Oncol*. 2007; 28:16-25.
26. Mondal SK, Nag D, Das R, Mandal PK, Biswas PK, Osta M. Computed tomogram guided fine-needle aspiration cytology of lung mass with histological correlation: A study in Eastern India. *South Asian journal of cancer*. 2013 Jan 1; 2(1):14.
27. Madan M, Bannur H. Evaluation of fine needle aspiration cytology in the diagnosis of lung lesions. *Turk J Pathol*. 2010 Jan 1; 26:1-6.