

## A Comparative Study of Drainage of Breast Abscess by Conventional Incision and Drainage versus Percutaneous Placement of Suction Drain

Dr. Prashanth D, MBBS<sup>1</sup>, Dr. Anupkumar MC MS<sup>2</sup>, Dr. Deepak G. Udapudi MS<sup>3</sup>

Department of General Surgery, JJM Medical College, Davangere, Karnataka, India

### Original Research Article

\*Corresponding author

Dr. Prashanth D

### Article History

Received: 18.11.2018

Accepted: 28.11.2018

Published: 30.11.2018

### DOI:

10.36347/sjams.2018.v06i11.083



**Abstract:** Breast abscess is common in puerperal period secondary to mastitis with incidence of 4.8%-11%. The conventional method of incision and drainage of the breast abscess has undergone a gradual change from invasive to minimally invasive method of percutaneous placement of suction drain. To compare the effectiveness of percutaneous placement of suction drain in drainage of puerperal breast abscesses, with conventional incision and drainage with reference to postoperative pain, residual abscess, duration of hospital stay, time required for complete healing and appearance of scar. In our prospective study, 60 patients admitted to Bapuji Hospital and Chigateri General Hospital with a primary diagnosis of lactational breast abscess, between June 2016 and May 2018, were included. Patients were alternately treated by incision and drainage and percutaneous placement of suction drain under general anaesthesia. Minimal postoperative pain was observed in patients who underwent. Percutaneous placement of suction drain (VAS G1 and G2) compared to the patients who underwent incision and drainage (G4 and G5). Residual abscess was found in one case in the incision and drainage group and 3 cases in the group that underwent percutaneous placement of suction drain. Mean duration of hospital stay in the incision and drainage group was 7.9 days and that in the group that underwent percutaneous placement of suction drain was 4.3 days. Mean duration of complete healing in the group that underwent incision and drainage was 28 days and that in the group that underwent percutaneous placement of suction drains was 13.2 days. Patients who underwent percutaneous placement of suction drain had a minimal scar at the entry and exit site whereas the patients who underwent incision and drainage had poor cosmetic outcome with a large scar. Percutaneous placement of suction drain is an effective method of drainage of breast abscess as it is less invasive, requires lesser time for complete healing, scarless and preserves the function of the breast.

**Keywords:** Puerperal breast abscess, Incision and drainage, percutaneous placement of suction drain.

### INTRODUCTION

It used to be recommended that all breast abscesses have to be incised and drained [4]. This can lead to prolonged healing time, difficulties in breastfeeding, and unsatisfactory cosmetic outcome [5]. Hence, conventional incision and drainage has been replaced by less invasive procedure of repeated needle aspirations under antibiotic cover [4] and the former is reserved for those cases in which repeated needle aspiration has failed or there is other indication, such as, thinning and necrosis of overlying skin [6]. However, drainage of breast abscesses by ultrasound guided needle aspiration mandates the availability of an interventional radiology department and has some limitations for large abscesses or abscesses with thick material [8, 7].

Percutaneous placement of suction drain in treatment of breast abscess is an effective method of drainage of breast abscess that is devoid of any complication, scarless and preserves function of breast feeding [7].

### MATERIALS AND METHODS

The patients admitted at Bapuji and Chigateri General Hospital attached to JJM Medical College, Davangere with primary diagnosis of breast abscess were taken for this prospective study from June 2016 to May 2018 (2 years).

Based on detailed history, thorough clinical examination and needle aspiration, the diagnosis of breast abscess was made. These patients were subjected to the required preoperative investigations. Patients

alternately underwent incision and drainage and percutaneous placement of suction drain.

An ultrasound scan of the operated breast was done on the 3rd and 7th day to rule out residual abscess. Each patient was analysed with reference to post operative pain (based on visual analog scale), residual abscess (based on USG), duration of hospital stay, time required for complete healing and appearance of scar. Each patient was followed up in outpatient department at 1 week, 2weeks, 4weeks and 8 weeks after discharge.

Only patients with puerperal breast abscesses were included in this study and patients who had signs

of necrosis of the overlying skin were excluded from this study.

#### Percutaneous placement of suction drain

18F perforated catheter with the curved needle was introduced from one side of the abscess and then brought out through the opposite side of the abscess and the perforated end of the catheter was left in the abscess cavity. The entry site was closed with silk. Hydrogen peroxide and povidone iodine wash was given through the catheter which was fixed at the exit wound and then connected to the suction apparatus. The catheter was irrigated daily with hydrogen peroxide and povidone iodine and was removed between 3 and 5 days or when discharge is less than 10ml.

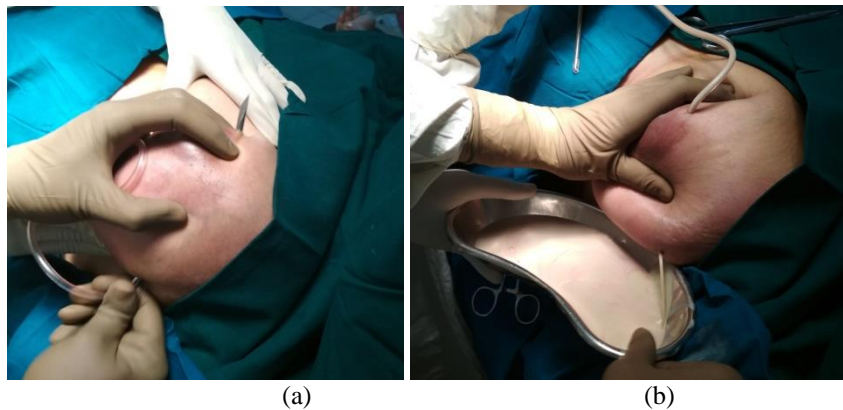


Fig-1: (a) Trochar was inserted from one side and brought out through the opposite side of the abscess, the loculi were broken. (b) Pus was drained through the entry site

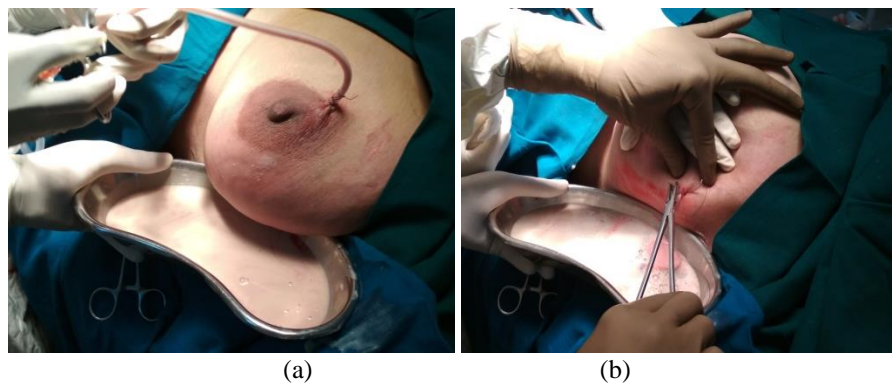
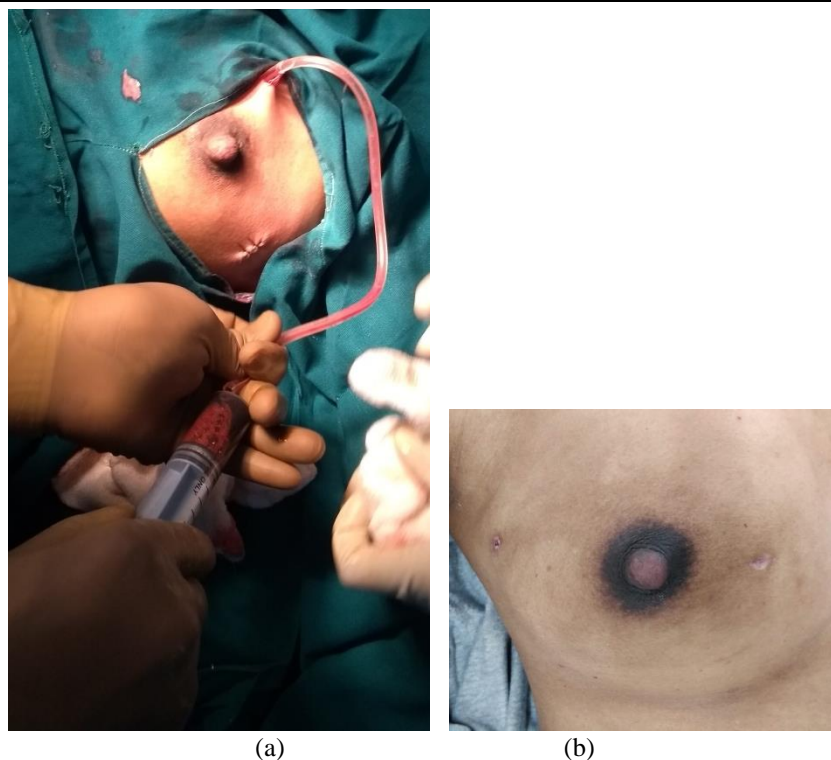

Fig-2: (a) Drain was fixed at the exit site. (b) Entry site was closed with sutures



**Fig-3: (a) The cavity was flushed with betadine and hydrogen peroxide and the drain tube is connected to a suction apparatus. (b) Scar noted on postoperative day 14**

**Incision and drainage**

A linear incision was made over the most fluctuant and dependant part of the abscess. All the loculi were broken by finger dissection. The pus is drained and the cavity is irrigated with hydrogen

peroxide and povidone iodine. The cavity is then loosely packed with betadine soaked gauze.

**RESULTS**

**Table-1: Comparison of age wise distribution of cases**

Age range (years)	Incision and drainage		Percutaneous placement of suction drain		Total	
	No.	Percentage	No.	Percentage	No.	Percentage
<25	10	33.3%	14	46.7%	24	40%
25-30	19	63.3%	15	50%	34	56.7%
>30	1	3.3%	1	3.3%	2	3.3%
Total	30		30		60	
Mean + SD	25.73 + 3.32		24.97 + 3.35			

In the present study only puerperal breast abscess cases were taken and the most commonly affected age group was 25-30 years, with 34 cases

(56.7%) followed >25 years, with 24 cases (40%). The youngest patient in my study was 20 years and the oldest is 31 years.

**Table-2: Comparison of size of abscess**

Size	I and D		Percutaneous placement of suction drain		Total	
	No.	Percentage	No.	Percentage	No.	Percentage
<4cm	5	16.7%	9	30%	14	23.3%
4-5cm	17	56.7%	16	53.3%	33	55%
>5cm	8	26.7%	5	1.7%	13	21.7%
Total	30		30			

In the present study 14 patients had breast abscesses of size less than 4cm and 33 patients had

breast abscess of size 4-5cm and 13 patients had breast abscesses of size greater than 5 cm.

**Table-3: Comparison of postoperative pain**

Postoperative pain (VAS)	I and D		Percutaneous placement of suction drain		Total
	No.	Percentage	No.	Percentage	
G1	0	0%	13	43.3%	13
G2	0	0%	17	56.7%	17
G3	0	0%	0	0%	
G4	15	50%	0	0%	15
G5	15	50%	0	0%	15
Total	30		30		60

Chi-square = 60.0, P<0.000, HS

In this present study VAS grade for the group that underwent percutaneous placement of suction drain group was G1 for 13 patients (43.3%) and G2 for 17

patients (56.7%). VAS grade for the group that underwent incision and drainage was G4 for 15 patients (50%) and G5 for 15 patients (50%).

**Table-4: Comparison of residual abscess cases**

Residual Abscess	I and D		Percutaneous placement of suction drain		Total
	No.	Percentage	No.	Percentage	
Yes	1	3.3%	3	10%	4 (6.7%)
No	29	96.7%	27	90%	56 (93.3%)
Total	30		30		60

Fisher's Exact Test= P<0.301, NS

In the present study residual abscess was noted in 1 patient (3.3%) in the group that underwent incision

and drainage and 3 patients (10%) in the percutaneous placement of suction drain group.

**Table-5: Comparison of duration of hospital stay (days)**

Duration of hospital stay	Group		I and D versus percutaneous placement of suction drain	
	Incision and drainage	Percutaneous placement of suction drain	t value	P value
Mean ± SD	7.9 ± 1 days	4.3 ± 1.4 days	11.68	P<0.000 (HS)
Range	7-10 days	3-8 days		

In the present study the mean hospital stay in I and D patients was 7.9 ± 1 days and patients who underwent percutaneous placement of suction drain was

4.3 ± 1.4 days. There was significant difference noted between the two groups.

**Table-6: Comparison of duration of complete healing (days)**

Duration complete healing (days)	Group		Incision and drainage versus Percutaneous placement of suction drain	
	Incision and drainage	Percutaneous placement of suction drain	t value	P value
Mean + SD	28 + 6 days	13.2 + 5.9 days	9.46	P<0.000 (HS)
Range	21-35 days	9-35 days		

In the present study the mean duration of complete healing in patients who underwent incision and drainage was 28 ± 6 days and patients who underwent percutaneous placement of suction drain was 13.2 ± 5.9 days.

patients. Size of the two scars noted in group that underwent percutaneous placement of suction drain was 0.5x1cm in 27 (90%) patients. Scar size in other 3 patients of percutaneous placement of suction drain who had to undergo open surgical drainage group was 4x2cm, 5x2 and 6x2cm. Percutaneous placement of suction drain resulted in a smaller scar as compared to incision and drainage, hence cosmetically better.

In the present study, size of the scar noted in group that underwent incision and drainage was 4x2cm in 22 (73.3%) patients, followed by 5x2cm in 5 (16.7%)

**Table-7: Comparison of size of the scar**

Size of the scar (cm)	I and D		Percutaneous placement of suction drain		Total
	No.	Percentage	No.	Percentage	
0.5x1, 0.5x1	0	0	27	90%	27
4x2	22	73.3%	1	3.3%	23
5x2	5	16.7%	1	3.3%	6
6x2	2	6.7%	1	3.3%	3
7x2	1	3.3%	0	0	1
Total	30		30		60

Chi-square = 60.0, P&lt; 0.000 (HS)

## DISCUSSION

### Postoperative pain

In the present study, VAS grade for patients who underwent incision and drainage was G5 for 15 patients (50%) and G4 for 15 patients (50%). The VAS grade for majority of the patients who underwent percutaneous placement of suction drain was G2 (17 patients, 56.7%) and remaining were G2 (13 patients, 43.3%). It is obvious that patients who underwent incision and drainage had more pain as compared to patients who underwent percutaneous placement of suction drain.

### Treatment failure

In the present study, presence of residual abscess detected clinically or by postoperative ultrasonography was considered as treatment failure. Among the patients who underwent incision and drainage only 1 patient had recurrence (3%) and the group that underwent percutaneous placement of suction drain there were 3 patients (10%) who had recurrence. In the study conducted by Tewari *et al.* no patients who underwent percutaneous placement of suction drain had recurrence [7]. In a study conducted by Karvande R *et al.* among the 14 patients who underwent incision and drainage, the recurrence rate was 3.3% [9]. In a study conducted by Dener *et al.* there were no recurrences in the 16 cases of lactational breast abscesses that underwent incision and drainage[10].

### Duration of hospital stay

In the present study, the mean duration of hospital stay in patients who underwent incision and drainage was 7.9 days and that in the group that underwent percutaneous placement of suction drain was 4.3 days. In the study conducted by Tewari *et al.* all patients underwent percutaneous placement of suction drain on out patient basis. The mean duration of hospital stay in 30 patients who underwent incision and drainage of breast abscess was 1.16 days in a study conducted by Karvande *et al.* [10].

### Duration of complete healing

In the present study the mean duration of complete healing was 13.2 days for the group that underwent percutaneous placement of suction drain and was 28 days for the group that underwent incision and

drainage. In the study conducted by Chuwa *et al.*, the mean time for complete healing in patients who underwent incision and drainage of breast abscess was 21 days (range, 5–28 days) [11]. Mean time taken for complete healing in patients who underwent incision and drainage of breast abscesses in a study conducted by Karvande *et al.* was 7.7 days [10].

### Size of the scar

In the present study, the size of scar at the entry site is 0.5cm x1cm and at the exit site is 0.5cm x1cm in all the 27 patients who were successfully treated by percutaneous placement of suction drain. The size of the scar following incision and drainage was 4x2cm in majority (73.3%) of the patients followed by 5x2 (16.2%).

## CONCLUSION

There are several advantages of the method of percutaneous placement of suction drain as compared to conventional incision and drainage of puerperal breast abscesses-

- In multiloculated abscesses, the loculi are punctured by the trochar of the suction drain that traverses the entire length of abscess.
- The negative suction drain collapses the abscess cavity and drains any remnant pus.
- Patients can continue breast immediately after the procedure.
- There is minimal scarring and distortion of the breast tissue.
- The discomfort associated with carrying the suction drain is minimal and post catheter placement care is simple and can be made easier by the assistance of a general practitioner or a community nurse.
- Percutaneous placement of suction drain is cost effective.
- It has superior cosmetic outcome.
- This procedure can be carried out in primary health centres in remote areas.<sup>7</sup>

## REFERENCES

1. Postgraduate in General Surgery, JJM Medical College, Davangere, Karnataka, India.
2. Professor, Department of General Surgery, JJM Medical College, Davangere Karnataka, India.
3. Professor, Department of General Surgery, JJM Medical College, Davangere, Karnataka, India.

4. Ruth S. Prichard. The breast. In: Williams N, O'Connell P, Mc Caskie A, editors. Bailey & Love's Short Practice of Surgery. 27th ed. Boca Raton: CRC Press. 2018.
5. Stuart J. Schnitt, Laura Christine Collins. Pathology of the Benign Breast Disorders. In: Jay R. Harris, Marc E. Lippman, Monica Morrow C. Kent Osborne. Diseases of the breast. 4th ed. Wolters Kluwer Health. 2010.
6. Brunicardi F, Anderson D, Billiar T, Dunn D, Hunter J, Pollock RE, Matthews J. Schwartzs Current Practice of General Surgery (EBOOK). McGraw Hill Professional; 2014 Oct 6.
7. Tewari M, Shukla HS. An effective method of drainage of puerperal breast abscess by percutaneous placement of suction drain. Indian J Surg. 2006; 68(6): 332-335.
8. Eryilmaz R, Sahin M, Hakan Tekelioglu M, Daldal E. Management of lactational breast abscesses. Breast. 2005;14:375–379.
9. Rajiv Karvande, Manoj Ahire, Makrand Bhole, Chetan Rathod. Comparison between aspiration and incision and drainage of breast abscess. Int Surg J. 2016 Nov; 3(4):1773-1780.
10. Dener C, Inan A. Breast abscesses in lactating women. World journal of surgery. 2003 Feb 1;27(2):130-3.
11. Chuwa EW, Wong CM, Tan YY, Hong GS. MRSA breast abscesses in postpartum women. Asian journal of surgery. 2009 Jan 1;32(1):55-8.