

A Comparative Study of Intramedullary Nailing Versus Plating in Fracture Tibia and Fibula

Dr. Rabi Narayan Dhar¹, Dr. Pradeep Kumar Merli^{2*}, Dr. Rashmi Ranjan Dash³

¹Associate Professor, Dept of Orthopaedics, VIMSAR, Burla, Odisha, India

²Assistant Professor, Dept of Orthopaedics, VIMSAR, Burla, Odisha, India

³Post graduate student, Dept of Orthopaedics, VIMSAR, Burla, Odisha, India

Original Research Article

*Corresponding author

Dr. Pradeep Kumar Merli

Article History

Received: 12.03.2018

Accepted: 21.03.2018

Published: 30.03.2018

DOI:

10.36347/sjams.2018.v06i03.071



Abstract: Malalignment has been frequently reported after intramedullary stabilization of distal tibia fractures. Nails have also been associated with knee pain in several studies. Historically, plate fixation has resulted in increased risks of infection and non-union. Our purposes were to compare plate and nail stabilization for distal tibia shaft fractures by assessing complications and secondary procedures. We hypothesized that nails would be associated with more malalignment and non-union. 68 patients with extra-articular distal tibia shaft fractures with a mean age of 38 years (range, 18-95 years) and mean Injury Severity Score of 13.5 were included in this study. Patients were randomized to a reamed intramedullary nail (n =34) or a large fragment medial plate (n = 34). Forty fractures (39%) were open. Twenty-eight (27%) had concomitant fibula fractures that were stabilized. Outcomes like Malunion, non-union, infection, and secondary operations were measured. Eighty-three percent of infections occurred in open fracture (P < 0.001). Four patients (7.1%) developed non-union after nailing versus two (4.2%) after plating (P = 0.25) with a trend for non-union in patients who had distal fibula fixation (12% versus 4.1%, P = 0.09). All non-union occurred after open fracture (P = 0.0007); the primary union rate for closed fractures was 100%. Primary angular malalignment of 5° or greater occurred in 13 patients with nails (23% of all nails) and four with plates (8.3% of all plates; P = 0.02 for plates versus nails). Six additional patients experienced malalignment after immediate weight bearing against medical advice. Valgus was the most common deformity (n = 16). Malunion was more common after open fracture (55%, P = 0.04). Eighty-five percent of patients with malalignment after nailing did not have fibula fixation. Eleven patients underwent 15 secondary procedures after plating, five of which were for prominent implant removal. This was not significantly different from patients treated with nailing: 10 patients had 14 procedures and five for prominent implant removal. High primary union rates were noted after surgical treatment of distal tibia shaft fractures with both no locked plates and reamed intramedullary nails. Rates of infection, non-union, and secondary procedures were similar. Open fractures had higher rates of infection, non-union, and malunion. Intramedullary nailing was associated with more malalignment versus plating.

Keywords: Intramedullary, nailing, plating, tibia, fibula.

INTRODUCTION

Distal tibial fractures continue to be one of the most controversial fractures that we treat. The type of fractures includes extra articular fractures of the metaphysis and the more severe intra-articular tibial plafond or pilon fractures. Fractures of distal tibia are also distinct from pilon fractures in mechanism of injury and also in the management. The mechanism of injury is bending force or twisting force that results in transverse, oblique or comminuted fractures resulting from high energy road traffic [1] accidents when

compared to pilon fractures which results from axial loading mechanism [2]. Several treatment methods have been recommended for the treatment of these injuries including variations of external fixation, intramedullary nailing (with and without reaming), and plate fixation with a recent emphasis on minimally invasive techniques. Studies of treatment outcome for distal tibial fractures of the metaphysis are uncommon. Locked intramedullary nailing is the TOC for closed fracture of tibial shaft

Minimally invasive percutaneous plate osteosynthesis (MIPPO) was one such method in which plate was introduced percutaneously and fixed proximal and distal to the fracture percutaneously [3]. MIPPO had advantage of biological fixation, less vascular damage, indirect reduction with less soft tissue stripping, proper restoration of axial and rotational alignment with sufficient stability to allow early range of motion (ROM) exercise and ambulation. But delayed healing, infection and hardware problems were some of the major concerns. It was technically simple, easier to master, need no additional expensive instruments, cheaper to the patient and facilitate early mobilization of the patients [4]. A recent trend in internal fixation by MIPPO had been a move towards locking screws which can rigidly stabilize cancellous bone that is normally not amenable to screw fixation retaining the fundamental goal of treatment of distal tibial fractures as restoration of normal or near normal alignment and articular congruity. Locking compression plating (LCP) provides an angular stability for fixation. Locked screws prevent the plate from pressing the bone, preserving periosteal blood supply. This system stimulates callus formation due to flexible elastic fixation. The anatomic shape of the plate prevents malalignment of the fracture and provides a better axial and angular weight distribution.

Aims of the study

- To compare the functional outcomes of distal tibial metaphyseal fractures of tibia by anatomical locked plate by MIPPO technique to that with reamed intramedullary nailing at 2 years.
- To alleviate the controversies regarding the complications arising from management of distal tibial metaphyseal fractures by nailing and plating by MIPPO technique.
- To set the indications for both modalities of fixation.

METHODS

All the patients were admitted to Orthopaedic Department of Veer Surrender Sai institute of medical science and research (VSSIMSAR) from November 2015 to October 2017.

The inclusion criteria

- Adults with age > 18 years and <65 years
- Distal tibial extraarticular fracture, minimum of 3cm of distal fragment.
- 3. Closed and Gustilo-Anderson grade I fracture
- Patients who were medically fit for surgery

The exclusion criteria

- Displaced intra articular fractures
- Gustilo-Anderson grade II and grade III fractures
- Fracture with Neuro vascular injury
- Pathological fractures

- 5. Fractures associated with compartment Syndrome
- Patients who are medically unfit and not willing for surgery

Appropriate anteroposterior and lateral radiographs were taken of injured limb and of contralateral normal limb for comparison. The fracture patterns were classified according to the Orthopaedic Trauma Association classification (AO/OTA). The soft tissue injury was classified according to Tschrene classification [5].

Preoperative planning

Preoperative planning of sequence of events was done before actual operation so as to minimise the complications and anticipate the intraoperative problems. A detailed preanaesthetic examination was done, the need for transfusion was decided and consent was taken. Patient positioning and need for the tourniquet were decided. The correct dimensions of the implants were calculated.

For intramedullary interlocking nail

The length of the nail was calculated using tibial tubercle to medial malleoli distance and subtracting the length by 1cm. This was accurate and inexpensive method available to calculate the nail length when compared to using templates which is less accurate. To calculate the diameter of nail, the opposite normal limb medullary canal at isthmus from inner cortex to inner cortex was measured and was divided by factor of 1.07 to account for radiographic magnification. The lengths of bolts were measured on radiographs and correction for magnification factor was done.

For hippo technique

The length of the plate, contouring and dimensions of the screws were calculated using templates and radiographs.

Additional instruments required for achieving the reduction and maintaining it intraoperatively were decided in preoperative planning such as K-wires for reduction, fracture table and bolster for reduction, AO distractor, cortical screws for using them as poller (blocking) screws, and plate bender for contouring the plate.

Postoperative protocol

Operated limb was immobilised in posterior splint. Mobilization of the knee and ankle was started in the immediate postoperative period. Early no weight bearing mobilization of the patient was started from 5th day onwards after inspection of suture line. X-ray radiograph of the involved leg was taken post operatively, at 6 weekly intervals till union and at 1 year follow-up.

Acceptable alignment was defined as less than 10° anterior/posterior angulation, less than 5° varus/valgus deformity or less than 10° rotation difference and shortening less than 1 cm.

Malunion was measured by the angle created by the intersection of the subchondral line of the plafond and a line drawn up the centre of the tibial shaft. Ninety degrees was considered normal and deviations of more than 5° were recorded as either varus, valgus, more than 10° anterior or posterior angulation. Rotational malalignment and limb length discrepancy was assessed clinically comparing with other limb (block method).

Patient was discharged after suture removal with strict orders of non weight bearing till next follow up. Patient was followed up clinically and radiologically at 6 weekly intervals till union and at 1 year.

A clinical evaluation for the functional assessment of the ankle was obtained at one year follow-up by Olerud and Molander Ankle Score (OMAS) and The American Orthopaedic Foot and Ankle surgery (AOFAS) scoring. The OMAS is a patient reported score but is more specifically related to injuries around the ankle and includes assessment of: pain, stiffness, swelling, stair climbing, running, jumping, squatting, supports and work and activities of daily living. It is transformed to a 100 point scale, where 100 represents normal function and 0 the worst possible function.

The American Orthopaedic Foot and Ankle Society (AOFAS) Ankle-Hindfoot Scale is a clinical rating system developed by Kitaoka *et al.* It combines

subjective scores of pain and function provided by the patient with objective scores based on the surgeon's physical examination of the patient. The AOFAS clinical rating systems do not incorporate any radiographic criteria into the assessment. The patients rate his or her pain and function levels on a written questionnaire. Then we do the physical examination of the patient to assess the sagittal motion, the hind foot motion, the ankle-hind foot stability, and the alignment of the ankle-hind foot. The AOFAS Ankle-Hind foot Scale is scored with a possible 100 points. There are no defined limits of what scores constitute excellent, good or poor outcome.

The final results at the end of 2 year follow up were evaluated using the "Johner & Wruhs' Criteria" as excellent, good, fair and poor.

RESULTS

In our study, 62 cases of extra articular distal tibia fractures were treated. All cases were fresh, 46 patients were male and 16 female. The mean age of patients was 37.6 years.

Out of 62 fractures, 52 were caused by road traffic accident, 8 from fall and 2 had history of assault. 28 patients had fracture on left side and 34 on right side.

All fractures were classified according to AO/OTA classification of which 18 fractures were 43A1, 28 fractures were 43A2 and 16 fractures were 43A3. 52 fractures were closed and 10 were compound. The soft tissue injury was graded according to Tscherny classification of which 8 fractures were type 0, 16 were type 1 and another 20 were of type 2 injury, 8 were type 3. All compound fractures were Gustilo-Anderson grade I type.

Table-1: Impact of nailing and mippo on duration of fracture union

UNION TIME IN WEEKS	NAIL(n=34)		MIPPO(n=34)	
	NO OF CASES	PERCENTAGE	NO OF CASES	PERCENTAGE
16-20	24	70.58%	10	35.71%
21-24	10	29.41%	10	50.00%
25-28	0	0	7	7.14%
≥29	0	0	7	7.14%

All fractures in nail group united in this study and most of them (24 fractures) united between 16-20 weeks. The mean union time was 19.8 weeks(95% confidence interval 18.712-20.817). All fractures in plate group except two united and most of them (24 fractures) united between 16-24 weeks(95% confidence interval 18.987-22.551). 8 fractures in the nail group united between 21-24wks including 6 cases of dynamisation. Out of four fractures in mippo group which got deep infection, two cases finally turned to infected non union and treated with ring fixator after implant removal and infection control, which finally

united at 46 weeks. The other two cases with discharging sinus carefully followed-up every 2weeks with proper antibiotic cover; finally they united at 27wks.

In the immediate postoperative period radiographic evaluation of reduction and alignment was done, in which 36 fractures showed acceptable alignment, 4 fractures of nail group had valgus angulation of 8° and 2 fracture of mippo group had Varus angulation of 10°(fig-1).

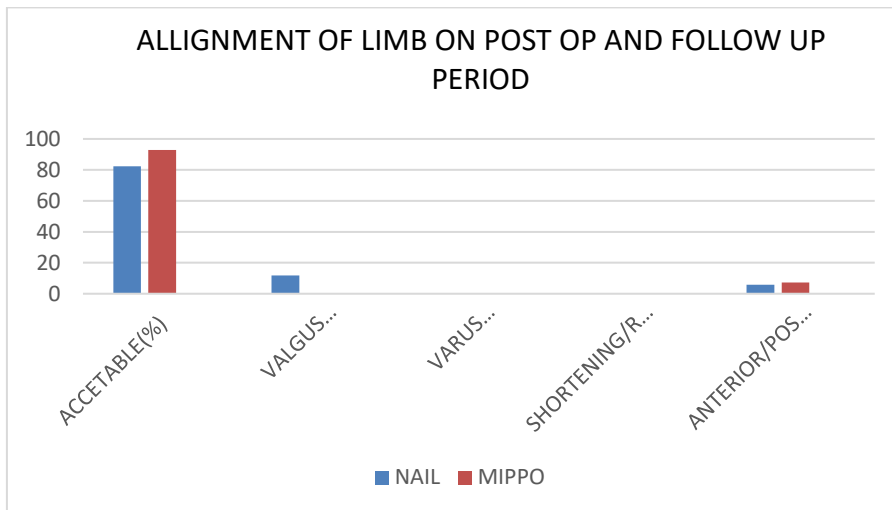


Fig-1: Alignment of Limb on Post OP and Follow Up Period

When followed up for one year the degree of alignment in all cases did not differ significantly and cases which were misaligned in immediate postoperative period went on to unite in that position except two cases in nail group which had good post-operative alignment develop recurvatum deformity on subsequent follow-up and finally united with 15 ° anterior malalignment. None of the cases had rotational malunion and shortening.

Infection occurred in eight cases all of which belong to the hippo group out of which 4 were superficial that controlled with dressing and antibiotic and caused no hindrance to bone union. 4 other cases which developed deep infection, two of them were gone into delayed union but two other cases ended up with

infected non-union. 4 cases of MIPPO had impingement and implant irritation for which symptomatic treatment was given. None of the cases which were treated with intramedullary nailing had infection as complication though 10 cases of our series were gustilo-anderson grade I. Two of the cases had implant failure in the form of breakage of distal locking screw in nail group, but it had no interference with fracture union. There were two cases of delayed union. Four of the cases of nail group had anterior knee pain that improved after nail removal. 8 cases required secondary procedures to achieve union. 6 cases were of intramedullary nailing group and all 6 were dynamited. The rest two cases were of mippo group that got infected and ring fixation was done to unite the fracture (fig-2).

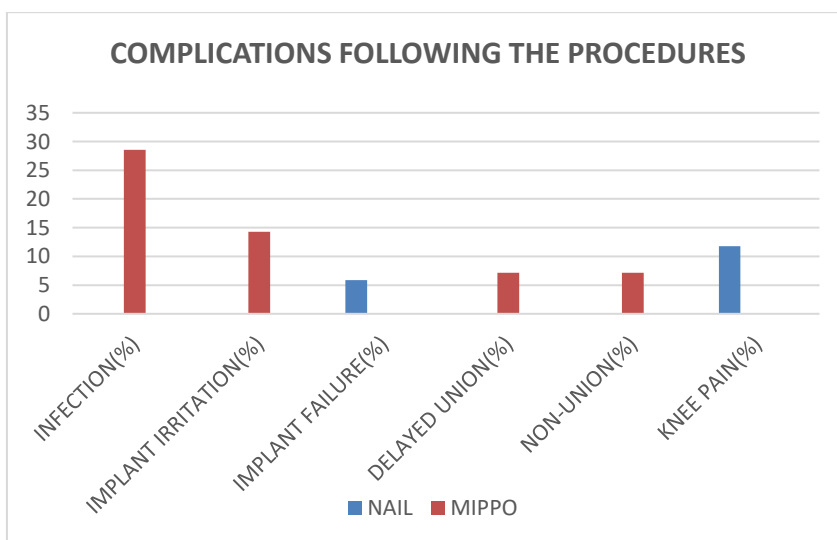


Fig-2: Complications Following the Procedures

The minimum period of follow up in our study was 1 year ranging from 12 months to 18 months, except 4 cases which lost to follow-up after union of fracture?

A clinical assessment of ankle function was done according to the criteria of Oleum and Molander Ankle Score (OMAS) and The American Orthopaedic Foot and Ankle surgery (AOFAS) scoring (table-2).

Table-2: Clinical assessment of ankle function

ANKLE SCORE		NAIL(n=34)		MIPPO(n=34)	
OLERAUD SCORE		NO OF CASES	PERCENTAGE	NO OF CASES	PERCENTAGE
	100	28	93.33%	16	57.14%
	95	2	6.67%	10	35.71
	90	0	0%	0	0%
	85	0	0%	2	7.14%
<85	0	0%	0	0%	
AOFAS SCORE	75-80	0	0%	8	28.57%
	81-85	18	60.00%	12	42.86%
	85-90	12	40.00%	8	28.57%
	>90	0	0%	0	0%

The mean OMAS for mippogoup were 97.143(range from 95 to 100), the 95% confidence interval being 94.685-99.601.The mean OMAS for nailing group were 99.333(range from 95 to 100),the 95% confidence interval being 98.385-99.316).The American Orthopaedic Foot and Ankle Society (AOFAS) Ankle-Hindfoot Scale is a clinical rating system developed by Kitaoka *et al.* It combines

subjective scores of pain and function provided by the patient with objective scores based on the surgeon's physical examination of the patient. The mean AOFAS score for mippo group were 83.571(range from 78-89),95% confidence interval being 81.881-85.262 .The mean AOFAS score for nail group were 84.867 (range from 82-90),the 95% confidence interval being 83.579-86.155.

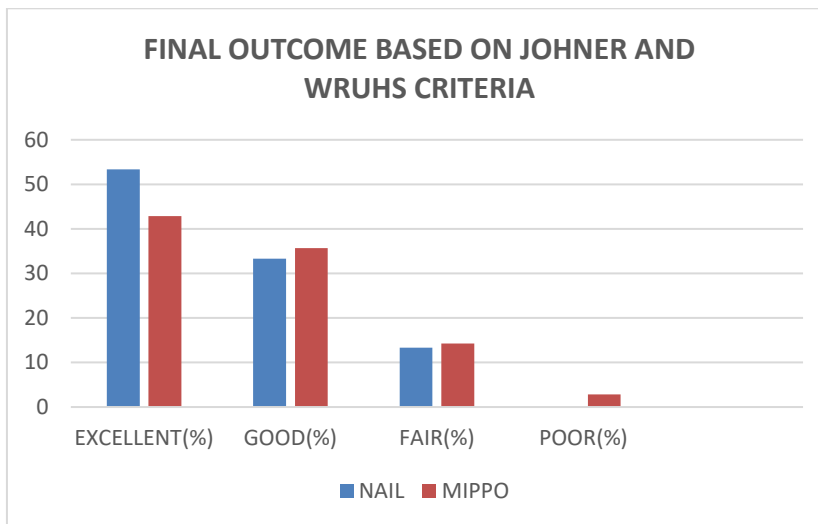


Fig-3: Final Outcome Based on Johner and Wruhs Criteria

The final outcome was assessed based on Johner and Wruhs criteria, 16 had excellent outcome, 10 had good outcome, 4 had fair outcome and 4 are lost to follow- up in nail group. Out of 28 of mippogroup 12 had excellent outcomes, 10 had good outcome, 4 had fair outcomes and 2 had poor outcome (fig-3).

DISCUSSION

Careful preoperative planning is needed in consideration with above mentioned factors in selecting the correct implant for given fracture pattern and associated soft tissue injury and minimizing the postoperative mal alignment and soft tissue complication.

Our study comprised of 68 patients with intraarticular distal tibia fracture out of which 34 were treated with intramedullary nailing and 28 with plate

fixation using minimally invasive techniques based on soft tissue condition and fracture pattern. Decision of fixing the associated fibula fracture was done depending on initial displacement, intraoperative alignment of tibia fracture and whether it caused any disturbance to ankle mortise and syndesmotoc stability.

In our study, we allowed weight bearing only after signs of union in form of bridging callus on at least 3 cortices on radiograph, absence of tenderness at fracture site and patient ability to bear weight is present usually by 12-14 weeks. We had 28 cases (82%) out of 34 in nail group and 20 cases (78%) out of 28 cases in mippogroup, having fulfilling above criteria around 12-14 weeks and were allowed to bear weight. In study by Oh W *et al.* [5] on hippo the mean time for complete weight bearing was 13.2 weeks and it was 14 weeks in study by Mehmet Atif Erol AKSEKLi *et al.* [22]. In

study by M Aslam Siddiqui *et al.* [21] on intramedullary nail the mean time for complete wt bearing was 13 wks and in similar study by Kasper W. Janssen *et al.* [47] it was 14.2 weeks. Our findings are similar to these results.

All fractures in nail group united in our study and most of them (24 fractures) united between 16-20 weeks. The mean union time was 19.8 weeks (95% confidence interval 18.712-20.817). 8 fractures in the nail group united between 21-24 weeks including 6 cases of dynamisation. In similar study by NorkS, *et al.* [9], 80% of the fractures united before 30 weeks and the mean time for union was 23.5 weeks. Ehlinger M *et al.* [18] achieved union before 30 weeks in all cases, the mean time being 16 weeks. In study by Fan C *et al.* [34] had mean union time of 17.2 weeks. Robinson C, *et al.* [3] 12 achieved union in all cases by 22.2 weeks when treated with IMIL nail.

In MIPPO group, most fractures (18 fractures, 65%) united between 18-22wks, the mean being 20.8 weeks (95% confidence interval 18.987-22.551). 2 cases in MIPPO group with delayed infection showed delayed union at 27 weeks. Oh W, *et al.* [5] in their study, similar to ours found the mean union time for these fractures treated with MIPPO was 15.2 weeks (range, 10-24weeks). In study by Ronga M, *et al.* [16] union was achieved in all fractures by 24 weeks. In study by Borg T *et al.* [7], they achieved union in 90% of fractures within 24 weeks. The mean time for union in Collinge C, *et al.* [12] study was 35 weeks but all fractures which were closed healed within 25 weeks.

Based on these findings we can conclude that dynamisation is an effective procedure and should be done in cases with slow progress to union before deciding on to more invasive procedure. In MIPPO group all fractures united without need of any secondary procedure except 2 cases that ended as infected non union and needed ring fixator for union. Collinge C, *et al.* [12] in their study had 8% cases requiring secondary procedures for union. In their study by J Guo *et al.* [19] all fractures in MIPPO group had united without any secondary procedure. Secondary procedure rate varies in different studies, 5% S. Hazarica *et al.* [10], 2% T W Lau *et al.* and 2.5 % in study by R K Gupta *et al.* All cases in our study treated with MIPPO healed without secondary procedures, this may be because of small number of cases in our study, all cases being closed and correct intraoperative techniques.

In our study, we had acceptable alignment in 28 cases out of 34 (82.4%) in nail group and 26 cases out of 28(93%) in MIPPO group. Of 8 cases 6 cases which had malalignment evident on immediate postoperative period healed in same position at follow up of 1 year and no significant change was noted. 2 cases in nail group developed recurvatum deformity on

weight bearing and united with 15° anterior angulation. This finding suggests intraoperative error could be the prime cause for malunion and it also throws light on difficulty in reducing the distal fragment accurately. 4 cases had valgus malunion and 2 cases had recurvate deformity which was primarily fixed with IMIL nail and 2 had varus malalignment which belonged to MIPPO.

In study by Ronga M, *et al.* [16] 4 cases (21%) out of 21 cases who were treated with MIPPO had unacceptable malunion with varus deformity and 2 had anterior angulation. None of the patients had rotational deformity and shortening. In study by Collinge C, *et al.* [42] 93% fractures united without significant malalignment.

In study by Ehlinger M, *et al.* [18] on these fractures with IMIL nail, they had 27.5% of cases having malunion the most common being valgus or combination of valgus with other deformity in AP or rotational plane. In the study by NorkS, *et al.* [9] 3 out of 30 cases had malunion with one case in valgus and 2 cases recurvatum. J Guo *et al.* in their study did not detect any case on mal-alignment. Study by A. Krishan, *et al.* [15] had malunion rate of 8% both in coronal and sagittal axis. In above mentioned studies they did not have rotational deformity and shortening. It is evident that these fractures tend to malalign in valgus/varus or in anterior /posterior direction. Our results are comparable to above studies.

None of the fractures treated with nailing in our study had infection (superficial and deep) as complication though we had nailed 10 cases of Gustilo-Anderson grade I injuries. A. Krishan, *et al.* [15] in their study got only 2 cases of superficial infection though they had done nailing in 11 case including Gustilo-Anderson Grade I, II and IIIA. In study by Ehlinger M, *et al.* [18] they had 2 deep infections (5%) requiring lavage and in study by Nork S, *et al.* [35] one case had deep infection. Guo J, *et al.* [19] in their comparative study of IMIL nail with MIPPO concluded that wound complication are more with MIPPO than nailing (3% vs 6%). Our study also showed the same trend as above mentioned trend. Four of our cases in nail group experienced knee pain; the cause for knee pain might be proximal end of nail prominence above the cortex that was subsided after nail removal.

None of the cases had implant failure as complication in our study except two where the distal locking bolt was broken. In these cases fracture united in due course but patient was lost to follow-up. In study by Ehlinger M *et al.* [18] and in study by NorkS *et al.* [9] no complications related implant failure occurred. Oh W, *et al.* [5] and A. Krishan [15] *et al.* In their study had no implant failure cases. Whereas M Aslam Siddiqui *et al.* [21] had 2 cases of distal screw breakage. In MIPPO group Collinge C, *et al.* [12] 38 had 7%

cases having loss of fixation and S. Bahari, *et al.* [25] had implant failure fixation in 1 case. Whereas Mehmet Atif Erol AKSEK iLi *et al.* [22], D. Shrestha, *et al.* [20] and Mohamed Sukeik, *et al.*[17] found no implant failure in their studies on MIPPO.

We had implant impingement and irritation in 4 of 28(14%) cases of MIPPO for which symptomatic treatment was given and patients are doing well. Oh W, *et al.* [5] in their study had 40% patients and D. Shrestha, *et al.* [20] had 38% patients experiencing implant impingement. Lau T, *et al.* [14] in their study had 52% experiencing implant discomfort. Only 14% had their implant removed for this reason and opined that decision on implant removal for this complication should be justified. We opine that implant irritation and impingement is related to thickness of implant and designs, the better result in our study is due to use of low profile 3.5mm plate and better designed plate in our case series.

Oh W, *et al.* [5] in their study on MIPPO had excellent to satisfactory results in all cases using olerud score at the end of mean follow-up of 20 months. Guo J, *et al.* [19] in their comparative study of IMIL nail with MIPPO had mean score of 83 for IMIL and 81 for MIPPO using AOFAS (American orthopaedic foot and ankle surgery) as scoring system for ankle function. According to this system, results will be graded as good if score is between 80-90. Collinge C, *et al.* [12] in their study used both AOFAS (American orthopaedic foot and ankle surgery) and olerud score to evaluate functional outcome and had good results in most of their cases. So our study conclude that functional outcomes at one year follow-up does vary significantly between MIPPO or interlocking nail treated patients and it was in accordance with above mentioned studies.

The final outcome was assessed based on Johner and Wruhs [24] criteria, 16 had excellent outcome, 10 had good outcome, 4 had fair outcome and 4 are lost to follow-up in nail group. Out of 28 of mippogroup 12 had excellent outcomes, 10 had good outcome, 4 had fair outcomes and 2 had poor outcome.

CONCLUSION

Most of the closed extra articular fractures of distal tibia are caused by high energy trauma. A gap of 3-7 days between injury and surgery should be the protocol especially if plating using minimal invasive technique is planned so as to reduce the incidence of soft tissue complications. In compound fractures, early debridement and interlocking is a better option. Both clinical and radiological parameters should be evaluated before allowing bearing weight. Intramedullary nail being load sharing device, comparatively early mobilization could be started. Prolonged duration of protected weight bearing was required in patients treated with locked plate and screws. Closed fractures progress to predictable healing when treated surgically

with either nails or plate fixation. Dynamisation as a secondary procedure to achieve union is simple, quick and effective in fracture slowly progressing to union treated with interlocking nails. The decision to dynamise the nail can be taken at 4-6 weeks. Anterior knee pain is noted only with intramedullary technique and no knee complications were noted with plating group. If principles of treatment are correctly followed, most of cases will have good final outcome with either modality of treatment for these fractures. Therefore the choice of treatments should be based on surgeon's expertise, the clinical condition of the patient and patient's injury pattern.

REFERENCES

1. Schatzker J, Tile M, The rationale of operative fracture care, 3rd edition: p 475-76.
2. Canale & Beaty. Campbell's Operative Orthopaedics: In 51, 11th edition:
3. Robinson C, McLauchlan J, McLean I, Court-Brown, "Distal metaphyseal fractures of the tibia with minimal involvement of the ankle. Classification and treatment by locked intramedullary nailing". J Bone Joint Surg Brit 1995; 77B: 781-87.
4. Dogra A, Ruiz A, Thompson N, Nolan P "Di-metaphyseal distal tibial fractures treatment with a shortened intramedullary nail: a review of 15 cases". Injury2000; 31(10): 799-804.
5. Oh CW, Kyung HS, Park IH, Kim PT, Ihn JC. Distal tibia metaphyseal fractures treated by percutaneous plate osteosynthesis. Clinical orthopaedics and related research. 2003 Mar 1; 408:286-91.
6. Schmidt A, Finkemeier C, TornettaIII P "Treatment of Closed TibialFractures".J Bone Joint Surg 2003; 85(2): 1582-85.
7. Borg T, Larsson S, Lindsjö U "Percutaneous plating of distal tibial fractures. Preliminary results in 21 patients". Injury. 2004 Jun; 35(6): 608-14.
8. Fan C, Chiang C, Chuang T, Chiu F, Chen T "Interlocking nails for displaced metaphyseal fractures of the distal tibia". Injury 2005; 36(5): 669-674.
9. Nork S, Schwartz A, Agel J, Holt S, Schrick J, Winquist R "Intramedullary nailing of distal metaphysealtibial fractures". J Bone Joint Surg Am. 2005; 87 (6):1213-21.
10. Hazarika S, Chakravarthy J, Cooper J "Minimally invasive locking plate osteosynthesis for fractures of distal Tibia—Results in 20 patients". Injury 2006; 37(9): 877-887.
11. Kenneth A. Egol, Russell Weisz, Rudi Hiebert, Nirmal C. Tejwani, Kenneth J. Koval, and Roy W. Sanders "Does Fibular Plating Improve Alignment After Intramedullary Nailing of Distal Metaphyseal Tibia Fractures?";J Orthop Trauma 2006;20:94–10310.AO Manual: Distal Tibia Fibula, 2008.
12. Collinge C, Kuper M, Larson K, Protzman R "Minimally Invasive Plating of High-Energy

- Metaphyseal Distal Tibia Fractures”. J Orthop Trauma; July 2007; 21(6): 355-360.
13. Kasper W, Janssen & Jan Biert & Albert van Kampen “Treatment of distal tibial fractures: plate versus nail A retrospective outcome analysis of matched pairs of patients”; International Orthopaedics (SICOT) (2007) 31:709–714
 14. Lau T, Leung F, Chan F, Chow S, “Wound complication of minimally invasive plate osteosynthesis in distal tibia fractures”. IntOrthop. 2008; 32(5): 697–703.
 15. Krishan A, Peshin C, Singh D. Intramedullary nailing and plate osteosynthesis for fractures of the distal metaphyseal tibia and fibula. Journal of Orthopaedic Surgery. 2009 Dec;17(3):317-20.
 16. Ronga M, Longo U, Maffulli N “Minimally Invasive Locked Plating of Distal Tibia Fractures is safe and Effective”. ClinOrthopRelat Res. 2010; 468(4): 975–982.
 17. Mohamed Sukeik, Michael Maru, Cathy Lennox “Minimally Invasive Plate Osteosynthesis Of Distal Tibial Fractures: A Multicentred Review”; *J. Orthopaedics* 2010;7(1)e7
 18. Ehlinger M, Adam P, Gabrion A, Jeunet L, Dujardin F, Asencio G. Sofcot “Distal quarter leg fractures fixation: The intramedullary nailing alone option”. Orthop Traumatol Surg Res. 2010; 96(6): 674-82.
 19. Guo J, Tang N, Yang H, Tang T. “A prospective, randomised trial comparing closed intramedullary nailing with percutaneous plating in the treatment of distal metaphyseal fractures of the tibia”. J Bone Joint Surg Brit 2010; 92-B (7):984-988.
 20. Shrestha D, Acharya BM, Shrestha PM “Minimally Invasive Plate Osteosynthesis with Locking Compression Plate for Distal Dia metaphyseal Tibia Fracture”; *Kathmandu Univ Med J* 2011;34(2)628.
 21. M Aslam Siddiqui, Maratib Ali, M. Frooq Mamji, S M Tariq, Ata Ur Rehman “Treatment Of Distal Tibia Fibula Fractures With Intramedullary Nailing & Plate Fixation”; J. Pakistan Orthopaedic Association, Oct 2011, vol 23 no 3, 105-7
 22. Aksekili MA, Celik I, Arslan AK, Kalkan T, Uğurlu M. The results of minimally invasive percutaneous plate osteosynthesis (MIPPO) in distal and diaphyseal tibial fractures. Acta orthopaedica et traumatologica turcica. 2012;46(3):161-7.
 23. Mauffrey C, McGuinness K, Parsons N, Achten J, Costa ML. A randomised pilot trial of “locking plate” fixation versus intramedullary nailing for extra-articular fractures of the distal tibia. J Bone Joint Surg Br. 2012 May 1;94(5):704-8.
 24. Johner R, Wruhs O. Classification of tibial shaft fractures and correlation with results after rigid internal fixation. Clinical orthopaedics and related research. 1983 Sep (178):7-25.