

To Derive the Significance of Thin/Thick Meconium Staining at Sri Aurobindo Medical College and Post Graduate Institute, Indore

Dr. Sujata Badoniya¹, Dr. Eshu Dixit^{2*}, Dr. Ratnamala Thakur³

^{1,2}Junior Resident, Dept. of Obstetrics & Gynecology, Sri Aurobindo Medical College and Post Graduate Institute, Indore, India

³Dept. of Obstetrics & Gynecology, Sri Aurobindo Medical College and Post Graduate Institute, Indore, India

Original Research Article

*Corresponding author

Dr. Eshu Dixit

Article History

Received: 10.07.2018

Accepted: 15.07.2018

Published: 30.07.2018

DOI:

10.36347/sjams.2018.v06i07.029



Abstract: This Study is conducted in Sri Aurobindo Medical College and Post Graduate Institute, Indore in department of obstetrics & gynecology. During the study period from January 2016 to June 2017. Study shows that 2 (4%) newborn had meconium aspiration syndrome, both case are affected with thick meconium stained liquor. No MAS occurred in thin and moderately stained group. on Statistical analysis it was seen that meconium aspiration syndrome was not significantly increased (P value > 0.05) in cases with thick meconium stained liquor when compared to moderately stained liquor but there was an increased tendency. Meconium aspiration syndrome (MAS) is a life threatening complication in cases with meconium stained liquor.

Keywords: Meconium, Staining, Thick & Thin.

INTRODUCTION

Meconium, the gastrointestinal excreta of fetus was named by Aristotle[1]. The word meconium is derived from Greek “mekonion” meaning “from poppy” or “like opium”. He believed that the substance caused sleeping state of the fetus in the mother’s womb.

Meconium is the earliest stool of a mammalian infant. Unlike later feces, meconium is composed of materials ingested during the time the infant spends in the uterus: intestinal epithelial cells, lanugo, mucus, amniotic fluid, bile, and water. Meconium, unlike later feces, is viscous and sticky like tar, its color usually being a very dark olive green; it is almost odorless.

When diluted in amniotic fluid, it may appear in various shades of green, brown, or yellow. It should be completely passed by the end of the first few days after birth, with the stools progressing toward yellow (digested milk)[2].

Meconium aspiration syndrome (MAS) accounts for 28 to 40 per cent of neonatal mortality[3]. Understanding of pathogenic mechanisms in MAS has undergone changes over the years. The resultant effect has been on the management strategies adopted in a neonate delivered after MSAF. The main lacuna in the understanding of pathogenic mechanism of passage of meconium during the process of labour has been the nature of the triggering factor. The earlier concept that there is a direct correlation with foetal hypoxia has not been proved. Further, the management of a newborn, born after MSAF labour has also been controversial with many different protocols without proper control studies. This prospective study was aimed at evaluation

of neonates delivered after meconium staining of amniotic fluid and the management protocol adopted.

MATERIALS AND METHODS

The present study was conducted at Sri Aurobindo Medical College and Post Graduate Institute, Indore, during the period of 18 Months from 01/01/2016 to 30/06/2017. Cases were selected from expectant mothers who were admitted for confinement in the department of Obstetrics & Gynaecology.

Inclusion Criteria

- Patient in active phase of labor
- Term pregnancy
- Post-term pregnancy
- Singleton fetus-Cephalic presentation

Exclusion Criteria

- Post- term Pregnancy(more than 42 weeks)

- Pregnancy with hypertension
- Post caesarean pregnancy
- Multiple pregnancy
- Ante partum hemorrhage
- Diabetes in pregnancy
- Abnormal presentation.
- Cephalic-pelvic disproportion
- PROM

During the study period, total number of deliveries were 3500, out of which 904 cases with OR without Intra-partum meconium staining were selected for the study, following exclusion criteria.

Study Group (Group1), comprised of 100 cases with Intra- partum meconium stained liquor Control Group (2), comprised of 804 cases with clear liquor in the intrapartum period .

Following selection of the cases, a detailed history was obtained as per proforma recorded in the labour room including age, parity, past obstetrical, medical, surgical history, history of present pregnancy for any abnormality and whether the labour was spontaneous or induced. General and systemic examination was done to rule out antecedent/ gestationally induced complication. Thorough per abdominal examination was done to find out the height of fundus, presentation, position, amount of liquor, expected fetal weight and gestational age of fetus. Assessment of cervix and pelvis; and station of head

were also recorded. Use of any medication like Antibiotic, oxytocin, analgesics and sedatives were noted.

Time of rupture of membranes and appearance of meconium were noted, whether meconium appeared either at the time of rupture of the membranes or after sometime during the course of labour. A speculum examination was done with aseptic precautions to collect the meconium stained liquor over the speculum and transferred to a test tube for clinical gradation depending on the consistency and colour. Liquor light green in colour, was considered as thin staining; yellow as moderately thick and deep green as thickly stained .At the time of detection of meconium stained liquor, position and station of the head, effacement and dilation of the cervix was noted.

Fetal heart rate was auscultated every 15 minutes with stethoscope /± Doppler recorded. During labour any complication of cord & placenta were noted. Presences of Paediatrician was assured during delivery with or without MSL Timely Oropharyngeal and/or nasopharyngeal/laryngoscopic suction was done. Endotracheal intubation was done according to the condition of the newborn. Condition of the newborn was assessed by APGAR score at 1 min, 5 min, and 10 min. after birth.

OBSERVATION & RESULTS

Table – 01: Correlation of different grades of meconium staining and meconium aspiration syndrome (MAS)

Group	Numbers of cases	Meconium aspiration syndrome
Thin staining	50(50%)	0(0%)
Moderate staining	26(26%)	0(0%)
Thick staining	24(24%)	2(8.33%)
Total	100	2

Table – 01 shows that 2 newborn had meconium aspiration syndrome, both case are affected with thick meconium stained liquor. No MAS in thin and moderately stained group.

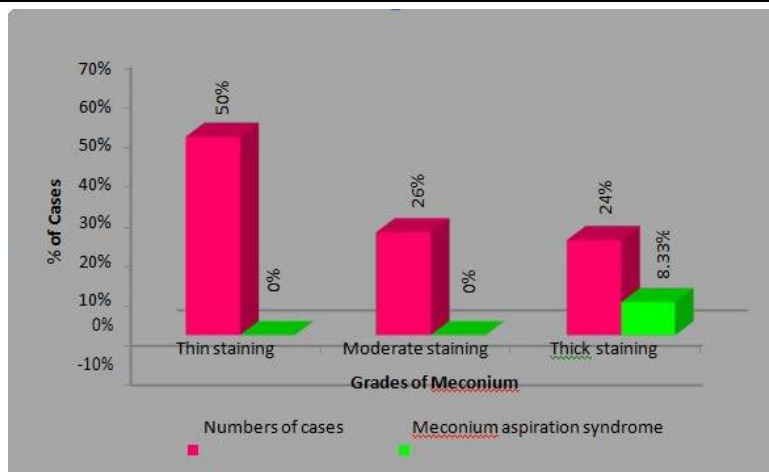
Statistical analysis was done, it was seen that meconium aspiration syndrome was not significantly increased (N2-value= 5.96,p-value=0.06, P value > 0.05) in cases with thick meconium stained liquor when compared to moderately stained liquor but there was an increased tendency.

DISCUSSION

It shows that 2 (4%)newborn had meconium aspiration syndrome, both case are affected with thick meconium stained liquor. No MAS occurred in thin and moderately stained group. on Statistical analysis it was seen that meconium aspiration syndrome was not significantly increased (P value > 0.05) in cases

with thick meconium stained liquor when compared to moderately stained liquor but there was an increased tendency. Meconium aspiration syndrome (MAS) is a life threatening complication in cases with meconium stained liquor.

The “thickness” of meconium had a direct bearing on the neonatal outcome[4]. All cases of MAS were seen in thick meconium compared to thin meconium. No statistical significant were found but there was increased tendency of meconium aspiration syndrome in thick meconium similarly according to Elena M *et al.*[5] 73% of newborns who had meconium aspiration syndrome were delivered through thick meconium. Only thick meconium as a single varibale appeared to be the most significant factor influencing fetal outcome as found by Starks *et al.*[6].



Graph-01:Correlation of different grades of meconium staining and meconium aspiration syndrome (MAS)

CONCLUSION

It is concluded from my study that some important steps taken at right time can reduced MAS and perinatal morbidity later neonatal death.

A selective aggressive approach to the neonate, exposed to MSL resulting in reduction of neonatal intubation and reduces MSA.

In study group fetal heart rate irregularity occurred in 24% in thick meconium out of 100 cases as compare to control group.

REFERENCES

1. Grand RJ, Watkins JB, Torti FM. Development of the human gastrointestinal tract. A review. *Gastroenterology*. 1976; 70:790-810.
2. Peng TCC, Gutcher GR, Van Dorsten JP. A selective aggressive approach to the neonate exposed to meconium-stained amniotic fluid. *Am J Obstet Gynecol* 1996; 175:296-303.
3. Holtzman BR, Banzhaf WC, Silver RK, Hageman RJ. Perinatal management of meconium stained amniotic fluid. *Clin Perinatol*. 1989;16:825–838.
4. Unnisa S, Sowmya BS, Rao SB, Rajagopal K. Maternal and fetal out come in meconium stained amniotic fluid in a tertiary centre. *International Journal of Reproduction, Contraception, Obstetrics and Gynecology*. 2017 Feb 23;5(3):813-7.
5. Rossi EM, Philipson EH, Williams TG, Kalhan SC. Meconium aspiration syndrome: intrapartum and neonatal attributes. *American Journal of Obstetrics & Gynecology*. 1989 Nov 1;161(5):1106-10.
6. Starks GC. Correlation of meconium-stained amniotic fluid, early intrapartum fetal pH, and Apgar scores as predictors of perinatal outcome. *Obstetrics and gynecology*. 1980 Nov;56(5):604-9.