

A Study of Correlation of Cutaneous Lesions in Neonates with Their Gestational Age at Birth in a Tertiary Care Hospital

Avdhut B Deshpande^{1*}, Sunil N Tolat²¹Assistant Professor, PIMS & R, Islampur, Maharashtra, India²Associate Professor, BJMC, Pune, Maharashtra, IndiaDOI: [10.36347/sjams.2019.v07i11.054](https://doi.org/10.36347/sjams.2019.v07i11.054)

| Received: 08.11.2019 | Accepted: 15.11.2019 | Published: 27.11.2019

*Corresponding author: Avdhut B Deshpande

Abstract

Original Research Article

Introduction: Skin is a complex dynamic organ that performs several vital functions. The function and efficacy of new-born skin is strongly related to the maturity of the infant. Neonatal dermatoses can be a cause of great parental anxiety which presents diagnostic and therapeutic dilemma to the health care professional. This study was planned to correlate skin lesions and gestational age of the neonates. **Aim:** Our aim was to correlate the various skin lesions occurring in neonates with their gestational age at birth. **Materials & Methods:** Cross Sectional & prospective study. **Sample size:** 120 neonates (Dermatology OPD, NICU, Pediatric & Postnatal ward of a tertiary hospital, Pune. Percentwise statistical analysis was done to arrive at conclusion. **Results:** Physiological scaling was seen in full term neonates. Physiological jaundice and Harlequin color change was seen in preterm neonates. Epstein pearls, milia, and erythema toxicum neonatorum were seen more in full term neonates. **Conclusion:** We found a definite correlation between some cutaneous lesions and gestational age.

Keywords: cutaneous lesions, neonates, gestational age.

Copyright © 2019: This is an open-access article distributed under the terms of the Creative Commons Attribution license which permits unrestricted use, distribution, and reproduction in any medium for non-commercial use (NonCommercial, or CC-BY-NC) provided the original author and source are credited.

INTRODUCTION

The function and efficacy of new-born skin is strongly related to the maturity of the infant. The full term infant has a well-developed epidermis and dermis, histologically similar to the skin of adult [1]. The barrier properties of the epidermis are excellent, so the infant is well equipped for the transition from the amniotic fluid to air. Dermal structures are well developed too, although there may be a degree of functional immaturity. The premature infant assumes the challenge of an independent life despite immaturity of essential

Functions [2, 6]. All the skin layers are thinner in preterm infant than the term infant. In extremely premature infant the skin is sticky, friable and transparent. The lanugo hairs are absent. As gestation progresses, the skin becomes less transparent and increasingly peeling with surface cracking, indicative of a thickening stratum corneum, while lanugo hair density peaks and then regresses [3]. A thorough knowledge of the neonatal skin biology and better understanding of the principles of infant skin care can minimize risks and costs to this special population [4, 5].

The appearance of the skin can provide clues regarding the health status of the neonate, for example, gestational age or nutritional status. Being aware of common skin lesions found in the neonatal period will alert us to symptoms of systemic or cutaneous disorders. There is a need to develop a care plan to protect the skin from iatrogenic damage. The neonatal period is the first four weeks of extra-uterine life. The infants born before the 37th week of gestation are considered to be premature or preterm. Infants born with weight less than 2500g are considered to be low birth weight infants; this may be due to prematurity or small for age or combination of both. Infants born after 42 weeks of gestation are described as post term, irrespective of birth weight. This expression is often used synonymous with postmaturity [6].

A variety of physiological skin lesions are commonly seen in newborns, they regress spontaneously during first few weeks of life. These lesions include vernix caseosa, acral cyanosis, harlequin color change, cutis marmorata, physiological scaling of the newborn, sucking blisters, occipital alopecia, sebaceous gland hyperplasia, milia, miniature puberty, Mongolian spots, Epstein pearls [7, 8].

Vernix caseosa

The most obvious clinical difference between the skin of the term newborn infant and that of an adult is the presence of the moist, greasy, yellow-white substance called vernix caseosa. It is a coating composed of sebum, keratin and lanugo hairs. It becomes thicker with advancing gestational age and serves as a lubricant and perhaps permeability barrier to protect the newborn skin from amniotic fluid [9].

The strategic location of vernix between the fetal skin and the amniotic fluid suggests a potential role in host defense which is supported by recent reports of antimicrobial proteins present in vernix caseosa, amniotic fluid, and pulmonary surfactant [9]. Lysozyme, lactoferrin, human neutrophil peptides 1-3 and secretory leucocyte protease inhibitors are antimicrobial peptides secreted in amniotic fluid. Antimicrobial peptides are concentrated in discrete, organized, acellular "granules" embedded in the vernix lipid matrix. Structurally and functionally, therefore vernix may be similar to breast milk, which also contains a galore of innate immune molecules and is evolutionarily derived from epidermal lipid secretory glands.

Physiological scaling of new-born

The excess outermost layers of stratum corneum are shed during initial few days of neonatal life. It occurs in majority of normal neonates [11]. Timing of scaling is dependent on gestational age. Most full term infants will have fine desquamation of skin at 24 to 48 hours of age [6, 12]. Premature infants do not show desquamation until 2 to 3 weeks of life. Post mature infants often experience thicker peeling.

Sebaceous gland hyperplasia

Sebaceous gland hyperplasia is a physiological event in the new-born, reflecting the influence of maternal androgens. It is visible to the naked eye in the great majority of infants as multiple, uniform, pinpoint yellowish papules. These are most prominently seen on the nose, cheeks, upper lip and forehead, but may also be visible on the upper trunk, especially around areola, the genitalia and the limbs [10]. Premature infants are less affected, but sebaceous hyperplasia occurs in nearly half of term new-borns. Sebaceous hyperplasia spontaneously involutes in the first few weeks of life.

Milia

Milia are small inclusion cysts within the epidermis that contain concentric layers of trapped keratinized stratum corneum. Clinically, they are tiny

(up to 2mm), white, smooth-surfaced papules, which are usually discrete, and their numbers may vary from a few to several dozen. Milia resolve spontaneously in several months and usually do not require any treatment.

Epstein's pearls and bohn's nodules

Epstein's pearls and Bohn's nodules are microkeratocytes derived from dental lamina. Both of these epidermal cysts occur in keratinized mucous membranes and form along embryonic lines of fusion [6]. When on palate they are called Epstein's pearls and when on the alveolar ridges, Bohn's nodules. Diagnosis is mainly clinical. They follow the same course as milia.

METHODS

This was a hospital based cross sectional study conducted in a tertiary care hospital. It included 120 neonates attending the dermatology Out Patient Department and neonates admitted in Neonatal Intensive Care Unit, pediatric and postnatal ward of the teaching hospital. A detailed history of neonatal skin lesions regarding onset and duration was taken from parents. A thorough clinical examination of all neonates along with following relevant investigations in selected cases was performed.

Neonates within first 4 weeks of life irrespective of gestational age, sex, and mode of delivery were included in the study. Exclusion Criteria: Mothers not willing to give consent for relevant investigations of neonates.

Relevant history was recorded in detail especially age of the mother, parity of mother, history of consanguinity, mode of delivery and history of maternal illness during pregnancy. The neonates were examined thoroughly in day light with accurate definition of morphology of skin lesions and findings were recorded. The sex, birth weight and age at the time of examination were noted in each case. In most instances, diagnosis of disorder was based on clinical impression.

RESULTS

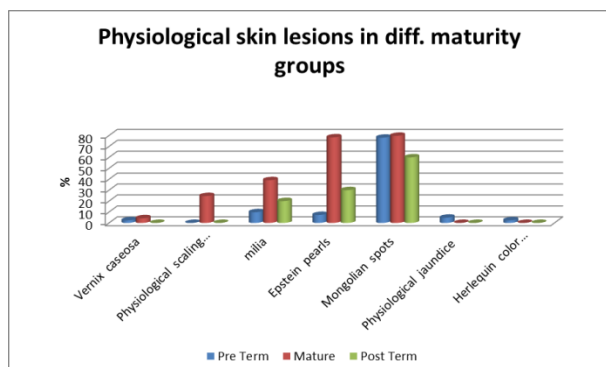
Of 120 newborns, 64 (53.3%) were males, 56 (46.7 %) were females, these, 69 (57.5 %) were born at term, 41 (34.2 %) were preterm, 10 (8.3%) were postterm.

Table-1: Sex ratio in newborns

| Gender | No | % |
|--------|-----|------|
| Male | 64 | 53.3 |
| Female | 56 | 46.7 |
| TOTAL | 120 | 100 |

Table-2: Maturity of neonates

| Maturity | No | % |
|----------------------|-----|------|
| PRE TERM | 41 | 34.2 |
| MATURE (TERM) | 69 | 57.5 |
| POST TERM | 10 | 8.3 |
| Total | 120 | 100 |

**Graph-1: Percentage of physiological skin lesions in neonates with correlation to maturity**

Physiological jaundice of newborn was seen in 2(1.7%) babies both of whom were preterm. Nobbay *et al.* reported 103 cases of jaundice amongst 500 cases with no reference to gestational age [13].

Skin lesions were commonly seen in full-term neonates (57.5%), followed by preterm (34.2%), and post-term (8.3%) neonates.

We found a definite correlation between some cutaneous lesions and gestational age. Physiological scaling was seen in full term neonates. Physiological jaundice and Harlequin color change was seen in preterm neonate. Epstein pearls, milia, and erythema toxicum neonatorum were seen more in full term neonates.

DISCUSSION

Skin is the largest organ in the body. It comprises approximately 13% of body weight in the neonate as compared to 3% of the bodyweight of the adult. Just as the other organs are immature with decreasing gestational age, the skin also is immature; however, with exposure to the postnatal environment, skin undergoes rapid changes to enhance maturation. Skin plays an important role in fluid balance and temperature regulation. Mature skin acts as a barrier to invading microbes, while immature skin may systemically absorb substances that result in adverse effects.

The appearance of the skin can provide clues regarding the health status of the neonate, for example, gestational age or nutritional status. Being aware of common skin lesions found in the neonatal period will alert us to symptoms of systemic or cutaneous disorders.

Evolution of neonatal skin diseases is much more rapid compared to adults. Some apparently serious skin lesions turn out to be trivial and vice versa. Many transient phenomena have been clinically recorded on neonatal skin but remain poorly understood. A thorough knowledge of the neonatal skin biology and the cutaneous lesions is expected from those providing neonatal care.

Physiological jaundice of newborn was seen in 2(1.7%) babies both of whom were preterm. Nobbay *et al.* Reported 103 cases of jaundice amongst 500 cases with no reference to gestational age [13].

An epidemiological study by Dash *et al.* conducted at Bangalore, India has shown that, certain conditions like Epstein pearls, lanugo hair, icterus, perianal dermatitis and cradle cap have higher incidence in preterm neonates [8]. Harlequin color change was seen in 1(0.8%) baby who was preterm. This finding is consistent with the fact that premature infants are more commonly affected than full term infants [6].

Physiological scaling was seen in 17 (14.2%) neonates in the present study, compared to a study of Australian neonates, where the frequency of occurrence was 65%[14]. It was seen in 17 (24.6%) full-term neonates, compared to other studies, where desquamation was not seen in preterm neonates [8, 15].

Vernix caseosa was seen in 4 (3.3%) neonates. It was observed most commonly on 1st day of life. Vernix caseosa was seen in 7.7% neonates in the study conducted by Haveri F and Inamdar A [6, 16].

Milia was seen in 33 (27.5%), similar to that of Indian studies by Kulkarni *et al.* and Meenakshi *et al.*[17, 18].

ACKNOWLEDGEMENTS

We are grateful to all the participants in the study. Our sincere gratitude to our institutional support to carry out this study.

Ethical approval

The study was approved by the institutional ethics committee

REFERENCES

1. Rutter N. Physiology of new-born skin. In: Harper J, Oranje A, Prose N, editors. Textbook of

- pediatric dermatology. Oxford: Blackwell Science. 2000: 43-47.
2. Kalia YN, Nonata BL, Lund CH. Development of skin barrier functions in premature infants. *J Invest Dermatol.* 1998; 111:320-26.
 3. Gilliam AE, Williams ML. Skin of premature infant. In: Eichenfield LF, Frieden IJ, Esterly NB, editors. *Textbook of neonatal dermatology.* 2nd ed. London: Saunders. 2008. 45-58.
 4. Qiang MM, Feingold KR, Thornfeldt CR, Elias PM. Optimization of physiological lipid mixtures for barrier repair. *J Invest Dermatol.* 1996; 106:1096-1101.
 5. Darmstadt GL, Dinulos JG. Neonatal skin care. *Pediatr Clin North Am.* 2000;47(4):757-82.
 6. Deshpande AB, A clinical study of physiological skin manifestations in neonates. *IJHSR.* 2019,9(3):43-46
 7. Lucky AW. Transient benign cutaneous lesions in the newborn. In: Eichenfield LF, Frieden IJ, Esterly NB, editors. *Textbook of neonatal dermatology.* 2nd ed. London: Saunders. 2008: 85-97.
 8. Dash K, Grover S, Radhakrishnan S, Vani M. Clinicoepidemiological study of cutaneous manifestations in the neonate. *Ind J Dermatol Venereol Leprol.* 2000;66:26-28.
 9. Bautista MB, Wickett R, Visscher MO, Pickens WL, Hoath SB, Characterization of vernix caseosa as a natural biofilm: comparison to standard oil-based ointments. *Pediatr Dermatol.* 2000;17(4):253-609.
 10. Akinbi HT, Narendran V, Pass AK, Markart P, Hoath SB. Host defense proteins in vernix caseosa and amniotic fluid. *Am J Obstet Gynecol.* 2004;191:2090-96
 11. Atherton DJ, Rook A. The neonate. In: Burns T, Breathnach S, Cox N, Griffiths C, editors. *Textbook of dermatology.* 7th ed. Oxford: Blackwell Science. 2004,14.1-50.
 12. Taieb A, Sandler B. Common transient neonatal dermatoses. In: Harper J, Oranje A, Prose A, editors. *Textbook of pediatric dermatology.* Oxford: Blackwell Science. 2000, 53-63
 13. Nobbay B, Chakrabarty N, Cutaneous manifestations in the newborn, *Indian J Dermatol Venereol Leprol,* 1992;58:69-72.
 14. Rivers JK, Frederiksen PC, Dibdin C. A prevalence survey of dermatoses in the Australian neonate. *J Am Acad Dermatol,* 1990;23(1):77-81.
 15. Moosavi Z, Hosseini T. One year survey of cutaneous lesions in 1000 consecutive Iranian newborns. *Pediatr Dermatol,* 2006;23:61-63.
 16. Haveri F, Inamdar A. A Cross-Sectional Prospective Study of Cutaneous lesions in Newborn. *ISRN Dermatol.* 2014; 2014:360590.
 17. Kulkarni ML, Singh R. Normal variants of skin in neonates. *Indian J Dermatol Venereol Leprol.* 1996; 62:83-86.
 18. Meenakshi S, Surjeet K, Madhu N, Dewan SP. Cutaneous lesions in new-born. *Indian J Dermatol Venereol Leprol.* 2002; 68:334-33786.