

Megaesophagus and Esophageal Cancer

Rahaoui A*, Benelbarhdadi I, Abdelwaly K, Lagdali N, Berhili C, Borahma M, Ajana FZ

Gastro-Enterology and Hepatology Department, University/Organization: University Mohamed V /CHU Ibn Sina Morocco

DOI: [10.36347/sjams.2020.v08i01.036](https://doi.org/10.36347/sjams.2020.v08i01.036)

| Received: 10.01.2020 | Accepted: 18.01.2020 | Published: 22.01.2020

*Corresponding author: Rahaoui Anass

Abstract

Review Article

Achalasia or megaesophagus is a pathology predisposing to the occurrence of squamous cell carcinoma and adenocarcinoma of the esophagus. The diagnosis is often made late. The first-line paraclinical workup should include esogastroduodenal fibroscopy with biopsies to confirm the diagnosis. **Materials and methods:** Retrospective study over a period of 18 years collecting all the patients followed in our department. The diagnosis of megaesophagus was made by esophageal manometry. **Results:** Among 104 patients followed for megaesophagus, only one patient developed a squamous cell carcinoma on achalasia, that is a prevalence of 0.96%. This is a 44-year-old patient who is non smoker, or who consumes alcohol and who has had functional dysphagia since the age of 5 and in whom esophageal manometry had demonstrated an aperistalsis of the esophageal body with hypertonia and lack of relaxation of the LES. This dysphagia became 39 years later marked with solids and semi-liquids, a constant progressive associated with odynophagia and weight loss of 07 kg in 2 months. The clinical examination was without particularities. Esogastroduodenal fibroscopy objectified ulcerative stenosing cauliflower mass of the lower esophagus. The anatomopathological study of the biopsies revealed a well differentiated, mature and infiltrating squamous cell carcinoma of the lower esophagus. A thoraco-abdomino-pelvic CT scan revealed a tumor of the lower stenosing esophagus classified T3N0M0. The patient received exclusive radiochemotherapy. **Conclusion:** The megaesophagus is a risk factor for the development of squamous cell carcinoma of the esophagus. The prevalence in our series is 0.6% of cases. The clinician must be aware of this association so that prevention programs and treatment are not delayed.

Keywords: megaesophagus-cancer-esophagus.

Copyright © 2020: This is an open-access article distributed under the terms of the Creative Commons Attribution license which permits unrestricted use, distribution, and reproduction in any medium for non-commercial use (NonCommercial, or CC-BY-NC) provided the original author and source are credited.

INTRODUCTION

The achalasia or megaesophage is considered by many authors as a condition predisposing to the occurrence of esophageal squamous carcinoma. The prevalence and prognosis of this cancer vary according to studies. The diagnosis is made often late before a progressive worsening with weight loss dysphagia. Paraclinical record must include first-line a fibroscopy with biopsies to confirm the diagnosis [4].

Objectives: study incidence and prognosis of esophageal cancer and the etiological factors.

OBSERVATION

Mr. O, A, 44 unknown years smoking, or consumer of alcohol, which has a low dysphagia of functional allure (intermittent, unpredictable, paradoxical, without odynophagie), since the age of 5 years it has become painful for 2 months, to the solid and semi liquid, progressive, constant, associated with a weight loss of 07 kg in 2 months. Clinical examination

found a patient eupneique, apyretique, stable in hemodynamic terms with good condition général(oms=0,IMC à 21.7 kg/m²). The somatic exam was without characteristics. The oesogastroduodenale (FOGD) fibroscopy objectified a tumor process of the lower esophagus CD-budding extended between 30 to 39 cm of dental arches (AD), range (Figure 1).

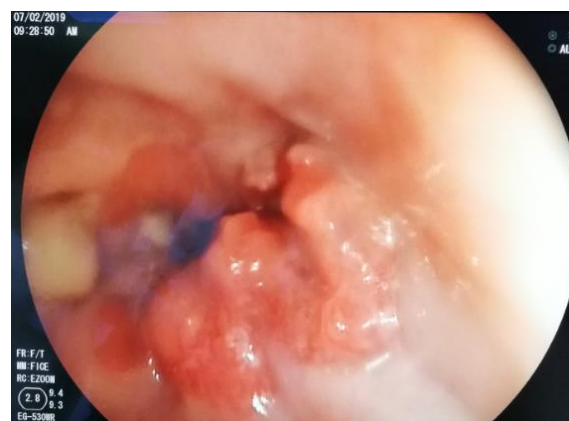

Fig-1: Process esophageal endoscopic

The manometric study confirms achalasia. The pressure of the lower sphincter esophagus (S.I.O.) not explored given the tumor of the lower esophagus.

No rolling of Peristaltic waves spontaneous activity (Figure 2).

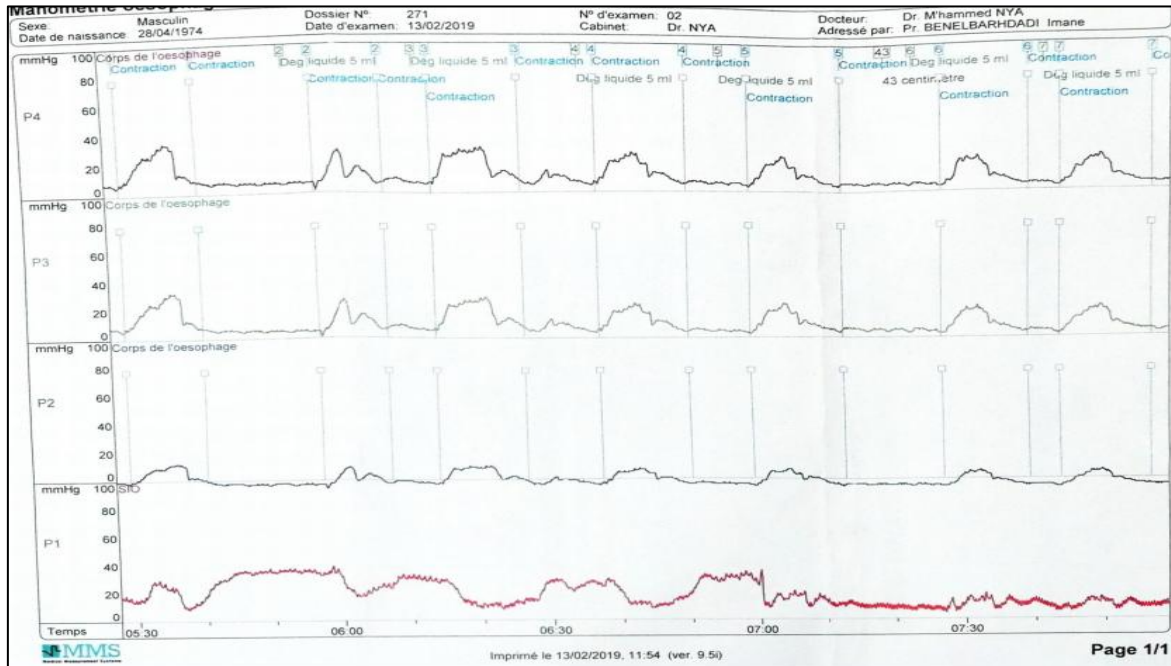


Fig-2: Esophageal manometry

The pathological study of carried out biopsies of the tumoral process during the FOGD objectified a mature, well-differentiated epidermoid carcinoma and cancer of the lower esophagus. An assessment of the

expansion was achieved with a best-abdominal-pelvien scanner which is in favour of a tumor process of the lower esophagus stenasant class T3N0M0 (Figure 3 and 4).

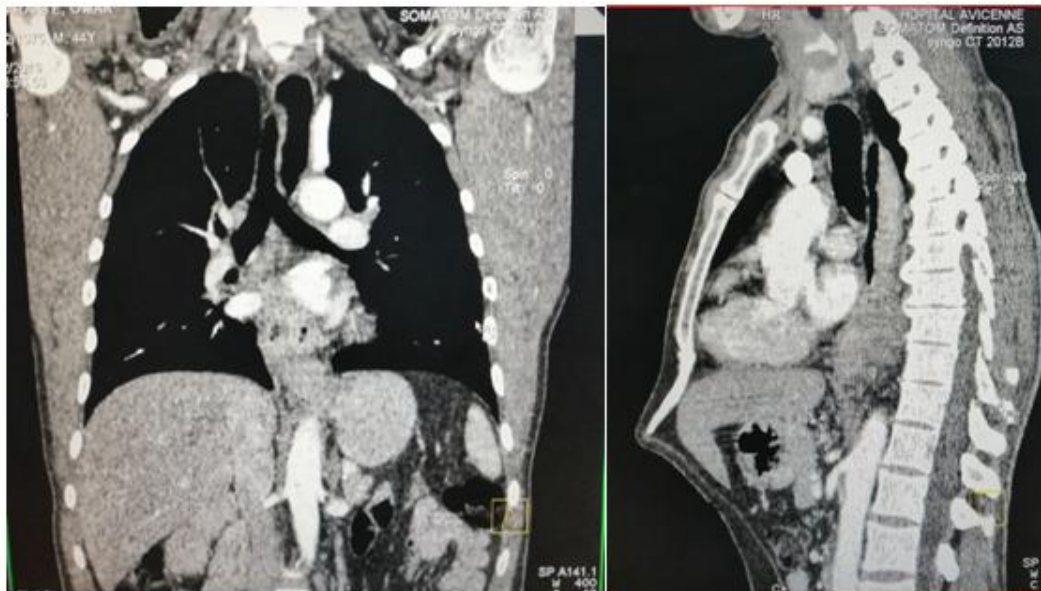

Fig-3, 4: Image scannographique showing the esophageal process

It should be noted that the patient had been given a transit oeso-gastro-duodenal (TOGD) which showed stenosis of the lower esophagus of irregular

appearance "Apple core" in favour of a suspicious lesion (Figure 5).

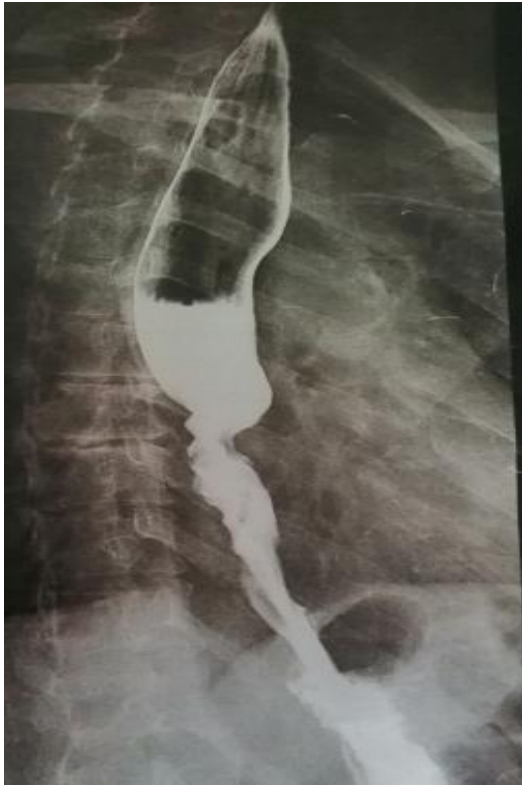

Fig-5: Transit oesogastrodeodenal showing a stenosis in Apple core

DISCUSSION

Esophageal cancer affects more than 4,50,000 persons worldwide, and its incidence has increased in recent years. It is the eighth most common cancer across the globe. Nearly four out of five cases occur in nonindustrialized nations, with the highest rates in Asia and Africa. The National Cancer Institute has estimated 16,910 new cases of esophageal cancer and 15,910 deaths from the disease in 2016. In the majority of countries, the estimated range of 5-year survival in patients with esophageal cancer is from 15% to 25%. In most cases, the outcome is poor and the mortality rate is high.

There are two main histologic types of esophageal cancer: esophageal squamous cell carcinoma (ESCC) and esophageal adenocarcinoma (EA). The incidence, ethnic pattern, and geographic distribution of the two pathologies are significantly heterogeneous. ESCC is the most frequent histologic subtype worldwide and more frequently presents in underdeveloped countries, whereas EA is the histologic subtype in up to 50% of the cases of esophageal cancer in Western countries, and its incidence has increased rapidly.

The most widely accepted explanation for that phenomenon is the elevated prevalence of obesity,

illustrated by the fact that the risk of EA is three times higher in obese subjects [4].

The incidence and prevalence of carcinoma squamous at the achalasia patient vary widely in the literature. The prognosis of the association "achalasia-cancer" is generally bad. However, there are few studies assessing incidence, prevalence and prognosis of the patients with the association 'achalasia-cancer'. A study done by Björn Lucas showed that patients with achalasia especially if the latter is known for a long time, the risk of developing cancer of the esophagus is increased to about 140 times compared to the general population. With good surveillance, we could detect cancer at a stage of the early patients whose prognosis is not worse than that of patients with cancer without achalasia esophageal squamous [3].

The diagnosis of achalasia is late in carcinomatous patients due to many years of dysphagia. The study by F. Tustumi, aims to assess the incidence and prevalence of the ADK and CE achalasiques patients is based databases until January 2017 in order to perform a systematic review and meta-analysis.

This study aims to estimate the risk of esophageal adenocarcinoma and squamous cell carcinoma in achalasia patients. We searched for association between carcinoma and esophageal achalasia in databases up to January 2017 to perform a systematic review and meta-analysis.

A total of 1,046 studies were identified from search strategy, of which 40 were selected for meta-analysis. A cumulative number of 11,978 esophageal achalasia patients were evaluated. The incidence of squamous cell carcinoma was 312.4 (StDev 429.16) cases per 100,000 patient-years at risk. The incidence of adenocarcinoma was 21.23 (StDev 31.6) cases per 100,000 patient-years at risk. The prevalence for esophageal carcinoma was 28 carcinoma cases in 1,000 esophageal achalasia patients (CI 95% 2, 39). The prevalence for squamous cell carcinoma was 26 cases in 1,000 achalasia patients (CI 95% 18, 39) and for adenocarcinoma was 4 cases in 1,000 achalasia patients (CI 95% 3, 6). The absolute risk increase for squamous cell carcinoma was 308.1 and for adenocarcinoma was 18.03 cases per 100,000 patients per year. To the best of our knowledge, this is the first meta-analysis estimating the burden of achalasia as an esophageal cancer risk factor. The high increased risk rate for cancer in achalasia patients points to a strict endoscopic surveillance for these patients. Also, the increased risk for developing adenocarcinoma in achalasia patients suggests fundoplication after myotomy, to avoid esophageal reflux and Barrett esophagus, a known risk factor for adenocarcinoma [7].

Table-I: Reported incidence of “achalasia-carcinoma” in the recent literature [3]

Study	Year	Length of investigation (years)	No. of patients with achalasia	No. of patients who developed esophageal cancer at follow-up	Cancer incidence/ patient-years of follow-up	Estimated increase in esophageal cancer risk	Average duration between first achalasia symptoms and esophageal cancer (years)
Wychulis [2]	1971	32	1318	7	1/2443	X7	28.4
Chuong [5]	1984	17	91	0	0/935	X0	--
Peracchia [9]	1991	21	244	1	1/1200	X16.6	9
Aggestrup [10]	1992	35	66	10	1.375	X26.9	--
Meijssen [8]	1992	15	195	3	1/293	X32.9	17
Sandler [11]	1995	--	1062	24	1/9864	X16	--
Streitz [12]	1995	25	241	9	1/1138	X14.5	--
Badaloni [13]	1996	5	281	8	--	--	17.7
Brucher [3]	1998	16	124	4	1/173	X140	32
our study	2019	18	104	1		--	39

Pathophysiology of ESCC in achalasia

Multiple pathophysiologic mechanisms have been related to the development of ESCC in patients with achalasia (Figure 6). One hypothesis is that food stasis promotes lactic acid production and fermentation due to bacterial overgrowth, which stays in the distal portion of the esophagus, causing slow and continuous chronic inflammation, damaging the esophageal mucosa, and predisposing to dysplastic changes.

In addition, a damaged esophageal mucosa is prone to be exposed to food carcinogens, such as

nitrosamines, alcohol, and tobacco. In untreated patients with achalasia, 24-hour pH-study tracing shows episodes of slow elimination reflux or prolonged episodes of acid exposure with no acid elimination. The possible causes of the slow esophageal elimination of acid reflux could be secondary to an aperistaltic esophageal body or to the fermentation of retained food. Episodes of poor acid reflux clearance could also cause lesions. With respect to histologic alterations and dysplasia markers, Chino et al⁴⁵ conducted a study on six patients with achalasia and ESCC, carrying out histologic mapping of.

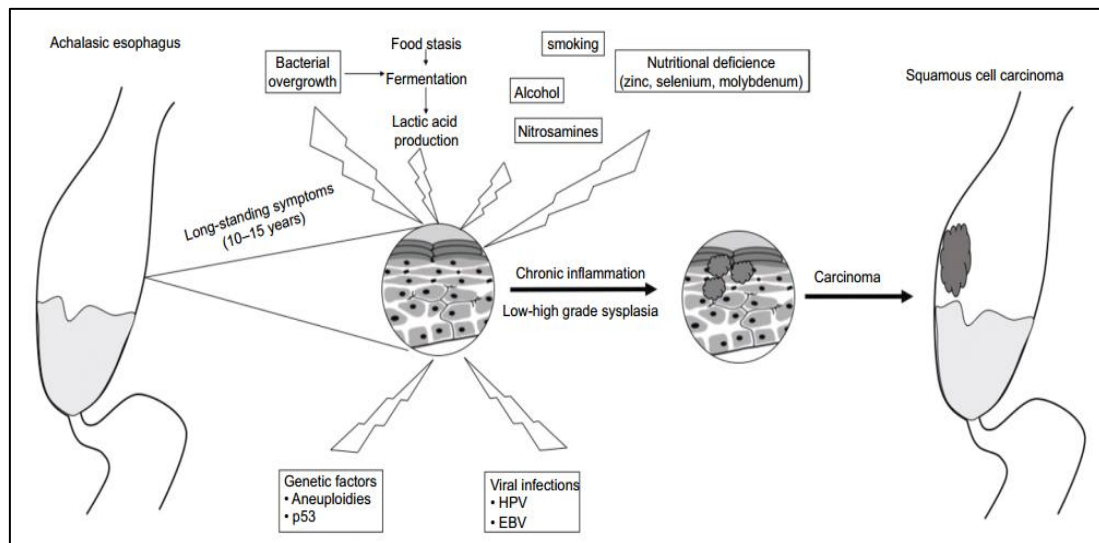


Fig-6: Model representing the pathophysiologic mechanisms related to the development of ESCC in patients with achalasia [4]

The esophageal samples. They reported marked hyperplastic changes in the stratified squamous epithelium and multiple foci of dysplastic changes. The ESCC was well differentiated, with low-grade atypia, closely associated with dysplastic foci. Immunohistochemical staining for p53, p21, p16, and the epidermal growth factor receptor suggested that the dysplastic epithelium was a borderline lesion between hyperplasia and carcinoma in situ. These findings imply that esophageal food stasis induces chronic hyperplasia that finally transforms into malignant epithelial cells of

the esophagus, associated with the dysplasia-carcinoma sequence. Regarding p53, in addition to overexpression in ESCC with achalasia, there are also mutational changes of that tumor suppressor. On occasion, high-grade squamous dysplasia or superficially invasive squamous cell carcinoma is an incidental finding in achalasia patients. Other genetic abnormalities described in ESCC associated with achalasia include mutations that could be associated with advanced megaesophagus due to Chagas disease. A silent mutation at codon 88 of exon 7 of the FHIT gene and a mutation involving exon

6 of the TP53 gene, as well as mutations in exons 5 and 7 of that gene, have been reported. Aneuploidies for chromosomes 7, 11, and 17 may possibly be associated with an increased risk of ESCC. Interestingly, idiopathic achalasia, like non-achalasia-related ESCC, is a disease that is associated with low socioeconomic levels and

poverty. It is postulated that those situations predispose to malnutrition, vitamin deficiencies, and infections that could be related to achalasia (eg, HSV-1 and Epstein-Barr), as well as to ESCC (HPV) [4].

Table-II: Risk factors associated with esophageal squamous cell carcinoma and esophageal adenocarcinoma [4]

Squamous cell carcinoma	Adenocarcinoma
<ul style="list-style-type: none"> •Smoking • Chronic alcohol consumption^a • Caustic injury • Achalasia • Chagas disease • Older age • Male sex • Black race • Tylosis • Previous SCC of the head or neck • Papilloma virus infection • Frequent consumption of hot beverages • Micronutrient deficiencies (zinc, selenium, molybdenum, iron) 	<ul style="list-style-type: none"> • Barrett's esophagus • Obesity • Smoking • Chronic alcohol consumption^a • Older age • Male sex • white race • Previously treated achalasia without anti-reflux therapy • Genetic predisposition

Note: a More than three drinks per day.

Abbreviation: SCC, squamous cell carcinoma

The diagnosis of achalasia is based on clinical arguments, endoscopic and bar(g) [3]. Endoscopy is not the best way to appreciate the dilation of the esophagus and cardia spasm intensity. It is necessary because it allows to eliminate an associated Pathology: esophagitis, cardiac incompetence by hiatal hernia or malposition cardiotuberositaire associated with and she must look for anomalies that can make suspect cancer [1].

The diagnosis is made often late before a progressive worsening with weight loss dysphagia. Paraclinical record must include first-line a fibroscopy with biopsies to confirm the diagnosis. An assessment of tumor extension to distance then local then asked, combining transit oesogastroduodenal sometimes, tracheal fibroscopy, scanner thoracoabdominal, neck ultrasound, positron emission tomography, ultrasonography stock looking for a second location (indirect laryngoscopy with bronchial panendoscopie and fibroscopy for epidermoid carcinomas), a balancé sheet of operability State of Comorbidities and a nutritional report. Even if the stage tumor-nodes-metastases (pTNM) pathological remains the reference for the assessment of prognosis [6]. Treatment of carcinoma on achalasia is stackable to cancer of the esophagus [1].

CONCLUSION

Achalasia is idiopathic motor disorder of the esophagus due to the absence of esophageal body peristalsis and failure of relaxation of the lower esophageal sphincter, is a risk factor for the

development of the squamous cell carcinoma. Adenocarcinoma. Many mechanisms are related to the development of EC in achalasia: include the proliferation of bacteria, food stasis, the genetic alterations and chronic inflammatory diseases. Regarding the risk of AE in patients with achalasia, most of the cases are associated with esophagitis of Barrett, because of uncontrolled chronic acid reflux. The clinician must be aware of these associations to ensure early prevention programs and treatment.

REFERENCES

1. Brun M, Moulinier B, Maiza E, Partensky C. Un cas de cancer épidermoïde superficiel développé sur méga-œsophage. *Acta endoscopica*. 1986 Apr 1;16(2):129-32.
2. Wychulis AR, Woolam GL, Andersen HA, Ellis FH. Achalasia and carcinoma of the esophagus. *Jama*. 1971 Mar 8;215(10):1638-41.
3. Brücher BL, Stein HJ, Bartels H, Feussner H, Siewert JR. Achalasia and esophageal cancer: incidence, prevalence, and prognosis. *World journal of surgery*. 2001 Jun 1;25(6):745-9.
4. Torres-Aguilera M, Troche JM. Achalasia and esophageal cancer: risks and links. *Clinical and experimental gastroenterology*. 2018;11:309.
5. Chuong JJ, DuBovik S, McCallum RW. Achalasia as a risk factor for esophageal carcinoma. *Digestive diseases and sciences*. 1984 Dec 1;29(12):1105-8.
6. Mariette C, Balon JM, Maunoury V, Taillier G, Van Seuning I, Triboulet JP. Value of endoscopic ultrasonography as a predictor of long-

- term survival in oesophageal carcinoma. *British journal of Surgery*. 2003 Nov;90(11):1367-72.
7. Tustumi F, Bernardo WM, da Rocha JR, Szachnowicz S, Seguro FC, Bianchi ET, Sallum RA, Ceconello I. Esophageal achalasia: a risk factor for carcinoma. A systematic review and meta-analysis. *Dis Esophagus*. 2017 Oct 1;30(10):1-8.
 8. Siersema PD, Dees J, Tilanus HW, Kok TC, Hordijk ML, von Blankenstein M, Rotterdam Oesophageal Tumour Study Group. Early detection and treatment of oesophageal and gastric cancer. *The Netherlands journal of medicine*. 1995 Aug 1;47(2):76-86.
 9. Meijssen MA, Tilanus HW, Van Blankenstein M, Hop WC, Ong GL. Achalasia complicated by oesophageal squamous cell carcinoma: a prospective study in 195 patients. *Gut*. 1992 Feb 1;33(2):155-8.
 10. Peracchia A, Segalin A, Bardini R, Ruol A, Bonavina L, Baessato M. Esophageal carcinoma and achalasia: prevalence, incidence and results of treatment. *Hepato-gastroenterology*. 1991 Dec;38(6):514-6.
 11. Aggestrup S, Holm JC, Sørensen HR. Does achalasia predispose to cancer of the esophagus?. *Chest*. 1992 Oct 1;102(4):1013-6.
 12. Sandler RS, Nyrén O, Ekblom A, Eisen GM, Yuen J, Josefsson S. The risk of esophageal cancer in patients with achalasia: a population-based study. *Jama*. 1995 Nov 1;274(17):1359-62.
 13. Streitz Jr JM, Ellis Jr FH, Gibb SP, Heatley GM. Achalasia and squamous cell carcinoma of the esophagus: analysis of 241 patients. *The Annals of thoracic surgery*. 1995 Jun 1;59(6):1604-9.
 14. Badaloni AE, Boerr LA, Cenoz MC, Corti RE, Chiocca JC, Kognan Z, Loviscek L, Salis GB, Sivori E, Soifer L. Prevalence of esophageal carcinoma in achalasia in argentina. *Recent Advances in Diseases of the Esophagus*, Peracchia, A, Rosati R, Bonavina L, Fumagalli U, Bona S, Chella B, editors, Milan, Monduzzi Editore. 1996:41-4.