

Combating the Risk of Type 2 Diabetes Mellitus in the Family: The Role of a Family Physician in Evidence-Based Care and Early Intervention. Index Case: A 40-Year-Old Patient with Pre-Diabetes

Ilodibia N¹, Akhidue K^{2*}, Alikor CA², Erere O³

^{1,3}University of Lagos Teaching Hospital, Lagos State Nigeria

²University of Port Harcourt Teaching Hospital, Rivers State Nigeria

DOI: [10.36347/sjams.2020.v08i02.050](https://doi.org/10.36347/sjams.2020.v08i02.050)

Received: 04.02.2020 | Accepted: 18.02.2020 | Published: 23.02.2020

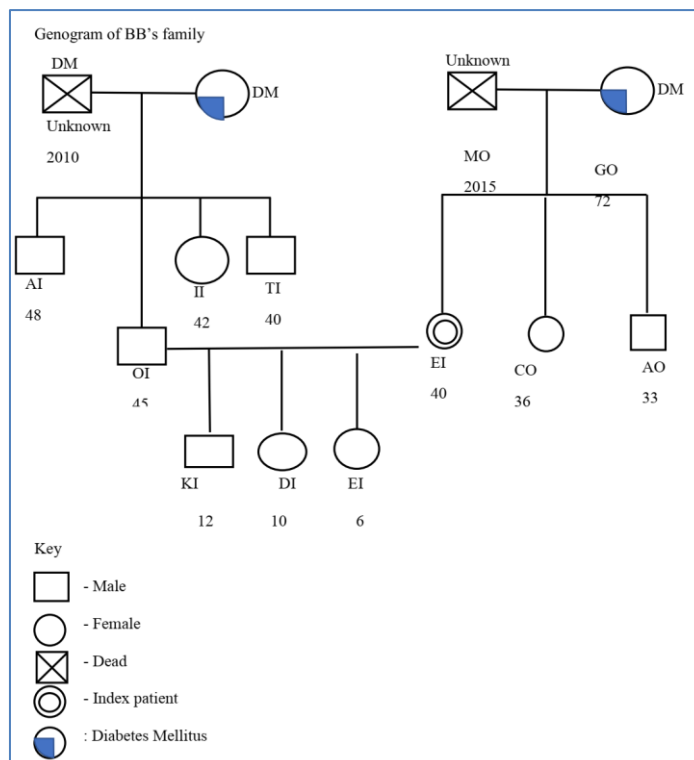
*Corresponding author: Akhidue K

Abstract Review Article

EI was recently diagnosed as having Pre-diabetes evidenced by the presence of acanthosis nigricans, obesity and impaired laboratory findings. Screening of family members revealed that her mother, GO a T2 DM patient with chronic complications – (peripheral neuropathy and dyslipidaemia) and poor medication adherence and her son was also seen to have childhood obesity/acanthosis nigricans. They received motivational counselling to improve adherence to prescribed medication and lifestyle modifications and are monitored twice-monthly up till date, where they have demonstrated satisfactory adherence to lifestyle counselling.

Keywords: Type 2 DM in The Family, Role, Family Physician, Evidence-Based Care, Early Intervention.

Copyright @ 2020: This is an open-access article distributed under the terms of the Creative Commons Attribution license which permits unrestricted use, distribution, and reproduction in any medium for non-commercial use (NonCommercial, or CC-BY-NC) provided the original author and source are credited.



All numbers are ages in years and unless otherwise indicated, abbreviations are names of individual

INDEX CASE

Name: EI	Marital status: Married	Hospital Number: 18/9984
Age: 40 years	Address: Surulere, Lagos	Date of the first visit: 10/05/18
Gender: Female	Religion: Christianity	
Occupation: Lawyer	Tribe: Igbo	

Presenting complaint: EI presented with a complaint of a rash in the armpits and the neck of about four months duration.

History of Presenting Complaints: EI presented to the Family Medicine Clinic of LUTH complaining of rash at the armpits and the neck of about four months duration. The appearance of the rash was of insidious onset. The rash initially appeared as a cluster and progressively increased and then coalesced into a big patch and then was noticed in the left armpit. It became dark as it progressed and was also described as occasionally itching and painful. The itching was precipitated by applying deodorants and sweating, and it was relieved by cooling her armpit while facing a standing fan. There were no associated rashes on any other part of the body. Her husband noticed the rash on her neck. This rash was localized to the back of the neck, and it started as a small rash but later spread to cover the entire nape of the neck. It was also occasionally itchy especially while sweating and in a warm environment but relieved on wiping off the sweat or getting herself to a cool, airy place. She had tried using over the counter creams and increases the number of times she bathed daily as she thought these rashes were as a result of poor hygiene, but this rash persisted. There was no associated bleeding, discharge, nor blistering from this rash. There was no polyuria, polydipsia, excessive thirst, recent onset rash of other nature, and history of poor wound healing. There was no recurrent boils, vaginal itching, or There was no use of hormonal medications or family planning. She usually ate two meals and a lot on pastries and soft drink daily. Her first meal was usually food purchased from cafeterias and the second meal was at home, usually around 8 pm with her husband.

FIFE: EI was concerned about the appearance of these dark rashes as it could be a sign of something sinister. She had no idea as to what could have caused it. This rash had not affected her function and she expected to be appropriately treated.

Review of systems: She had no cough, dizziness, chest pain or palpitations. She had no heat intolerance, tremors of her hands or undue anxiety.

Past Medical History: EI had no recent hospital admissions. She was not a known hypertensive, diabetic, asthmatic, peptic ulcer disease or sickle cell disease patient. She also had no known allergies.

Past Surgery History: EI had never had any surgeries in the past.

Family and Social History: A genogram was drawn to capture EI's family history. (fig 3) There was a history of T2DM in her parents. She was a lawyer married in a monogamous emerging family setting, to an accountant who was working with an oil servicing company. She had an MSc in Business law and her husband had an MSc in Energy economics. They had three children in an emerging family; A 12-year-old boy in boarding school, a ten-year-old boy in primary six and a six-year-old girl in primary two. The family lived in a three-bedroom apartment where the source of water was from a borehole, drinking water was bottled water and from a water dispenser. Their waste disposal was by the Lagos State Waste Management Agency (LAWMA). Their combined monthly income was about ₦890,000.00 (\$2472). Her source of health care financing was through a health maintenance organization engaged on contract by the company her husband worked for.

She did not drink alcohol or smoke cigarettes and also did not engage in exercise. She was always satisfied with how decisions were made in the family, and she felt she could always count on her family for support whenever she had any issues. She sometimes felt she did receive enough support from her husband when she wanted to try new things. She was however; always satisfied with the level of affection displayed from her family but only sometimes satisfied with the amount of time they spent together. The family APGAR, therefore, was 8/10, indicating a highly functional family.

General Examination: She was not in distress. She was not pale, afebrile (36.8⁰C), anicteric, not cyanosed and not dehydrated. She weighed 97kg and was 1.69m tall. The body mass index was 34.kg/m² (Class 1 Obesity). She did not have any significant lymphadenopathy or pedal oedema.

Dermatological examination: A hyperpigmented patch measuring about 8 cm with ill-defined flat edges was seen on the posterior aspect of the neck. The rash also appeared velvety. There was also hyperkeratosis seen on the inspection with no bleeding, no fissures. Two similar rashes were seen in the left axillae, measuring about 3cm by 5cm and 3cm by 7cm. See pictures attached on appendix II. These lesions were not bleeding or discharging any serous fluid.

Cardiovascular System: The pulse rate was 88 beats per minute, regular and of full volume. There were no thickened radial arteries, locomotor brachialis. There was radio radial synchrony with no radio-femoral delay. Her blood pressure reading was 120/80mmHg. The jugular venous pulse was not raised and the precordium was quiet. The apex beat was at the fifth left intercostal space along the mid-clavicular line. Only the first and second heart sounds were heard.

Abdominal Examination: The abdomen was soft, full and moved with respiration with no scarification marks. The waist measured 127cm and the hip circumference was 114cm with the waist-hip ratio calculated to be 1.12 (moderate risk) There was no abdominal tenderness. The liver and spleen were not palpable and the kidneys were not ballotable. Her bowel sounds were normal.

Central Nervous System: She was fully conscious and well oriented in time, place and person. Her neck was supple; Kernig's and Brudzinski's signs were negative. The pupils were equal, round and reactive to light. There were no obvious cranial nerve defects or sensory deficits. The muscle bulk, power and tone were normal in all limbs. Her reflexes were equivocal.

Respiratory System: The respiratory rate was 18 cycles per minute, there was normal chest expansion bilaterally, the tactile fremitus and vocal resonance were reasonable and the breath sounds were vesicular in all lung fields.

Provisional Diagnosis: Acanthosis Nigricans (Pre-Diabetes)

Differentials: Atopic Dermatitis, Candidiasis

Psychosocial problems: Poor lifestyle choices.

Management - Counselling and Lifestyle Education: EI was interviewed to ascertain her knowledge of obesity. She knew obesity had to do with excess weight, and she knew exercise and dietary modifications would help with it. She was surprised that the skin patch was as a result of the obesity. She was assured that once the offending cause of the rash was removed, the patch would resolve.

The concept of obesity, insulin resistance and its sequelae were explained to EI. She was also told she had multiple risk factors which could lead to Type 2 diabetes Mellitus (T2DM): Her lifestyle and history of T2DM in both parents.

She was told that lifestyle modifications were significant in preventing the onset of T2DM and maintaining proper blood glucose control and was counselled on the importance of increasing her physical activity. Following the counselling concerning various physical activity options, She selected early morning

brisk walking to include into her lifestyle. She was told to engage in 30 minutes of brisk walks for at least five days a week. She was also advised to take around 10000 steps daily. It was agreed that she would also get a pedometer to monitor her daily steps.

EI was also counselled on the importance of not eating heavy meals at night. She felt that this would be difficult because of her closing time at work as this was the only meal she shared with her husband. She was then counselled to have light meals like vegetable salads and other reduced caloric meals with her husband. Her readiness to change was assessed, and she was seen to be in the contemplative phase. She was told she would need to run the following investigations: fasting blood glucose, HbA1C, OGTT, fasting lipid profile, electrolyte, urea and creatinine, urinalysis and the cost implications were discussed with her for whom she replied that these would be covered by her company's health maintenance organization. EI was given a three-day appointment.

First follow up visit three days (13/05/2018): EI presented with results of the investigations requested for. She said she had started engaging in daily brisk walks and attained a step count goal of 8,000 to 10,000 steps daily. She had also reduced the number of sugary drinks and pastries she consumed. She now had light meals for dinner, usually consisting of vegetable, fruits or a glass of warm herbal tea with boiled eggs.

The results of the investigations requested are as follows: HbA1c:5.9%, Fasting blood glucose: 6.7mmol/L, Total Cholesterol: 5.1mmol/L, LDL: 3.2mmol/L, HDL: 1.6mmol/L, non-HDL cholesterol: 3.3mmol/L, Triglyceride: 1.64mmol/L. (Sodium-139mmol/l, Potassium-4.0mmol/l, Chloride-101mmol/l, Magnesium-0.7mmol/l and Bicarbonate-28mmol/l). The Serum urea-5.3mmol/l. The results were discussed with her and their implication. She was told she had Prediabetes and this could account for the symptoms she had. The condition had led to the body to be in a state of insulin resistance. The risk factors that predisposed her to attain this were highlighted to her; the family history and her body mass index. She was also told that this could progress to type 2 DM, and it could place her at risk of developing cardiovascular disorders if not addressed early although the 10-year risk of heart disease or stroke using the ASCVD algorithm was calculated to be 0.3%. She was encouraged with the fact that she had commenced lifestyle behavioural change (she was now in the preparatory and action phase). She was asked if she had any questions so far regarding the consultation and she enquired if her mother could be seen by the author (Discussed in the next case) because she knew her mother was on medications for diabetes and had not been compliant with them. She said she asked her mother to run the similar investigations requested of her and sought the author's advice on a review of the

investigations. An appointment was scheduled to see the mother the following week with results of the investigations. She had a doorknob question about the likelihood this was the same thing occurring in her son. She described him as 'fat', and he had a similar patch on his neck. EI was then counselled on the need to screen members of the household for diabetes and other risk factors. A Family counselling session was scheduled for EI, her mother and members of her family.

Second follow up visit two weeks later on the 31/05/2018: EI had no new complaints and presented with her mother, her husband and her children. She had also learnt some new healthy plant-based recipes, and

Name	Relationship	Age	Weight (Kg)	Height(M)	BMI	FBS
CI	Husband	44	90	1.86	26.01	97mg/dl
KI	First son	12	42	1.59	16.56	86mg/dl
DI	Second son	10	56	1.52	24.24	91mg/dl
SI	Daughter	6	25	1.26	15.71	89mg/dl
GO	Mother	72	72	1.66	26.21	101mg/dl

Her son and Mother, DI and GO were selected for further evaluation and asked to open GOP folders to be seen in the clinic. They are discussed as the second and third cases. NI was given a month's appointment and told to repeat an FBG a day before presenting.

Third follow up visit of EI a month later (14/06/2018): EI presented to the clinic. She was happier with the turnout of events. She proudly attested to the fact she had lost about 3kg of body weight and had reduced her abdominal girth by 4 cm. The size of the hyperpigmented patch on her neck had reduced, and the keratotic lines were no longer pronounced. The hyperpigmented patches in her axilla had also reduced in size to about 3cm across in diameter. Her FBG level was 116mg/dl. EI was then given a three-month appointment and asked to repeat the investigations earlier requested to monitor the trend in the laboratory investigations.

Follow up visit three months later on 30/08/2018: EI presented to the hospital looking trimmer than she looked during the first consultation.

Name: GO	Marital status: Married	Hospital ID: 18/10376
Age: 72 years	Address: Yaba Lagos	Date of the first visit: 31/05/18
Gender: Female	Religion: Christianity	
Occupation: Pensioner	Tribe: Igbo	

Reason for encounter: GO had no complaints, she only presented for advice about her blood glucose's control.

History: GO presented to the Family Medicine Clinic LUTH for advice about her blood glucose after being convinced by her daughter to do so. She could not recall her last fasting blood glucose level as she had not

she joined some online support group for ideas on engaging and committing to a healthy lifestyle. This support group helped her avoid triggers that would make her eat unhealthily and advised on coping mechanisms should the cravings to eat such unhealthy meals appear. Using the Transtheoretical model of change, she was still in the "Action phase".

The members present were welcomed and made comfortable. The need for screening for pre-diabetes was discussed with the members of the household and their BMI's and fasting blood glucose levels were checked.

She was very excited about the resolution of symptoms. She said the darkened patch on her neck had significantly reduced and not as prominent as it previously was. The axillary patches had also reduced in size to less than 1 cm, and the pain she initially experienced had reduced. She now weighed 87 kg (BMI 30.46kg/m²). Her waist circumference was now 101 cm and hip measurement was 99cm with a WHR of 1.02. The results of the investigations were as follows: HbA1c:5.1%, Fasting blood glucose: 98mg/dl, Total Cholesterol: 4.9mmol/L, LDL: 3.1mmol/L, HDL: 1.5mmol/L, non-HDL cholesterol: 3.1mmol/L, Triglyceride: 1.6mmol/L. She was then counselled to try and abide by these lifestyle modifications. NI is currently being followed up every two months till date and had demonstrated adequate weight control and on the maintenance phase of her lifestyle regimen.

SECOND CASE: EI's MOTHER 31/05/2018

Poor medication adherence as a reason for poor blood glucose control

checked it in over a year. Her last ophthalmologic examination was done three months prior to this consultation at Ancila Catholic hospital with satisfactory results and she was scheduled for another year. Her diet consisted of the normal Nigerian staple meals however, she is occasionally careful of the portion and type of foods she ate. She had no nocturia, history of passing frothy urine or facial puffiness. She,

however, experienced a burning sensation on both feet, which was worse at night. She had discussed her symptoms with a nurse who was a church member who told her it was "Rheumatism" and part of ageing and advised her to apply a heat balm "aboniki" ® at night. This, however, did not relieve her of the symptoms but she felt it would go away with time.

GO was diagnosed to have T2DM about seven years prior to this visit during a routine health screening program at the staff clinic of the Nigerian Ports Authority liaison office where she worked as an administrative officer. She was then commenced on medications. She was initially compliant with her medication until three years prior when she was burdened with taken care of her late husband, who was diagnosed with prostate cancer. She admitted that since he passed on, she was not compliant with her medications and took the only when she remembered.

FIFE: She was not worried about her blood glucose levels as she felt that she was eating well, exercising occasionally and taking her medications after eating a high carbohydrate meal, so that was sufficient for her blood glucose control. She did not feel limited by this illness and expected that at the end of the consultation, she would be declared healthy.

Past Medical History: She was not a known hypertensive, asthmatic or a sickle cell disease patient. She had no recent hospital admissions. Past Surgical History: She had no surgeries in the past.

Drug history: She had previously used Glucophage® 1gram 12 hourly, and centrum 50+ ® occasionally for three years.

Family and social history: GO was a 72-year-old retired widow in an actualizing family. Her husband died three years earlier from complications of advanced prostate cancer. She had three children who were alive and well. (see fig 3). GO resided with a relative in a 3-bedroom apartment in a gated estate at Yaba Lagos where the source of water was from a borehole, drinking water was pure water. Her waste and sewage disposal were by LAWMA and water cistern respectfully. She did not drink alcohol or smoke cigarettes. She usually took walks in the evenings within the estate with her neighbour. She was always satisfied with how she was involved decision making in her family and she felt she could always count on them for support whenever she had any issues. She was satisfied with the support of her children when she wanted to try new things. She was sometimes satisfied with the level of affection displayed by her family and was always satisfied with the amount of time they spent together. The family APGAR, therefore, was 9/10, indicating a highly functional family. Her monthly allowances from her children, pension and late

husband's estate was estimated to be ₦700000 (\$1912). Her means of health care financing was out of pocket.

General examination: GO was an elderly woman, not pale, well-hydrated, not cyanosed and afebrile to touch with temperature of 36°C. She had no pedal oedema. She weighed 72kg and a height of 1.66m with BMI of 26.12kg/m², which was overweight.

Central nervous system: She was conscious, alert, and oriented in time, place, and person. The neck was supple. Both pupils were equal and reactive. There was no cranial nerve deficit. The muscle power, tone and reflexes were normal in both upper and lower limbs. Her sensation was normal globally.

Cardiovascular System: The pulse rate was 78 beats per minute, was of full volume and was regular. There were no thickened radial arteries, no locomotor brachialis and no radio-femoral delay. The blood pressure was 130/80 mmHg. The jugular venous pulse was not raised and the apex beat was at the fifth left intercostal space along the mid-clavicular line. Only the first and second heart sounds were heard.

Respiratory system: The respiratory rate was 18 cycles per minute. The trachea was central and there was equal chest expansion bilaterally. The tactile resonance and vocal fremitus were normal. Percussion notes were resonant and the breath sounds were vesicular bilaterally with no added sounds.

Abdomen: The abdomen was flat and moved with respiration. It was soft. There was no area of tenderness. The liver and the spleen were not palpable, while the kidneys were not ballotable. The bowel sounds were present and normoactive.

Diabetic Foot examination

There was a normal distribution of weight when standing. Her gait was symmetrical. There was no pallor, hair loss, shiny appearance of the skin and muscle wasting of the legs. There was no pedal erythema and calluses. She had no joint deformity or swelling, no claw toe or abnormal bony prominences. The midfoot arch was intact in both feet. The lower limb pulses were adequately palpable. Her joint proprioception and sensation of vibration were normal. Her sensation of pressure and pinprick were reduced. Semmes-Weinstein monofilament (SWM) testing was negative. An inspection of the pattern of wear on the soles did not reveal asymmetrical wearing. The shoes were seen to be the correct size for her.

Diagnosis: Type 2 DM with peripheral neuropathy
Psychosocial problems: Poor drug adherence

Investigations: Urinalysis done was also normal. The results of the investigations were HbA1c:6.1%, FBG: 128mg/dl which were elevated. Total Cholesterol: 4.8mmol/L, HDL: 1.2mmol/L, non-HDL cholesterol: 3.6mmol/L, Triglyceride: 0.71mmol/L, which were normal. Her LDL level was: 3.3mmol/L (Higher than the ideal targeted level of 2.6mmol/L for her), her 10-year risk of heart disease or stroke using the ASCVD algorithm was calculated to be 24.2%.

Management: GO's perception that she did not need to take the medicines daily was corrected by pointing out the fact that the burning sensation she experienced in both feet was a consequence of poor drug compliance. She was told that T2DM was not curable, but she could live a normal life with optimum blood level control if she used her drugs and adhered to lifestyle modifications. She was also educated on other complications of poor blood glucose control and all questions she had were addressed. She was enlightened on her risk of developing a heart disease in ten year. Based on this, she accepted to recommence her regular use of medications. She was also informed about eating fruits and vegetables, reducing salt, fried foods and cholesterol-containing cooking oils. She was prescribed with pregabalin tablet 75mg daily for five days and one

neurovite tablet daily to help with the neuropathy. She was also prescribed metformin tablets, 1000mg 12hourly and atorvastatin 20mg daily. She was then given a week's appointment.

First follow up visit 1 week later on 7/06/2018: GO presented to the hospital in good spirits, with no complaints and had recommenced her medications and was tolerating them well. The burning sensation had reduced. She was encouraged to continue her medications. She was asked to repeat the investigations in a month and given a month appointment.

Follow up visit 1 month later on 14/06/2018: GO presented with no complaints was monitored bimonthly till date. The burning sensation had significantly reduced. The results of the investigations were HbA1c:5.9%, FBG was 97mgdl and Total Cholesterol: 4.1mmol/L, LDL: 2.8mmol/L, HDL: 1.2mmol/L, non-HDL cholesterol: 3.2mmol/L, Triglyceride: 0.67mmol/L, She is currently being followed up every two months to date and had demonstrated proper medication compliance with satisfactory health status.

THIRD CASE: EI's SON, DI 31/0 5/2018

Name: D I	Marital status: Single	Hospital ID: 18/10187
Age: 10 years	Address: Lagos	Date of first visit: 31/05/2018
Sex: Male	Religion: Christianity	Informant: Mother
Occupation: Pupil	Tribe: Igbo	

Presenting complaint: Darkening rash on the neck

History of Presenting Complaints: DI presented to the Family Medicine Clinic LUTH in the company of his mother on account of darkening on his neck. He could not recall when this rash appeared as well as its progression. The rash was localized to the posterior neck. It was associated with occasional itching and no pain or discharge. There was no history of insect bite on the neck. There was no similar rash in any other part of his body. There were no complaints of sluggishness. No difficulty in breathing, no poor self-esteem, no anxiety or features suggestive of depression. His mother says he snored loudly, but DI had not experienced any shortness of breath and he had no sensation of poorly unrefreshed sleep. He was not involved in any exercise both in school and at home. During the break time in school, he just stayed in the classroom to chat with his friends about a collective video game his cohort of friends was engaged in. After school, he had home coaching lessons and then went on to either play video games or watched cable tv. He knew he was "fat", but this was not associated with bullying from his friends at school as he said, "most of his friends were equally big".

FIFE: He had no concerns about his weight; however, the mother was afraid he might be at risk of

developing type 2 Diabetes. He had no ideas to why he was fat, and this had not limited his function. He also no expectations from this consultation but the mother expected a systematic approach to addressing the dark neck and whatever risks he was exposed to.

Past Medical History: He was not a known hypertensive, asthmatic or sufferer of sickle cell disease. He had no recent hospital admissions. His genotype was AA and blood group was A Rhesus (D) positive.

Past Surgical History: He had not had surgeries in the past.

Drug history: He was not on any medications and had no known drug allergies.

Family and social history: He was always satisfied with how decisions were made in his family and he felt he could always count on them for support whenever he had issues. He was sometimes satisfied with the support from his family whenever he wanted to try new things. He was always satisfied with the level of affection displayed from his family and always satisfied with the amount of time they spent together.

The family APGAR, therefore, was 9/10, indicating a highly functional family. His source of health care financing was from his Pregnancy and delivery history: The mother had antenatal care and delivery at a private hospital. Pregnancy, labour, delivery and puerperium were normal and uneventful. His birth weight was 3.5Kg.

Immunization history: He received all the doses of oral polio, BCG vaccine. Measles, Vitamin A, Yellow Fever and Mumps vaccines were also given as scheduled.

Nutritional history: They had two family mealtimes in a week, on Sundays during breakfast and lunch. His diet mainly consisted of cereals with milk and sugar and processed meats for breakfast, with lots of pastries as mid-day snacks with sugary fruit juice at school. He also had a bottle of soft drink with lunch every day and dinner consisted of noodles, spaghetti or macaroni and also enjoyed taking bananas. He rarely took vegetables.

24-hour dietary recall: Breakfast included six slices of bread and butter, two sausages, a bowl of cereal with milk and sugar and a cup of fruit juice. His midday snacks consisted of a pack of wafers, a pack of biscuits, a bar of chocolate, a pack of sweet juice and a small bowl of spaghetti. His lunch was two slices of boiled yam and stew. He also had a pack of chinchin (A crusty pastry snack) as an after-lunch snack while playing video games. His dinner consisted of two wedges of left-over pizza bought the day before.

Developmental milestones: DI attained his developmental milestones at the appropriate time.

Other siblings: They were alive and well.

General examination: DI was not pale, well-hydrated, not cyanosed and afebrile to touch with temperature of 36.3⁰C. He had no pedal oedema. He weighed 56kg and a height of 1.52M with BMI of 24.24kg/m². This was above the 95th percentile on the CDC Body mass index for age chart and thus classified as obese.

Dermatology examination: A hyperpigmented patch measuring about 6 cm by 3cm with ill-defined edges was seen on the posterior aspect of the neck. The rash appeared velvety. There was also hyperkeratosis seen on the inspection with no bleeding and no fissures.

HEENT: His pupils were equal, round and reactive to light bilaterally. His external auditory meatuses were patent with intact tympanic membranes bilaterally. He had no tonsillar or adenoidal hypertrophy.

Cardiovascular System: The pulse rate was 88 beats per minute, was of full volume and was regular. The blood pressure was 110/70 mmHg. The jugular venous pulse was not raised and the apex beat was at the fourth left intercostal space along the mid-clavicular line. Only the first and second heart sounds were heard.

Central nervous system: He was conscious, alert, and oriented in time, place, and person. The neck was supple. The pupils were equal and reactive bilaterally. There was no cranial nerve deficit. His muscle power, tone and reflexes were normal in both upper and lower limbs.

Respiratory system: His respiratory rate was 18 cycles per minute. The trachea was centrally located. The percussion notes were resonant in all lung fields. There was good air entry in all lung fields with vesicular breath sounds were heard in all lung fields, there were no added sounds.

Abdomen: The abdominal girth was 82 cm, full and moved with respiration. There was no area of tenderness. The liver and the spleen were not palpable, while the kidneys were not ballotable. The bowel sounds were present and normoactive.

Diagnosis: Childhood Obesity with acanthosis nigricans
Differential diagnosis: Seborrheic dermatitis, Candidiasis.

Psychosocial Problems: Poor family lifestyle choices.

Management: Counselling and Education: It was suggested that DI should aim for 1 hour of physical activity daily and to reduce screen time to less than 1 hour per day. His diet should be nutrient-rich foods with a low glycemic index, low-fat dairy, increased intake of fibre-rich foods such as vegetable and fruit, healthier snack food options, to reduce his portion sizes and increase his water intake. They were counselled to take family meals together and he was given a two-month appointment.

Follow up visit: (26th July 2018): DI presented with his mother with no complaints. He had lost 5 kg. He was happy with the way he looked. He had reduced the number of sugary drinks and snacks he consumed daily and had joined started playing volleyball in school. The hyperpigmentation had reduced in intensity and the hyperkeratotic lines were less pronounced. His mother said they had more family meals together and had adhered to the other tenets of counselling given and maintained they would abide by it. His mother was very pleased with their collective progress. DI was commended on his progress and encouraged to maintain this lifestyle. He was also encouraged to partake in some volleyball competition to motivate him.

Summary: EI was recently diagnosed as having Pre-diabetes evidenced by the presence of acanthosis nigricans, obesity and impaired laboratory findings. Screening of family members revealed that her mother, GO a T2 DM patient with chronic complications – (peripheral neuropathy and dyslipidaemia) and poor medication adherence and her son was also seen to have childhood obesity/acanthosis nigricans. They received motivational counselling to improve adherence to prescribed medication and lifestyle modifications and are monitored twice-monthly up till date, where they have demonstrated satisfactory adherence to lifestyle counselling.

DISCUSSION

The family is defined as a social and intimate nurturing group of individuals connected to a patient biologically, legally or by choice, from whom the patient can reasonably expect a measure of support in the form of shelter, finance and emotional nurturing; that share a past, a present and a future with the patient and includes all who contribute in one way or the other to the family culture [1]. The focus on the family is paramount because it plays a significant role in the course of some diseases, for example Type 2 Diabetes Mellitus (T2DM). The genogram of EI discussed in this family case revealed a strong family history of T2DM.

In 2018 and 2019, the theme for diabetes awareness month and World Diabetes Day was “Family and Diabetes [2]”. T2DM is known to have a high familial rate of inheritance[3]. The strongest and most widely accepted risk factors for T2DM are pre diabetes, obesity, physical inactivity, and the predisposing factors to developing childhood obesity include poor dietary habits, sedentary lifestyle, family eating habits and increased media time[5, 11, 12]. EI had pre diabetes and was at risk of developing T2DM. The World Health Organization (WHO) has defined prediabetes as a state of intermediate hyperglycemia using two specific parameters, impaired fasting glucose (IFG) defined as fasting plasma glucose (FPG) of 6.1-6.9 mmol/L (110 to 125 mg/dL)[4]. EI was diagnosed as prediabetic based on her FPG level of 6.7mmol/L. Childhood obesity is defined as a BMI at or above the 95th percentile for *children* and teens of the same age and sex[5,6]. EI's BMI was calculated as 24.24kg/m² and thus categorized as obese. Prediabetes is a precursor to T2DM, her mother GO was managed for. In Nigeria, they are among the commonest disease entities seen in the outpatient departments [7].

The international diabetes federation reports the global and Nigerian prevalence of diabetes as 463 million adults and as 1.7 million respectively[7-9]. SO Martins reported a prevalence of 22.3% for prediabetes among 300 administrative staff of the University College Hospital, Ibadan. Additionally, there is a rising trend in the prevalence of childhood obesity in Nigeria[3,10]. Consequently, due to the increasing

morbidity and mortality associated with Type2DM in children, the American Diabetes Association (ADA) developed guidelines to identify children that are at risk and will require screening. Hence EI's family was screened for T2DM[13].

EI's mother GOES had a complication of diabetes, a peripheral neuropathy [14]. Other common symptoms of diabetes include observed include polydipsia, foot ulcers, and symptoms of target organ damage like retinopathy, peripheral vascular disease [9] and these were not apparent in GO.

The USPSTF recommends that adults without a history of cardiovascular disease (CVD) use a low- to moderate-dose statin for the prevention of CVD events and mortality when all of the following criteria are met: they are aged 40 to 75 years; they have 1 or more CVD risk factors (i.e., dyslipidemia, diabetes, hypertension, or smoking); and they have a calculated 10-year risk of a cardiovascular event of 10% or greater[15,16]. These were calculated in EI and her mother GO as 0.3% and 24.2% respectively and GO was commenced on statins.

While it is widely agreed that lifestyle intervention is a major key to diabetes prevention, accessing readiness to change as was done on EI to undergo such modifications and self-efficacy are also important considerations [5].

EI and her family were counselled on lifestyle modifications as they should be the first line in the management of diabetics, especially for prediabetics in which drug treatment is not indicated and in the case of EI, EI was best positioned to help with his dietary changes because she did the shopping, prepared his meals and packed his school lunch. Her mother GO was counselled to adhere to her medications. The involvement of EI's family in the lifestyle modification summarized with the learning aid WASHED: weight control, alcohol reduction, smoking cessation, health promotion, exercise, and diet as well as medication adherence was crucial in ensuring compliance to the regimens [5, 17].

For family physicians, appropriate evaluation and care should involve a strong focus on the family, especially in chronic illnesses that has a hereditary component. This importance of primary care with respect to the prevention and early detection of heritable disorders will grow significantly [18]. This role was demonstrated in this family case study as applying the levels of prevention in the management of Prediabetes and diabetes, through education, screening for early detection in relatives and spouses, and ensuring adherence to medications to prevent its complications. The lesson learnt is the importance of using the family as a unit in combating T2DM.

REFERENCES

1. VA Inem. Foundational knowledge for the practice of family medicine in West Africa. Lagos. Gbola Awujoola Press. 2016.
2. International diabetes federation. 2019 theme | World Diabetes Day. Available from: <https://worlddiabetesday.org/about/2019-theme>. Accessed on November 15, 2019
3. Ugege O, Ibitoye Pk, Jiya Nm. Childhood Diabetes Mellitus in Sokoto, North-Western Nigeria: A Ten Year Review. *Sahel Med. J* 2013;16:97-101
4. World Health Organization, International Diabetes Federation. Definition and diagnosis of diabetes mellitus and intermediate hyperglycaemia: report of a WHO/IDF consultation. Available from: http://www.who.int/diabetes/publications/diagnosiss_diabetes2006/en/. Accessed on October 12, 2019.
5. Alizadeh Z, Khosravi S, Borna S. Obese and Overweight Children and Adolescents: An Algorithmic Clinical Approach. *Iran J Pediatr.*2013;23(6):621–631.
6. Defining Childhood obesity. Center for disease control and prevention. Available at <https://www.cdc.gov/obesity/childhood/defining.html>. Accessed on October 12,2019.
7. Martins So, Folasire Of, Irabor Ae. Prevalence and Predictors of Prediabetes Among Administrative Staff of aTertiary Health Centre, Southwestern Nigeria. *Ann Ib Postgrad Med.* 2017;15(2):114–123.
8. Zhao Y, Song C, Ma X, Ma X, Wang Q, Ji H, Guo F, Qin G. Synergistic effect of family history of diabetes and dietary habits on the risk of type 2 diabetes in Central China. *International journal of endocrinology.* 2017;2017.
9. International diabetes federation. IDF Africa members. Available from: <https://idf.org/our-network/regions-members/africa/members/20-nigeria.html>. Accessed on November 15, 2019.
10. Ene-Obong H, Ibeanu V, Onuoha N, Ejekwu A. Prevalence of Overweight, Obesity, and Thinness among Urban School-Aged Children and Adolescents in Southern Nigeria. *Food Nutr Bull.* 2012;33(4):242–50.
11. Sahoo K, Sahoo B, Choudhury AK, Sofi NY, Kumar R, Bhadoria AS. Childhood obesity: causes and consequences. *J Family Med Prim Care.*2015;4(2):187–92.
12. Adegoke OA, Emma-Okon BO, Fasanya MK, Salawu AO, Tomi-Olugbodi AA. Behavioural and anthropometric risk factors for diabetes mellitus among newly admitted undergraduates in a Nigerian University. *Nigerian Journal of Clinical Practice.* 2017;20(10):1246-9.
13. Jaja T, Oduwole A O, Fetuga B, and Abdus-Salam I A. Prevalence of Prediabetes In Secondary School Students In Port Harcourt, Nigeria. *Ajdm.*2015;23(1):11-14.
14. Ojo OO, Odeniyi IA, Iwuala SO, Oshinaike OO, Okubadejo NU, Fasanmade OA. Frequency of neuropathic pain in type 2 diabetes mellitus at the Lagos University Teaching Hospital: A questionnaire-based outpatient survey. *J Clin Sci* 2016;13(2):46-50
15. Melvyn Rubenfire.2019 ACC/AHA Guideline on the Primary Prevention of Cardiovascular Disease. American College of Cardiology. Available from: <https://www.acc.org/latest-in-cardiology/ten-points-to-remember/acc-aha-guideline-on-primary-prevention-gl-prevention>. Accessed on November 28 2019
16. ASCVD risk estimator plus. Available at <http://tools.acc.org/ASCVD-Risk-Estimator-Plus//calculate/estimate>. Accessed on November 20 2019
17. Abdulazeez FI, Omole M and Ojulari SL. Medication adherence amongst diabetic patients in a tertiary healthcare institution in central Nigeria *Tropical Journal of Pharmaceutical Research* June. 2014; 13 (6): 997-1001
18. Daelemans S, Vandevoorde J, Vansintjean J, Borgermans L, Devroey D. The Use of Family History in Primary Health Care: A Qualitative Study. *Adv Prev Med.* 2013.