

A Review on Hereditary Palmoplantar Keratoderma

Shivanu Mathon¹, Manu Singh^{2*}

¹Third Year Postgraduate Resident Department of Dermatology Teerthanker Mahaveer University, N.H. 24, Delhi Rd, Moradabad, Uttar Pradesh 244001

²Senior Resident Department of Dermatology, Teerthanker Mahaveer University, N.H. 24, Delhi Rd, Moradabad, Uttar Pradesh 244001

DOI: [10.36347/sjams.2020.v08i03.011](https://doi.org/10.36347/sjams.2020.v08i03.011)

| Received: 26.02.2020 | Accepted: 04.03.2020 | Published: 13.03.2020

*Corresponding author: Manu Singh

Abstract

Review Article

PPK require a precise diagnosis to determine the underlying defects, to know the predisposition for internal malignancy and for proper genetic counselling. The disorder can be diffuse (non- transgradient or transgradient) or focal localised to pressure points. Non-transgradient PPK do not extend beyond the palms on the hands and the sole on the feet while Transgradient PPK extend beyond the palms and soles on their dorsal aspects and to flexor aspect of wrist. Skin around the mouth, eyes, nose, and over the elbows and knees may also be affected. Precise classification of disease helps in choosing the appropriate therapeutic modality.

Keywords: Hereditary, Palmoplantar, Keratoderma.

Copyright © 2020: This is an open-access article distributed under the terms of the Creative Commons Attribution license which permits unrestricted use, distribution, and reproduction in any medium for non-commercial use (NonCommercial, or CC-BY-NC) provided the original author and source are credited.

INTRODUCTION

Hereditary palmoplantar keratodermas (PPK) - 'Keratoderma' means marked thickening of the skin and 'Palmoplantar' refers to the skin on the soles of the feet and palms of the hands [1]. Hereditary PPK are defined as heterogenous group of keratinisation disorders characterized by hyperkeratotic thickening of the palms and soles [2]. Also known as 'keratosis palmaris et plantaris'.

PPK can be either acquired during the lifetime or inherited. Acquired PPKs may arise due to variation in person's health or environment. Inherited PPKs can be autosomal dominant or autosomal recessive [3]. Diagnosis should be made on the basis of history (consanguinity in parents to be ruled out), clinical and histopathological features. Inherited PPKs are caused by genetic mutations that result in abnormalities of structural protein, cornified envelop, connexins and cathepsin C. Mutation in the loricrin gene cause abnormalities in formation of cornified cell envelop [4] and dysfunctional apoptosis of differentiated keratinocytes, causing PPK. Also mutation in keratin gene (K5 and K14 in basal layer, K1 and K9 in suprabasal layers) causes disruption of keratin leading to compensatory thickening of skin of palms and soles.

Hereditary PPK can be classified in two ways

- 1) **Simple Keratoderma-** PPK only [5].
- 2) **Complex Keratoderma-** PPK with lesions on non-volar skin, hair, teeth, nails and sweats glands.

3) **Syndromic keratodermas-** PPK associated with abnormalities of other organs including deafness and cancer.

- 1) **Diffuse PPK** - refers to uniform involvement.
 - a) Non-transgradient PPK does not extend beyond the palms on the hands and the sole on the feet. They may affect the knuckle pads and nails. Eg Vorner's syndrome, Unna Thost Syndrome
 - b) Transgradient PPK extend beyond the palms and soles on their dorsal aspects and to flexor aspect of wrist. Skin around the mouth, eyes, nose, and over the elbows and knees may also be affected.

2) **Punctate PPK-** multiple, small, hyperkeratotic discrete round lesions on entire palmoplantar surface or localized to certain area

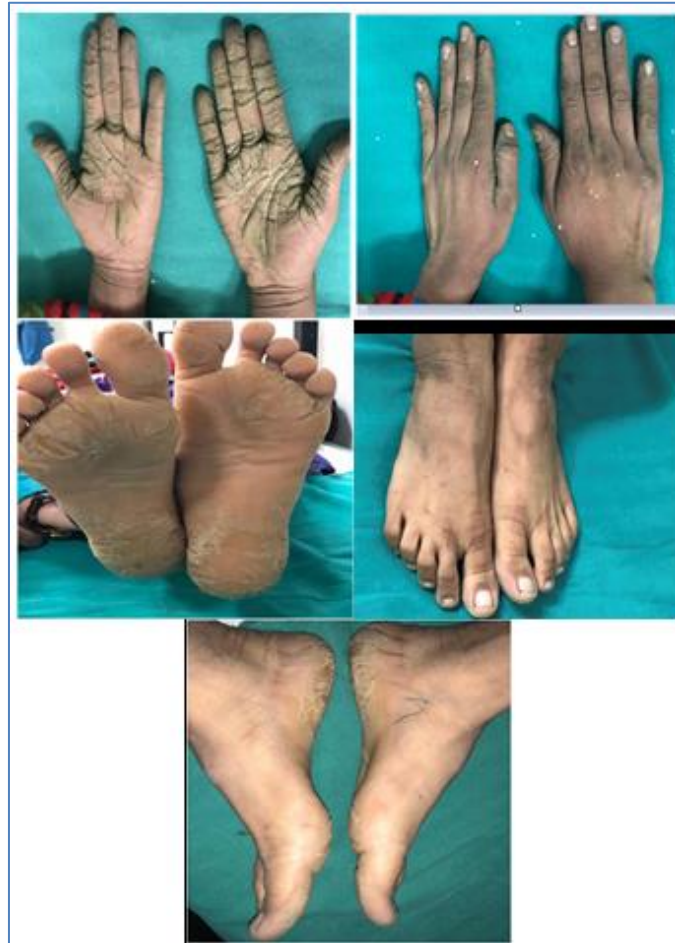3) **Focal PPK** – localized involvement, either nummular or linear, mainly on pressure points.

1) Diffuse PPK Vorner's PPK

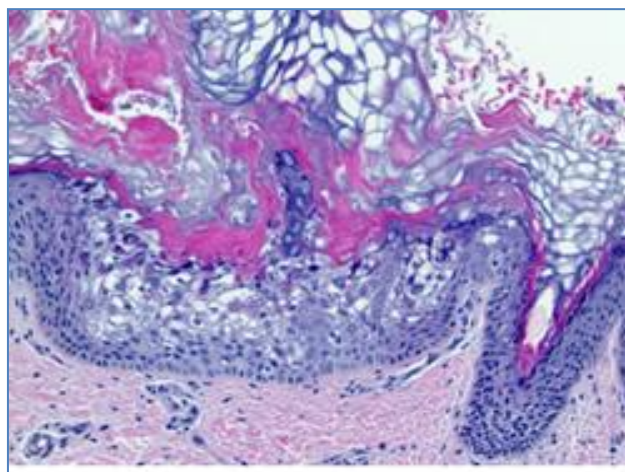
A 14-year-old female student presented with thickening over her palms and soles since the age of the three years. There was no history of blistering in summers or palmoplantar hyperhidrosis. No area other than palms and soles was involved and the patient had normal development. Patient was the only child of her parents. No other family member was affected with similar skin lesions.

Clinically, patient presented with thick diffuse dirty looking fissured hyperkeratotic palms and soles with sharp red margins on the side of feet. Knuckle pads

were absend and no flexion contracture deformity was present. No other hyperkeratotic area noted over the elbows and knees. Nails, teeth and hair were normal.

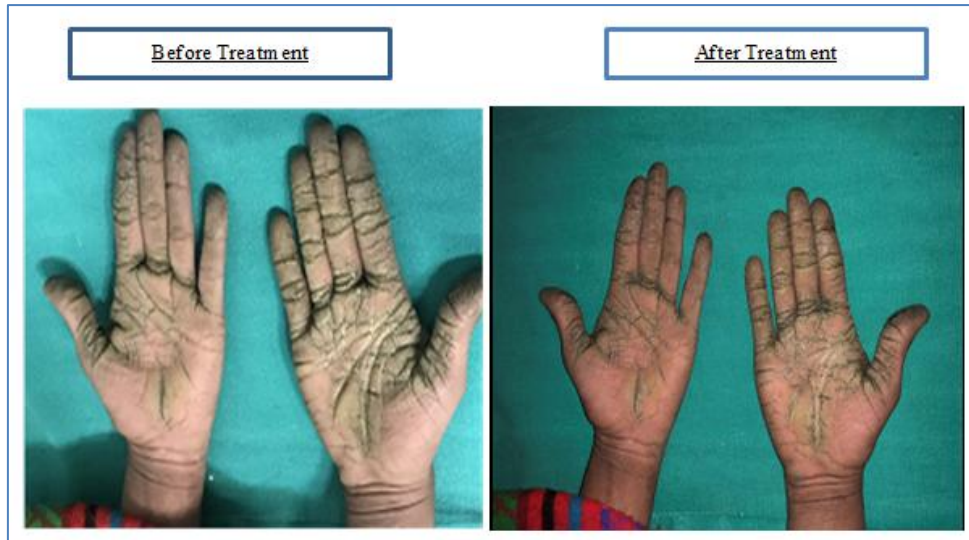

Histologically epidermolytic hyperkeratosis was seen along with hyperkeratosis and acanthosis.



Patient was diagnosed with Vorner's type of PPK and was started on topical keratolytic and oral isotretinoin 20mg/bd. Blood and lipid profile was done and patient was explained about the side effects of

isotretinoin before starting her on medication. Significant improvement i.e reduction of hyperkeratosis and healing of fissures was seen after 3 months.

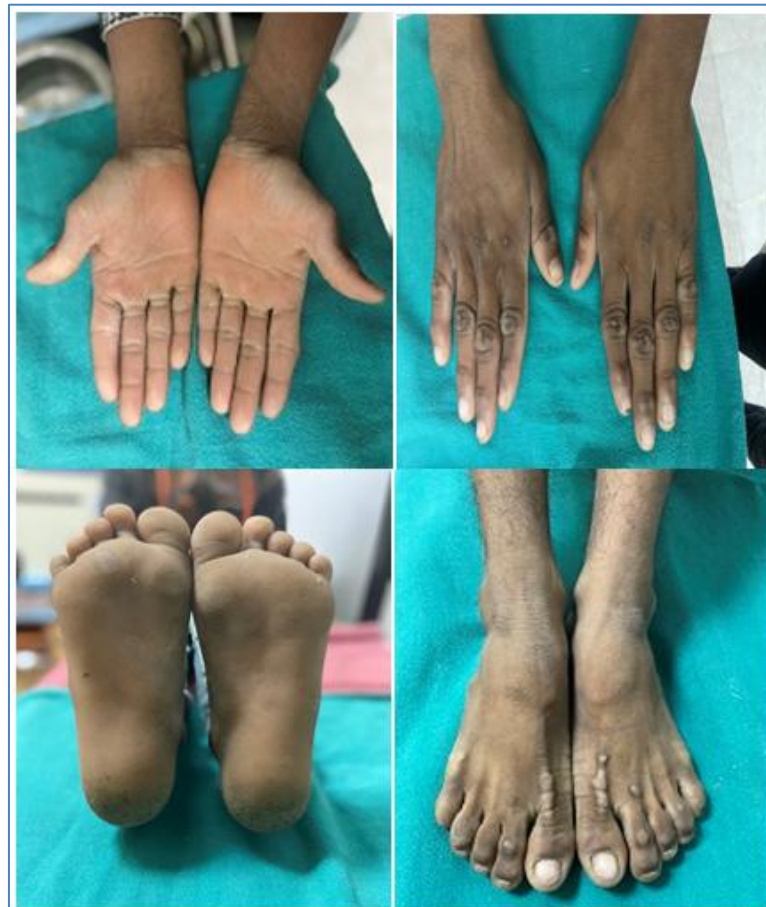

Unna Thost Syndrome

A 9 year old boy presented with waxy scaly lesions over the palms and soles since 10 months. History of consanguineous parents was present. Family history of hyperkeratotic palms was present in the elder brother. Other members of the family were normal. History of hyperhidrosis was present since one year. No history of

dermatophytic infection, pitted keratolysis or maceration was present.

On examination slightly erythematous waxy diffuse hyperkeratosis on palmoplantar area with sharp cut off from wrist and ankle joint was present. Well defined, smooth, flattened to dome shaped thickening present over the joints of hand and feet.



Patient was advised biopsy for which the child had refused. A diagnosis of Unna Thost Syndrome was made based on the history and clinical examination. Patient was started on keratolytics and topical emollients.

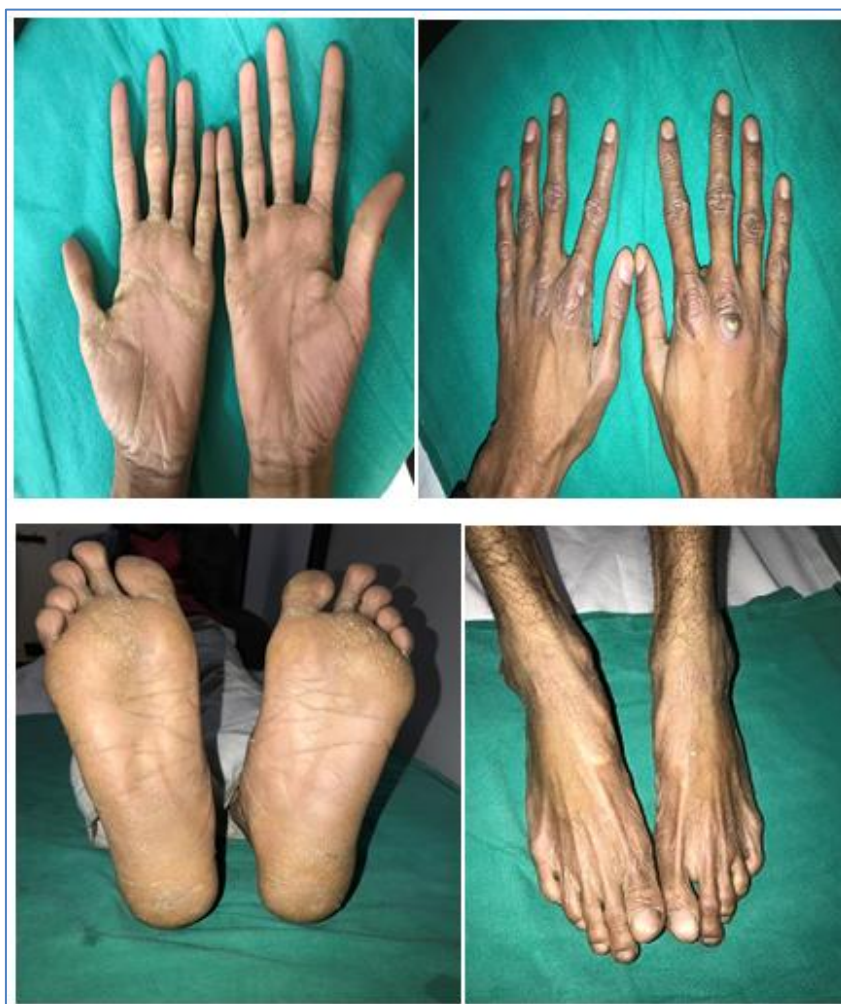II) Punctate PPK

Buschke-Fischer-Brauer PPK

A 22 years old male, worker by occupation was admitted with complaints of chest pain (left side) on deep breathing and breathlessness on exertion, anorexia and weakness since 4 months. After the routine investigations including CXR-PA view and USG thorax were done, patient was found to have 5.5 mm pleural thickening on USG thorax and obliteration of Rt CPA with right pleural thickening, he was referred to our department of dermatology for multiple hyperkeratotic papules and circular depressed craters on the palms and soles. He gave a history that these

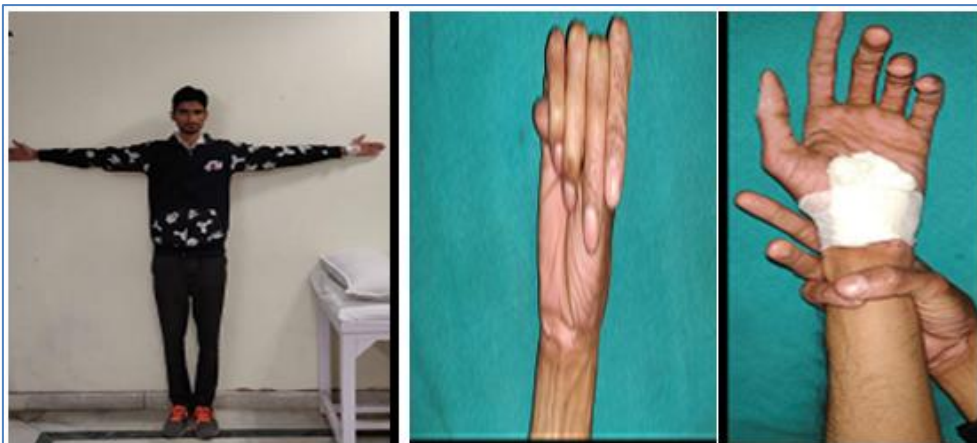
lesions, started 5 years back as small papules that coalesced to give a warty appearance on the left palm. These asymptomatic lesions gradually progressed to involve both the palms and soles. No history of itching and bleeding from the lesions. No history of hyperhidrosis or joint pain. Similar lesions were present on the palms and soles of his father. History of palpitations on and off for which the patient consulted a cardiologist and was diagnosed with rheumatic heart disease in 2015. He had positive ASO titre and had taken injections of penicillin G. History of ATT in 2017 for abdominal Koch's disease.

On cutaneous examination, both his palms and soles had 1-3 mm small discrete yellowish hyperkeratotic papules with a central crateriform depression. The lesions had a linear configuration over the palms. Tenderness was elicited at the pressure points.



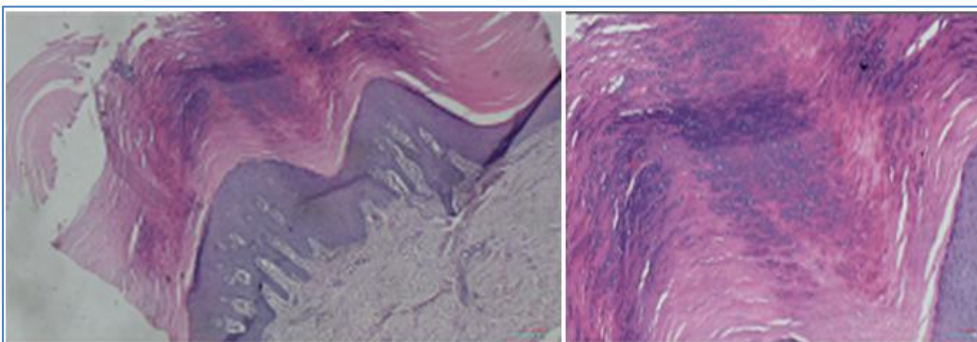
On further examining the patient had disproportionately long arms and legs as compared with the trunk. His arm span was more than his height by about 3 inches with an increased floor to pubis measurement. He had positive wrist sign and steinberg

thumb sign, that is on opposing his hand across the palm, the distal phalanx of his thumb extended beyond the ulnar border indicating laxity of the ligaments. Intraoral examination revealed crowded teeth with arched palate.



4mm punch biopsy was done from the hyperkeratotic lesion of the left palm that revealed orthokeratotic hyperkeratosis, hypergranulosis and

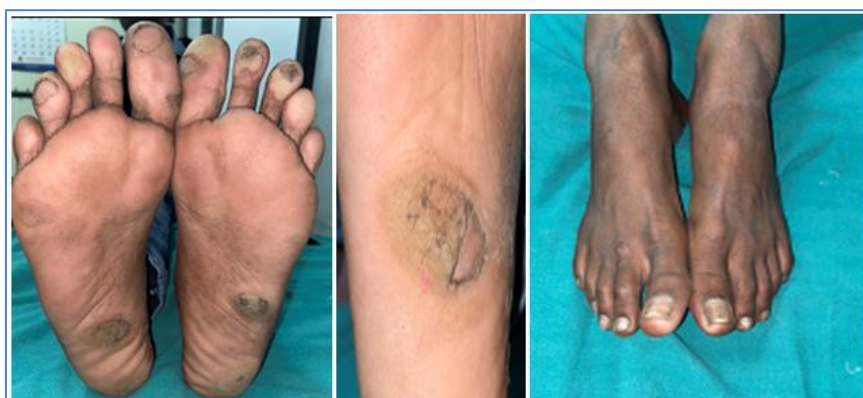acanthosis. Cornoid lamellae were absent and dermis showed infiltration of inflammatory infiltrate.



Based on history, clinical examination and histopathology findings a diagnosis of Buschke-Fischer-Brauer palmoplantar keratoderma with marfanoid habitus was made. Patient was prescribed 5% salicylic acid and 20% urea containing ointment along with emollients. Orally he was given isotretinoin 20mg once a day and was asked for monthly follow up.

III) Focal PPK

A 10 year old boy presented with focal palmoplantar thickening since the age of 3 years. It started as small non pruritic lesions which later progressed to involve the pressure bearing areas with slight pain while walking. Patient was born from a second degree non consanguinous marriage. Similar lesions have started to appear in his 4 year old younger brother.



On examination patient exhibited yellowish focal thickening on pressure bearing areas. No other sites were involved, Hair, nail and oral cavity was normal. On histopathological examination

hyperkeratosis, acanthosis and papillomatosis were seen. Hence patient was diagnosed as Focal PPK and was started on keratolytics and emollients.

DISCUSSION

PPKs comprise a heterogenous group of disorders characterised by epidermal thickening of palms and soles. Apart from being classified as above stated, they can also be divided on the basis of presence or absence of extracutaneous findings [6]. Complex keratoderma may involve abnormalities of internal organs and adenexal structures. Acquired keratoderma comprising keratoderma associated with internal malignancy, due to inflammatory dermatosis, infections, drug related PPK or associated with systemic disease and internal malignancy needs to be ruled out [7].

Treatment usually is difficult. The most important aspect of treatment is to stop underlying condition or possible trigger if any [8]. The most important treatment modalities used provide only a short term effect and have varied side effects. Topical treatment modalities include keratolytics like salicylic acid 5-10%, lactic acid 10% or urea 10-40%. Others may include tretinoin or calcipotriol with no much effect. Oral modalities include retinoids like Acitretin or isotretinoin [9]. These should be started from low doses and slowly increased to prevent disease flare. Phototherapy i.e PUVA can be done if PPK is present secondary to psoriasis or eczematous condition. Associated hyperhidrosis can be treated with aluminium chloride, iontophoresis or botulinum toxin. Associated dermatophyte infection should be treated. Comfortable footwear should be selected. For severe cases, surgery including the excision of Hyperkeratotic area should be considered. Various syndromes in PPK like Huriez syndroeme, Papillon Lefevre syndrome have higher chances of skin cancer so these should be closely monitored.

REFERENCES

1. Judge MR, Mclean WHI, Munro CS, Burns T, Breathnach S, Cox N. Disorders of Keratinization. In Rook's Textbook of Dermatology. 8th ed. United Kingdom: Wiley-Blackwell Publisher (P) Ltd; 2010. 19.93-19.119
2. Tanvi Dev, Vikram K. Mahajan. Hereditary Palmoplantar Keratoderma: A Practical Approach to the Diagnosis. Indian Dermatol Online J. 2019 Jul-Aug; 10(4): 365-379
3. Sakiyama T, Kubo A. Hereditary palmoplantar keratoderma "clinical and genetic differential diagnosis": J Dermatol. 2016 Mar;43(3):264-74.
4. Braun-Falco M . Hereditary palmoplantar keratodermas. J Dtsch Dermatol Ges. 2009 Nov;7(11):971-84.
5. Guerra L, Castori M. Hereditary palmoplantar keratodermas. Part I. Non-syndromic palmoplantar keratodermas: classification, clinical and genetic features: J Eur Acad Dermatol Venereol. 2018 May; 32(5):704-719.
6. Kelsell DP, Stevens HP. The palmoplantar keratodermas: much more than palms and soles: Mol Med Today. 1999 Mar;5(3):107-13.
7. Murthy SC, Raghu TY, Suresh T. A study of palmoplantar keratodermas in South India: Int J Dermatol. 2008 Jul;47(7):762-4.
8. Puri N. A study on palmoplantar keratoderma in childhood in a district hospital. Indian J Paediatr Dermatol. 2017;18:183-6
9. Guerra L, Castori M. Hereditary palmoplantar keratodermas. Part II: syndromic palmoplantar keratodermas - Diagnostic algorithm and principles of therapy: J Eur Acad Dermatol Venereol. 2018 Jun; 32(6):899-925.