

Hypospadias and Urethral Diverticulum in a Female Pseudohermaphrodite Calf

A.A.A. Abd-El-Hady*, Mouchira M. Mohi El-Din

Surgery Department and Pathology Department, Faculty of Veterinary Medicine, South Valley University, Qena

*Corresponding Author

Name: A.A.A. Abd-El-Hady

Email: abdelnaserazab@yahoo.com

Abstract: A five-month old crossbred calf weighing about 120 kg referred to The Surgery Department, Faculty of Veterinary Medicine, South Valley University, Egypt, with a complaint of dysuria, stranguria accompanying perineal swelling. A fluctuant swelling was palpated in the midperineal region. Since iatrogenic interference a multiple skin sores were seen on the diverticulum along with subcutaneous leaking fluctuating pocket on aspiration revealed pus. Urine outflow from a tiny orifice presented at the proposed natural site of the vulva. Dissection of skin diverticulum revealed hypoplastic penis with adhesion of the preputial sheath along with penile hypospadias. Permanent perineal urethrostomy and diverticulectomy was performed in the region of the defect. Finally, the urethral layer was sutured with the skin using 2-0 Mersilk sutures in a simple interrupted pattern. The urethrostomy site appeared to be healed without any complications and the animal was reported to be urinating properly. Histopathological examination revealed thick layers of the diverticulum, declared female pseudohermaphroditism, in which complete structure of penis with inflamed urethral opening was noticed adhered to the structure of female urethra.

Keywords: Hypospadias; Urethral diverticulum; Pseudohermaphrodite; Surgical; Histopathology

INTRODUCTION

Hermaphroditism occurs most commonly in goats [1] and rare in cattle [2, 3]. A pseudohermaphrodite is distinctly of one gender but has the somatic characteristics of both genders [4]. It could drive from discordance from gonadal and phenotypic [5]. In cattle, Freemartin syndrome and female pseudohermaphrodite heifer with gonadal mosaicism are the most frequent intersex condition reported [6, 7]. Hypospadias and urethral diverticulum are rarely occurs in ruminants [8]. Sporadic cases of hypospadias and urethral diverticulum are recorded in kids and lambs [9-11]. In hypospadias, penile urethra terminates ventrally and caudal to its normal opening at any level from the perineum to the tip of the penis, generally occur as a result of imperfect closure or complete lack of fusion of the urethral grooves during phallus elongation [12]. It is classified on the basis of anatomic localization such as glandular, penile, scrotal, perineal, or [13, 14]. Surgical correction is not recommended as mostly the anomaly coexists with other malformations [15]. Urethral dilatation occurs sporadically and could be recognized easily, but sometimes it is neither so easily repaired, nor the outcome of its surgical correction has been fully discussed [16-18]. The urethral diverticulum may be single or multiple. When not associated with other malformations, surgical correction may be attempted under local anaesthesia [19, 20]. The aim of this study was to describe the clinical and pathological examinations for a rare case of female

pseudohermaphrodite, hypospadias and urethral diverticulum for attempting surgical treatment.

MATERIALS AND METHODS

A five-month old crossbred calf weighing about 120 kg referred to The Surgery Department, Faculty of Veterinary Medicine, South Valley University, Egypt with a complaint of dysuria, stranguria accompanying perineal swelling. Anamnesis and follow-up information were obtained from animal owner. Surgical intervention was done. The animal was sedated using Xyla-ject® (Xylazine HCL 23.3mg Eq.to 20mg xylazine base. ADWIA Co. S.A.E. 10th of Ramadan City. Egypt) in a dose 0.1mg/kg. b.w. i.m., this was combined with epidural injection of Debocaine® (Lidocaine HCL 2 %. Sigma. Tec. Pharmaceutical indust. Co. packed by Al-Debeiky pharmaceutical industries Co. for AL-Debeiky pharma. A.R.E) in a dose of 8ml to anaesthetize the perineum. The animal was kept on lateral recumbancy then the site was clipped, shaved, aseptically prepared using Betadine® (povidone iodine solution. The Nile Co. For Pharmaceutical and Chemical Industries – Cairo – A.R.E), and finally draped for surgery. An elliptical skin incision was given on the ventral border of the diverticulum. After incising through the subcutaneous tissue, a keen dissection was extended to free the adhesion of hypoplastic penis to the preputial sheath. Then, the urethral diverticulum was exposed and resected close to its caudal end. Simple interrupted

sutures using 2-0 Mersilk were applied to close the urethral and skin wounds. Post-operative care was undertaken through daily administration of an antibiotic, named Pent&Strept® (Norbrook Laboratories Limited, Newry, BT35 6jp. Distributed by: Norbrook Laboratories(GB)Limited. The green, Great Corby, Carlisle, CA4 8LR) in a dose of 1/25 kg.b.wt. deep intramuscularly, for 7 days; the suture line was cleaned daily with an antiseptic Betadine® (Povidone-Iodine 10% Antiseptic Solution – EL-Nile Co. For Pharmaceutical and Chemical Industries – Cairo – A.R.E. R.C.C. 115668). Sutures were removed on the 10th post-operative day. The removed diverticulum was sent to the Pathology Department laboratory, Faculty of Veterinary Medicine, South Valley University, Egypt. Specimens from the hypoplastic penis and thick layers of the diverticulum were collected and fixed in buffered formalin, then immersed in paraffin and 5µ thick paraffin-sections were prepared and stained by Harris's hematoxylin and eosin for histopathological examination.

RESULTS

The animal showed mild fever (39.7c°), tachycardia (120/minute) and normal respiration. The calf was classified as a typical female pseudohermaphrodite. It appeared like a female because normal teats were present in the inguinal region and just a mid-line perineal diverticulum (15cm×25cm) was palpated along the entire length of perineum. Caudally, a rudimentary urethral orifice was detected below the anal opening (Fig.1). The cranial end of the diverticulum showed the preputial opening covered with hair tuft. Narrowing of the urethral orifice as well as the presence of fibrous adhesions between the penis and preputial sheath led to failure of attempts to remove urine from the diverticulum. The skin was inflamed and thickened dorsally which could be attributed to subcutaneous leaking pocket filled with pus. Urine could be aspirated from the ventral aspect of the diverticulum (Fig. 1&2). Surgical dissection of the

diverticulum skin declared a sigmoid flexure, an S-shaped bend in the penis protrude from the outpouching of a fluid-filled structure along the entire length of perineum (Fig. 3-5). Permanent perineal urethrostomy and diverticulectomy were performed and the urethral layer was sutured with the skin and the urination acted normally after the end of operation (Fig. 6&7). The urethrostomy site appeared to be healed without any complications, and the animals were reported to be urinating properly.

Histopathologically, thick layers of the diverticulum declared female pseudohermaphroditism, in which complete structure of penis with glans penis adhered to structure of female urethra, besides suppurative inflammation in urethral smooth muscle and congestion in the blood vessels (Fig. 8 & 9). Penis aspect showed complete structure of penis formed from spongy urethra characterized by stratified cuboidal epithelium centrally the corpora spongiosum and corpora cavernosum containing extensive fibromuscular trabeculae surrounded the vascular channels, besides retractor muscles, tunica albuginea and skin (Fig. 10). The spongy urethra was suffered from hyperplasia in the lining epithelium formed finger like projection among the trabeculae with severe suppuration mainly neutrophil and eosinophil cells scattered in the epithelium cells and trabeculae (Fig. 11). Other aspects showed urethral layer manifested by smooth muscle with urethral space and bundles of skeletal muscle adhesion to thrombotic blood sinusoids (Fig. 12 & 13). Suppurative inflammation surrounded the edematous blood vessels characterized by dead neutrophils replaced necrotic smooth muscles (Fig. 14). Cells proliferation was detected around the urethral spaces and blood vessels, besides edema among the smooth muscles (Fig. 15). Other section showed numerous abscessation characterized by accumulation of live neutrophils replaced the necrotic muscles adhesion to inflamed blood vessels (Fig. 16).

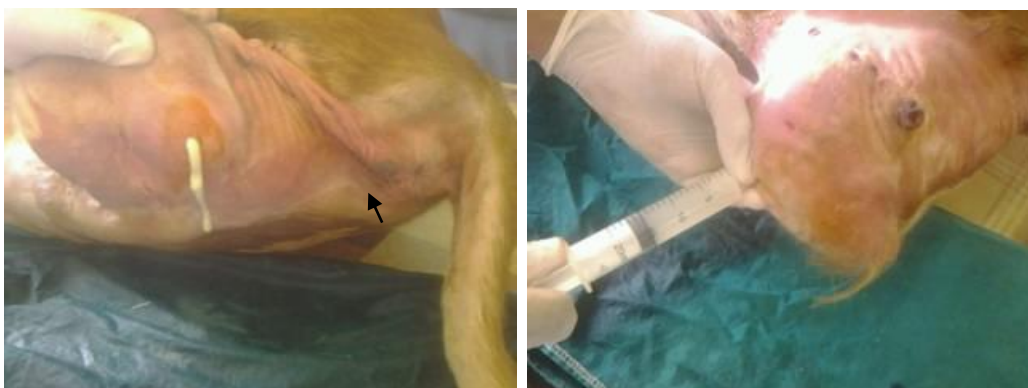

Fig. 1 & 2: Showed a mid-line perineal diverticulum (15cm×25cm) along the entire length of perineum, the dorsal aspect of the diverticulum have pocket with puncturing revealed pus (1), while urine aspirated from the ventral aspect (2).

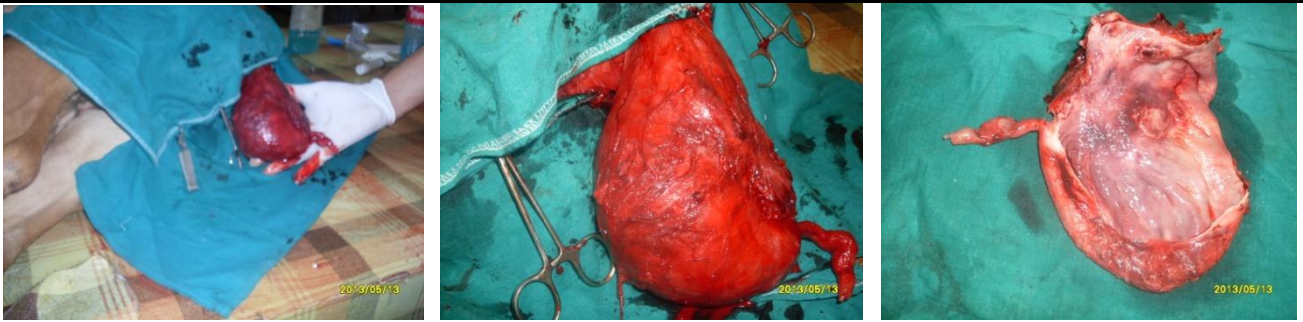


Fig. 3-5: Urethral diverticulum after complete dissection of skin, a sigmoid flexure, an S-shaped bend in the penis protrudes from the outpouching of a fluid-filled structure along the entire length of perineum (3&4). The opened diverticulum after its excision (5)

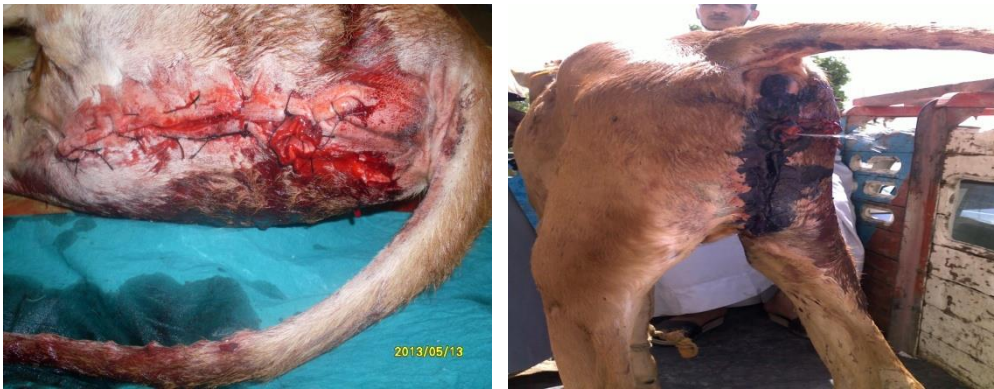

Fig. 6 & 7: Permanent perineal urethrostomy and diverticulectomy: The skin and urethral layer was sutured (6) and the urination acted properly post operation (7).

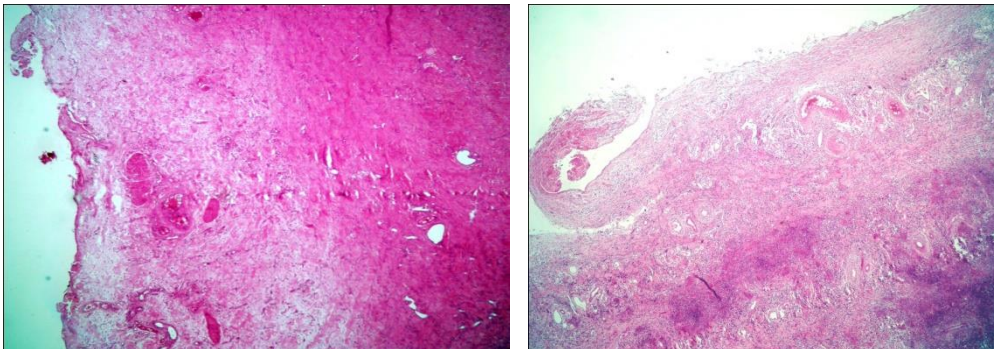


Fig. 8&9: Thick layer of the diverticulum declared female pseudohermaphroditism, in which complete structure of penis with glans penis adhered to structure of female urethra, besides suppurative inflammation in urethral smooth muscle and congestion in the blood vessels. HE. Bar= μ

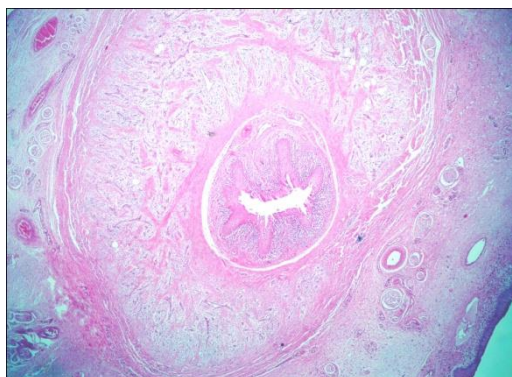


Fig. 10: Complete structure of penis formed from spongy urethra characterized by stratified cuboidal epithelium centrally the corpora spongiosum and corpora cavernosum containing extensive fibro-muscular trabeculae surrounded the vascular channels, besides retractor muscles, tunica albuginea and skin. HE. Bar= μ

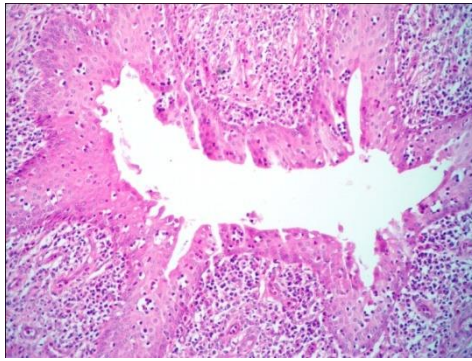


Fig. 11: Penile urethra showed hyperplasia in the lining epithelium formed finger-like projection among the trabeculae with severe suppuration mainly neutrophil and eosinophil cells scattered in the epithelium cells and trabeculae. HE. Bar= μ

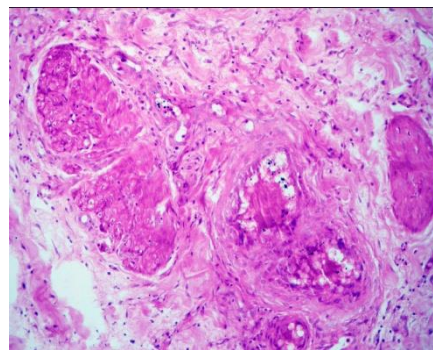
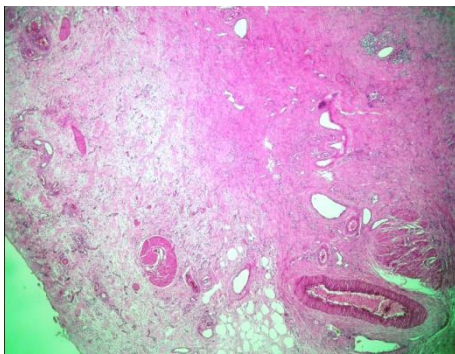


Fig. 12 &13: Urethral layer manifested by smooth muscle with urethral space (12) and bundles of skeletal muscle adhesion to thrombotic blood sinusoids (13). HE. Bar= μ

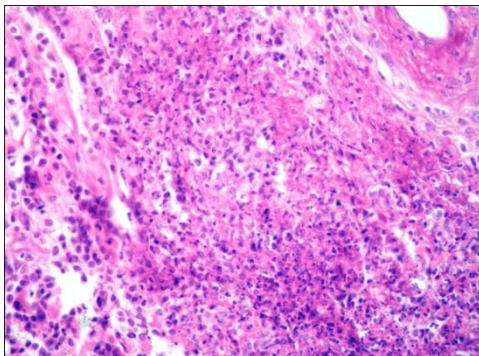


Fig. 14: Suppurative inflammation surrounded the edematous blood vessels characterized by dead neutrophils replaced necrotic smooth muscles. HE. Bar= μ

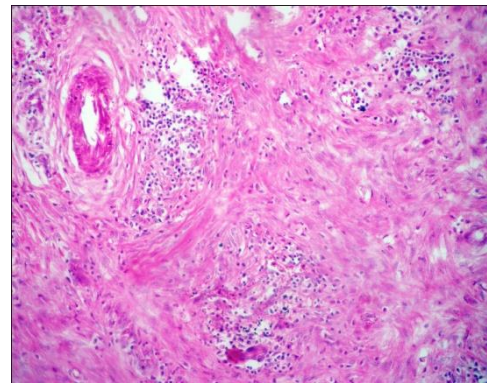


Fig. 16: Numerous abscessation characterized by accumulation of live neutrophils replaced the necrotic muscles adhesion to inflamed blood vessels. HE. Bar= μ

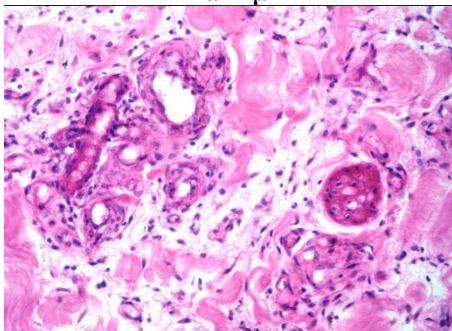


Fig. 15: Cell proliferation around the urethral spaces and blood vessels, besides edema among the smooth muscles. HE. Bar= μ

DISCUSSION

A hermaphrodite is an organism that has reproductive organs normally associated with both male and female sexes but pseudohermaphroditism having gonads of only one sex [1]. Male pseudohermaphrodites are phenotypically resembles females but have testes while female pseudohermaphrodites resemble males but have ovaries [1, 21]. Hypospadias is a birth defect of the urethra in the male that involves an abnormally placed urinary meatus. The more severe cases of the proximal hypospadias often show a narrowing of the urethra with signs of urinary outflow obstruction and are commonly associated with cloacal anomalies and

female pseudohermaphrodites [22]. Urethral diverticulum in females is a localized outpouching of the urethra into the anterior vaginal wall. In our reported case, hypospadias and urethral diverticulum coexists in female calf. Histopathological evaluations of the anomalous confirm the existence of female hermaphrodite suspected during clinical examination.

CONCLUSION

Although, the surgical intervention is not recommended in hypospadias coexisted with other malformations. However, in this report, it could be concluded that surgical intervention was successful for treatment of urethral diverticulum associated with hypospadias in female pseudohermaphrodite calf.

REFERENCES

1. Roberts SJ; Veterinary obstetrics and genital disease (Theriogenology), 2nd edition, CBS Publisher and Distributors, New Delhi, 1971: 64 – 67.
2. Khan LA, Utage SG, Sontakke HS, Shaikh AR, Khan KM, Qazi MM, Siddiqui Z; Male Pseudohermaphroditism in a non-descript calf. Veterinary World, 2008; 1(5):148.
3. Arsdall DV; Pseudohermaphrodite <http://calfology.com/library/wiki/Pseudohermaphrodite>
4. Stamper MA, Norton A, Spondnick G, Marti J, Loomis M; Hypospadias in a polar bear (*Ursus maritimus*). J Zoo Wildl Med., 1999; 30(1): 141–144.
5. Bigliardi E, Parma P, Peressotti P, Lorenzi LD, Wohlsein P, Passeri B *et al.*; Clinical, genetic and pathological features in of male pseudohermaphroditism in dog. Reproductive Biology and Endo., 2011; 9: 12.
6. Padula AM; The freemartin syndrome: an update. Anim Reprod Sci., 2005; 87(1/2): 93–109.
7. Takagi M, Yamagishi N, Oboshi K, Kageyama S, Hirayama H, Minamihashi A *et al.*; A female pseudohermaphrodite Holstein heifer with gonadal mosaicism. Theriogenology, 2005; 63(1): 60–71.
8. Alam MR, Shin SH, Lee HB, Choi IH, Kim NS; Hypospadias in three calves: a case report. Vet Med Czech., 2005; 11: 506–509.
9. Dennis SM, Leopold HW; Ovine congenital defects. Vet Bull., 1979; 49: 233–239.
10. Sharma SN, Singh J; The Urinary System. In Tyagi RPS, Singh J editors; Ruminant Surgery, CBS Publishers, Delhi, India. 1995; 272.
11. Al-Ani FK, Khamas WA, Al-Qudah KM, Al-Rawashdeh O; Occurrence of congenital anomalies in Shami breed goats: 211 cases investigated in 19 herds. Small Rumin Res., 1998; 28(3): 225–232.
12. Radostits OM, Gay CC, Hinchcliff KW, Constable PD; Veterinary Medicine. 10th edition, London, Saunders Co., 2007: 573.
13. Ader PL, Hobson HP; A review of the veterinary literature and a report of three cases in the dog. J Am Anim Hosp Assoc., 1978; 14: 721–727.
14. Kahn CM, Line S, Aiello SE; Urinary System. The Merck Veterinary Manual. 9th edition, Merck and Co.Inc., Whitehouse Station, NJ., USA, 2005; 1249–1287.
15. Singh AP, Al-Badrany MS, Eshous SM, Abid TA; Hypospadias and urethral diverticulum in goats, Indian J. Vet. Surg. 1989; 10(1): 51.
16. Johnson EH, Nyack B, Johnson R; Urethral dilatation in a steer: a case report. Vet Med Small Anim Clinic., 1980; 75(9):1429-1431.
17. Karras S; Modransky P, Welker B; Surgical correction of urethral dilatation in an intersex goat. J Am Vet Med Assoc., 1992; 201(10): 1584-1586.
18. Misk NA; Atlas of Veterinary Surgery. Assiut Univ. Press, 2008.
19. Ali MM, Hussein KED, Galal AF; Diagnosis and treatment of congenital urethral dilatation in cattle calves. XX International Congress of Mediterranean Federation of Health and Production of Ruminants, Assiut University, Egypt, 19-22 February, 2013.
20. Bokhari SG; Hypospadias and urethral diverticulum in two goat kids: A case report. The Journal of Animal & Plant Sciences, 2013; 23(2): 675-677.
21. Jan L, Sadler T; Langman's medical embryology. Hagerstown, MD: Lippincott Williams & Wilkins. 2006.
22. Knight HML, Phillips NJ, Mouriquand PDE; Female hypospadias, a case report. J Pediatr Surg., 1995; 30(12): 1738–1740.