

Clinical observations on some surgical udder and teat affections in cattle and buffaloes

A.A.A. Abd-El-Hady

Surgery, Anaesthesiology and Radiology Department; Faculty of Veterinary Medicine; South Valley University; Qena; Egypt.

***Corresponding Authors**

Name: A.A.A. Abd-El-Hady

Email: abdelnaserazab@yahoo.com

Abstract: The study was carried out on a total number of 360 dairy animal, 275 dairy cow and 85 buffalo during the period from Jan. 2010 to March 2015. All the cases were private cases seen in the villages of Damietta and in veterinary convoys held in villages of Upper Egypt. The udder affections included: Deep wounds (5(1.4%) , 1(0.28%)); Hematoma (20(5.6%) , 7(1.9%)); Abscesses (21(5.83%) , 0); Gangrenous mastitis (36(10%) , 0) and ruptured suspensory ligaments (10(2.8%) , 0), while the teat lesions included: Anomalies (50(13.9%) , 5(1.4%)); Wounds (18(5%) , 0); Stenosis (50(13.9%) , 15); Obstructions (70 , 15); Ulcerative thelitis (0 , 33(9.5%)) and teat cistern dilatation (3 , 9) in cattle and buffaloes, respectively. The appropriate medicinal and surgical management was undertaken for each case with uneventful results. It was concluded that, udder and teat affections are relatively variable between cattle and buffaloes with less frequent occurrence in buffaloes, perhaps due to specific anatomical and physiological criteria of the buffalo udder along with the special environmental peculiarities under Egyptian relations.

Keywords: cattle and buffaloes, Deep wounds, Hematoma, Abscesses, Damietta, Egypt

INTRODUCTION

Udder and teat health are increasingly important for dairy producers and any disease condition involving udder or teat ultimately affects the productivity and the farmer's economy. The udder and teats are vulnerable to external trauma or injury because of their anatomical location, increase in size of udder and teats during lactation, faulty methods of milking, repeated trauma to the teat mucosa, injury by teeth of calves, accidentally stepped on teat, paralysis resulting from metabolic disturbances at parturition [1]. In addition, anomalies of the udder and teats may preclude or interfere with milk outflow and may predispose to mastitis [2]. Congenital aberrations in the mammary gland of the cows include many structural defects; however, the only one of significance is supernumerary teats. Supernumerary teats may be located on the udder behind the posterior teats, between the front and hind teats, or attached to either the front or hind teats [3]. In India, some reports on the congenital abnormalities of the udder and teats in buffaloes were published [4]. Though the diseases of udder and teats are well documented in cattle, very little information is available in buffaloes. Lacerations and wounds of the udder and teats may be caused by barbed wires fencing around the farms. Laying down on sharp objects or inflicted by long untrimmed claws of the cow itself or by another cow trotting a recumbent one. Non penetrating wounds may be handled as any other lacerations, keeping in mind that large amount of scar tissue or flaps of skin may interfere with milking or have undesirable cosmetic effect. Penetrating wounds

of the udder with exposed parenchyma should be closed with catgut and antibiotic should be administered by intramammary infusion. Teat lacerations are classified according to the duration from time of trauma, the localization and conformation of the laceration and the thickness of the lesion (full or partial thickness) [5]. Wounds in the area of the teat sphincter may lead to stenosis. If there are flaps of skin that protrude, they should be sutured or removed. Portions of non viable skin should be trimmed back to conform to normal contour of the teat. Sutured wounds of the teat may be protected by an adhesive elastic bandage.

Udder abscesses are clinically manifested either in a form of chronic suppurative mastitis caused by the common environmental pathogens [6,7] or in a circumscribed localized swelling anywhere of the udder and most commonly seated on cranialateral and posterior aspects of the udder quarters [2, 8]. Diagnosis depends on exploratory puncture which revealed the presence of pus and necrotic tissues. Treatment by a stab incision was performed on the lateral aspect of affected quarters and complete evacuation of the contents was performed in chronic suppurative form [9], whereas the localized form was treated similar to those elsewhere in the body. Hematomas of the udder are considered as inflicted by the cow itself or by external trauma from butting or kicking by other cows but injuries from these sources seldom are confirmed [10]. [11] reported that, hemolactia in buffaloes usually occurs immediately after calving as a result of rupture

of many small congested blood vessels or seepage of blood into teat canal by diapedesis. Hematomas are diagnosed as subcutaneous, mixed and parenchymatous. [12] who reported a case of acute gangrenous mastitis due to clostridium perfringens type A and Escherichia coli in a five-year-old Holstein cow. The disease may be developed within 24 hours after calving with pronounced general systemic disturbance along with subcutaneous emphysema of the affected quarter(s), cold and feel insensitive along with deep violet changed into dark brown coloration. On stripping, gas bubbles were present and evokes in a brownish discolored secretion [2, 12]. Ruptured suspensory ligaments are of two types, 1) rupture of the medial ligaments: is the most common type of rupture and results in a lateral displacement of the right and left halves of the udder. When viewed from the rear this is recognized by the teats splaying outwards. The teats are no longer perpendicular to the ground or parallel with each other. Sudden change in the udder conformation may notice, and there is a loss of the dividing curvature between the two halves of the udder. 2) rupture of the lateral ligaments: is the most easily recognized and results in a dramatic lowering of the udder below the hocks [13]. Concerning the teat anomalies, [14] stated that, hyperthelia occur with considerable frequency in cows. [15] found that, the incidence of supernumerary teats in Egyptian buffaloes was 1.6% while [16] met with 2.7% of this anomaly. In India, [17] reported 1.3 – 8.6 % of buffaloes were with hyperthelia. In Egyptian buffaloes, either complete or incomplete fusion between the teats in a percentage of 1.8% was recorded by [15] and [18]. In Indian buffaloes, [19] recorded a higher incidence of teat anomalies in buffaloes (9.2%). Among the teat lesions, the highest incidence observed was intraluminal obstructions (28.80%) followed by polythelia (26.66%), oligithelia and fused teats (2.22%) [20]. The most important congenital affections met with in teat of dairy cows included supernumerary teats (36.80 %), too closed teats (26.50 %), very short teats (23 %), congenital teat obstruction (4.90 %) and incompetent teat sphincter (1.50 %)[21].

Ulcerative thelitis is a disease affecting primarily the high-yielding primiparous graded Murrah milch buffaloes and causing serious economic losses to the farmers in coastal districts of Andhra Pradesh [22]. The disease is characterized by acute inflammation of one or more teats with subsequent thickening, narrowing or closure of teat canal leading to incomplete drainage of milk. The quality of milk appears to be normal unlike in clinical mastitis. This is followed by ulceration, focal necrosis, and either partial or complete sloughing off the affected teat. Healing may be delayed due to the trauma of milking and secondary bacterial infections. Similar signs were reported by many workers in ulcerative mammillitis of cows [23, 24, 25, and 26] and in buffaloes [27, 28]. As primiparous animals were most commonly affected with this condition, there is lot of impact on milk production due to loss of teats,

resulting in great economic loss to the farmers. Dilated teat cistern was not fully reported in literatures. In buffaloes, cistern dilatation was recorded in one teat [29]. Recently, the condition was observed much more in buffaloes than cattle [30] at Upper Egypt. Teat obstruction involves the intraluminal lesions that partially or completely hinder the milk outflow. These lesions have been identified and classified in literatures [31, 32, 33, and 34]. Teat spider is met with in buffaloes and cows as a congenital as well as acquired anomaly [18, 32, 34 and 21]. Congenital condition is usually associated with improper development of the teat cistern or teat canal. Whereas acquired obstructions are caused by injury, tumor or infections. The resulting membrane, obstructing the milk flow, is either thin or thick, and is located high at the base of the teat or lower down in the cistern. Palpation reveals fluctuating milk above the obstruction but milking is not possible. In case of congenital cases with improper development of the teat cistern, it may impossible to feel the milk pocket. Treatment of such cases is not recommended, the quarter is usually allowed to atrophy and become non-functional. If the pocket of milk can be palpated, prognosis is usually considered good to favorable. According to [33], surgical treatment through the teat orifice was successful in 84% of the operated cases. After rectification with Hudson's teat spiral or small teat bistuary. Complete milking from the affected quarter is not recommended for 2-3 days in an order to avoid a stricture. Flow of the milk itself keeps the teat cistern patent [34, 35]. Concerning the teat lumen granuloma, [36] described the teat granuloma (pea) as a free-floating, irregular rubbery mass of fibrocollagenous material covered by mucosa which may develop in the teat cistern and pass down to the sphincter, thus obstructing the milk flow. [37] adopted manual expression from a surgically dilated teat orifice for the small and mobile masses but in cases which produce clinical signs, vertical incision in teat wall opposite to the mass was indicated with surgical resection followed by suturing of the teat wall. Teat stenosis: Contracted sphincter or teat orifice "hard milker": The condition may be congenital in origin or may be acquired as a result of trauma to the end of the teat. There is a small stream of milk, and prolonged milking time. There may be loss of milk due to incomplete milking or trauma to the teat due to attempts for strenuous milking methods [38, 1]. Teat stenosis resulting from mucosal lesions in the region of the streak canal or Furstenberg's rosette may be successfully treated via theloresctoscopy [39].

MATERIALS AND METHODS

Anamnesis and general examinations:

An informative data was taken from the owner regarding animal description, age, stage of milk production, onset of the disease occurrence, state of appetite, previous intervention and is there a concurrent disease or not. Each animal was subjected to general clinical examination to detect temperature, pulse,

respiratory rate and mucous membrane. Superficial and supramammary lymph nodes should be examined.

Physical examination of udder and teats:

Special physical examination of the udder was done initially by visual observation followed by digital palpation. Many undesirable features like udder asymmetry (e.g. pendulous udder) and, teat shape and placement which can help in the confirmatory diagnosis. The size of the udder often increases gradually with each lactation, becoming heavier and more pendulant with age and production. With the use of the physical examination, it is possible to select the udders most suitable for specific therapy and to identify the cows in which the disease has advanced to such extent that slaughter is indicated. The digital palpation is determined by employing the fingers and thumbs of both hands. Examine the teat orifice by turning the ends of the teats upward for a clear view. By gentle pressure note the ease of milking. To examine the teat duct and teat cistern, grasp the end of the teat with the fingers of the left hand, and pull down gently to stretch the teat. Then with the thumb and forefinger of the right hand examine the canal and cistern from the distal end (teat orifice) to the base of the udder. Abnormal lobulation or contour could be detected by this method. Probing of the teat canal and cistern to detect the intraluminal obstruction. The results of the physical examination, when correlated with other observations, may help to reach to an accurate diagnosis. Physical examination of each gland must be done on the empty udder. The most opportune time, therefore, is immediately after milking when the hormone stimulation has ceased and the udder is completely relaxed[27].

Animal restraint:

The animal was sedated using intramuscular injection of xylazine Hcl 2% (Xylaject®: The Egyptian Co. For Chemicals & Pharmaceuticals (ADWIA); 10th of Ramadan City) in a dose of 0.1mg/kg.b.wt. in cows with slight reduction of the dose in buffaloes. This is should be combined with securing of the hind limbs by a rope tightened above the hocks in a form of eight figure. Epidural analgesia with an appropriate dose of xylocaine Hcl to control the motor activity of the hind limbs whenever indicated. Intracisternal and local infiltration analgesia of the teat was performed whenever indicated in cases of teat surgery. In case of teat obstruction, infusion of lidocaine HCL 2% was used during correction of the condition. Elastic tourniquet was placed around the base of the teat to provide hemostasis during surgery. Deep penetrating recent teat wounds were sutured after cleansing, irrigation and debridement, and then insert vertical mattress suture into sub mucosal layer to the skin with vicryl, then cover the wound with adhesive tape. The insertion of Larson-teat tube to facilitate milking in hand-milking process as well as to the animal because of the pain associated with trauma. Replacing the cap

on the tube after milking to reduce the possibility of mastitis.

RESULTS

As illustrated in table 1. The results revealed that, deep wounds of the udder were encountered in five cows and one buffalo. The wound was inflicted by the cow itself due to overgrown claws or a horn gore from neighboring cow or the nail in the paddock used for securing the buffalo. All wounds were in the posterior aspect of the hind quarters longitudinally directed and penetrating the skin layer. Simple interrupted sutures were used for the wound closure (Fig.1:a&b). Teat wounds were met with in two dry and ten lactating cows. Full skin thickness wounds in the teat barrel were presented as an old contaminated and swollen with longitudinal orientation in six cases. Hydrotherapy and non steroid anti-inflammatory treatment was beneficial before primary closure of these wounds by vertical mattress sutures using vecryl (Fig.2:a&b). Distal injuries involving teat sphincter were presented later after healing in three cases and the wound revised and sutured then a tight adhesive bandage was applied after insertion of a Larson teat cannula on the teat papilla(Fig. 3:a&b). Subsequent milk leaker was seen in three cases. . Subcutaneous small udder hematomas (5 in cows) were left without surgical interference to subside spontaneously. In cases of parenchymatous hematomas with bloody milk (15 in cows and 7 in buffaloes). In all cases, varied severity from normal milk color in subcutaneous type to large clots and frank blood to a pale pink tinge of the milk. Milking of the affected quarter(s) was stopped, then siphoning of milk every other day followed by application of intramammary antibiotic to prevent mastitis. Cold water sprays on the affected quarters was helpful in blood resolve. Twenty one cases of udder abscesses were encountered in lactating cows. The entire right hind quarter was affected in two cases which evacuate a large amount of pus after surgical opening. Gangrenous mastitis was met with thirty six cows. The typical signs of acute gangrenous mastitis were remarkably evident in a first lactating heifer 24 hours after calving with involvement of the whole udder tissues. A comprehensive medicinal and surgical care led to simultaneous sloughing within six weeks (Fig. 4). This scenario was repeated in a second lactating cow with partial involvement of the distal half of the right hind quarter (Fig.5: a, b, c). The remaining cases have been treated for previous attacks of acute mastitis without curative response. A focal necrotic patches were developed anywhere on the udder, mostly on the right half. These focal areas were progressively demarcated from surrounding skin to be easily detached leaving a portal of entry for surgical removal of the necrotic parenchyma of the entire quarter (Fig.6:a,b,c). This may be done once or may last several times to avoid bleeding of the existence blood vessels. Complete obliteration of the resultant defect occurs within 2 – 3 months. Teat stenosis was met with in (50, 15) lactating

cows and buffaloes, respectively. Clinically, hard milking and strenuous efforts have been made in milking the affected teats. The condition was seen in 15 first lactating cows and mostly affects the rear teats (10 cows and 5 buffaloes) than the front ones (5 cows and 3 buffaloes). The rest of lesions were in multiparous cows and buffaloes and associated with traumatic injury, thelitis, and removal of scab at the tip of the teat and after attacks of foot and mouth disease (Fig.7: a, b, c, d). Ulcerative thelitis was encountered only in buffaloes. The sudden onset of the disease is very characteristic in a thirty primiparous buffaloes and three second lactating ones. The important clinical signs noticed include acute inflammation of one or more teats with subsequent thickening, narrowing or closure of the teat canal leading to difficult and very painful milking. There was increase in the size of the affected teats with glistening appearance followed by peeling off and ulcer formation. The affected teat showed complete or partial slough off (Fig.8: a, b, c).

Dilated teat cistern was met with in three cows and nine buffaloes. The affected teat(s) showing either allover dilatation of their cistern (Fig.9: a) or partial dilatation at its distal portion (Fig.9: b). In a one buffalo, the condition was associated with chronic mastitis and thelitis (Fig.9: c). Teat obstructions were met with in 70 cows and 15 buffaloes. Basal teat obstructions in 15 first lactating cows were considered hopeless and were encountered in rear teats and right fore teat and not recorded in first lactating buffaloes. Thirty five cases were discovered immediately after calving in multiparous lactating cows and five buffaloes with mastitis attacks in the previous lactation season. The corresponding quarters of the affected teat(s) appeared engorged with milk and an obvious wrinkled teat(s). Probing of the teat through the teat canal does not penetrate up to the gland cistern. Complete blocking at the communicating area of teat and gland cistern was

detected in cases of first lactating cows whereas in multiparous animals variable degrees of blocks could be detected motivating hand in hand with a palpable connective tissue masses at the area of obstruction. Intermittent milk flow obstruction was met with in a twenty lactating cows and ten buffaloes. A floating mass in the teat and gland sinus could be felt on palpation with gentle pressure along the teat cistern which reveals the presence of either regular or irregular sliding smooth (Fig. 10) (pea) or hard mass (lactolith) and the obstruction become complete when these masses located in the region of Furstenberg's rosette or the streak canal. The small masses were drained with milk during hand milking, while in case of the large ones, 30 ml saline were infused through the orifice which was dilated by teat dilator, then massive hand milking to help in pushing it outside.

Dropped udder was encountered only in ten cows. All cows were multiparous except in one was presented immediately after the second calving. A big udder appeared hanged from the pelvic floor down below the hock. The teats were splaying outwards with complete loss of division between the two halves (Fig.11: a, b) or may be directed inwards. The area of attachment of the udder appeared as constricted fold of skin (Fig.11: c). Anomalies of the teats were met with in 50 cows and 5 buffaloes. Supernumerary teats type 1 was encountered in 22 cows and all were located on the caudoposterior aspect of the rear quarters. Supernumerary teats type 2 was located in between the right fore and right hind teats in 17 cows and 3 buffaloes whereas, fused teats were presented in 5 cows (Fig.12) and 2 buffaloes. Supernumerary teats type 3 was recorded in 6 cows. Fused teats interfere with milking process which cause the milk splashes out. Previous attacks of mastitis were recorded in the corresponding quarters having supernumerary teats in 15 cows in particular of type 2, type 3 and fused teats.

Table-1: Incidence of some common udder and teat affections in cattle and buffaloes in Egypt

Udder/teat injuries	Subdivision	Cattle No. %	Buffaloes No. %	Total %
Deep wounds		5 (1.4%)	1(0.28%)	6 (1.67%)
Abscesses	Subcutaneous Parenchymatous	19 (5.3%) 2 (0.56%)	0 0	21 (5.83%)
Hematoma	Subcutaneous Parenchymatous	5 (1.4%) 15 (4.17%)	0 7(1.9%)	27 (7.5%)
Gangrene		36	0	36 (10%)
Dropped udder		10	0	10 (2.8%)
Teat Anomalies	Supernumerary teat typeI	22 (6.11%)	0	55 (15.3%)
	Supernumerary teat typeII	17 (4.7%)	3(0.83%)	
	Supernumerary teat typeIII	6 (1.67%)	0	
	Fused teat	5 (1.4%)	2(0.56%)	
Wounds		18 (5%)	0	18 (5%)
Ulcerative thelitis		0	33	33(9.5%)
Cistern dilatation		3 (0.83%)	9(2.5%)	12 (3.3%)
Stenosis		50 (13.9%)	15(4.2%)	65 (18.5%)
Obstruction		70 (19.4%)	15(4.2%)	85 (23.61%)
Total		275 (76.4%)	85 (23.6%)	360 (100%)

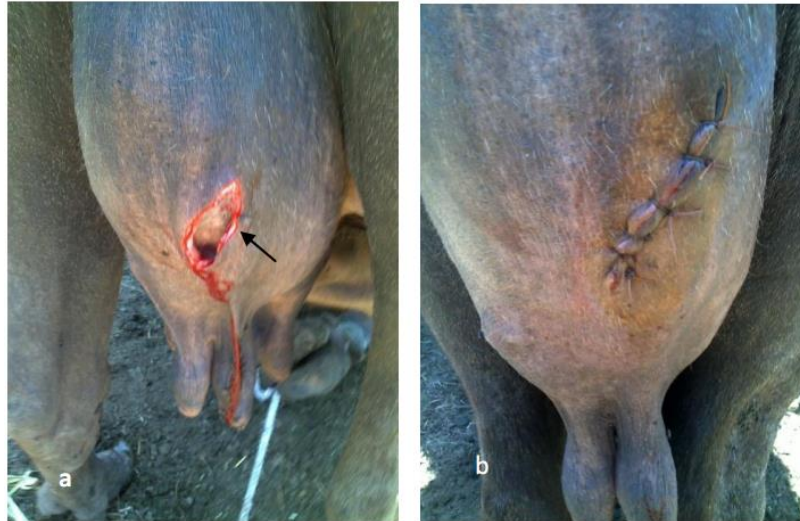

Fig-1: (a) Deep longitudinal wound on the posterior aspect of the udder in a buffalo. (b) After closure with simple interrupted suture.

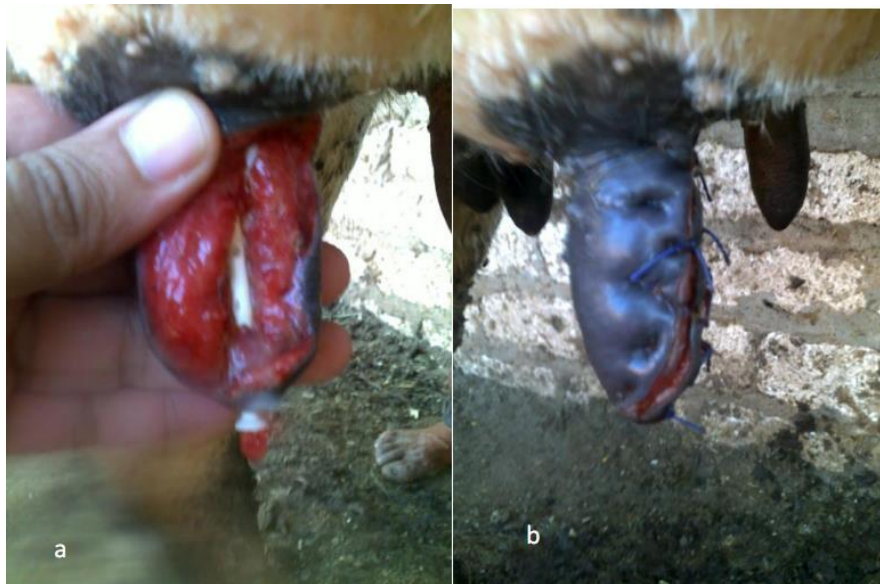

Fig-2 : (a) Longitudinal full thickness penetrating teat wound in a cow. (b): After closure with two raw of vertical mattress sutures.

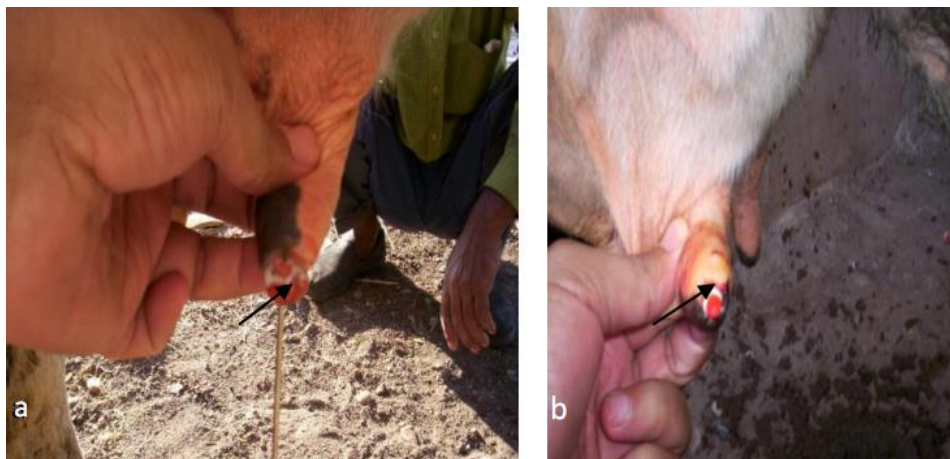

Fig-3: (a) Old distal teat injury with milk seepage in the right fore teat in a cow. (b) Insertion of a Larson teat canula after revision of the previous teat injury.

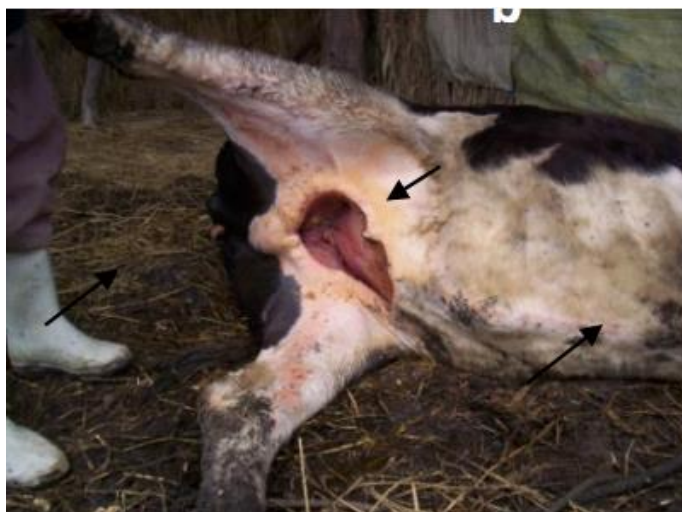

Fig-4: Complete sloughing of the udder in first lactating cow leaving a large defect

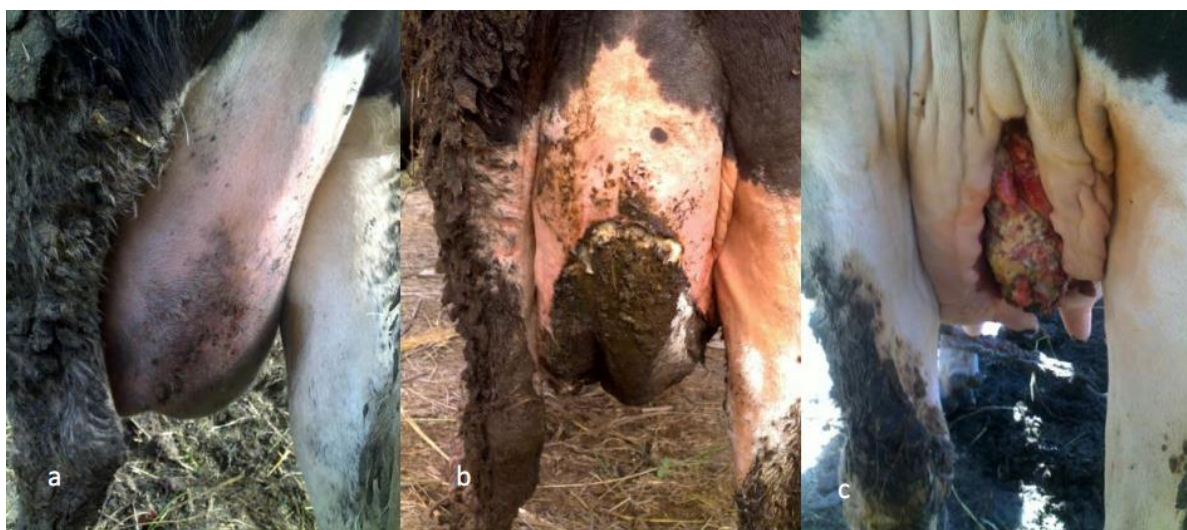

Fig-5: Gangrenous mastitis in a second lactating cow with partial involvement of the distal half of the right hind quarter. Note, the discoloration (a) then the demarcation and necrosis (b) and finally, the resultant defect following surgical removal of the affected parenchyma (c).

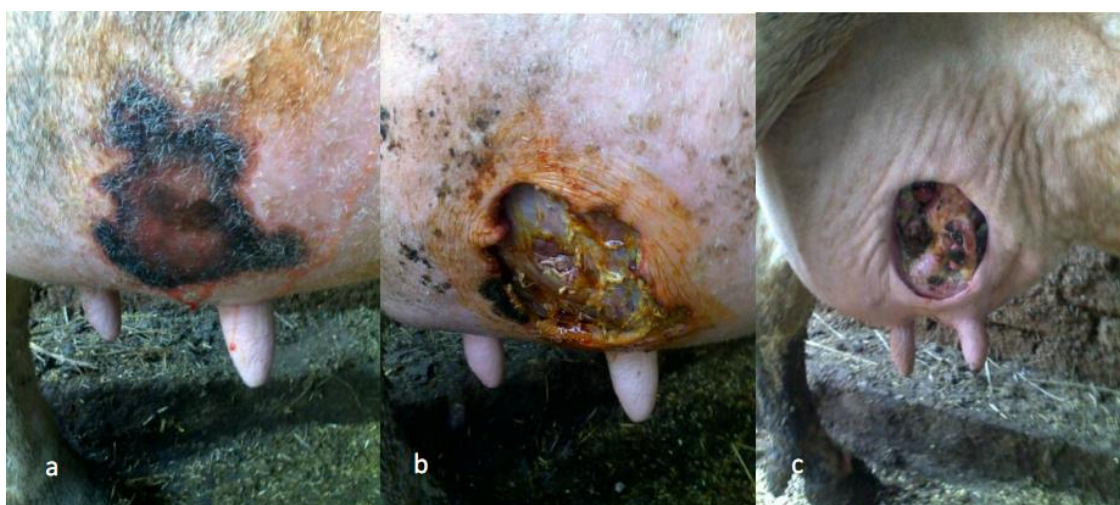
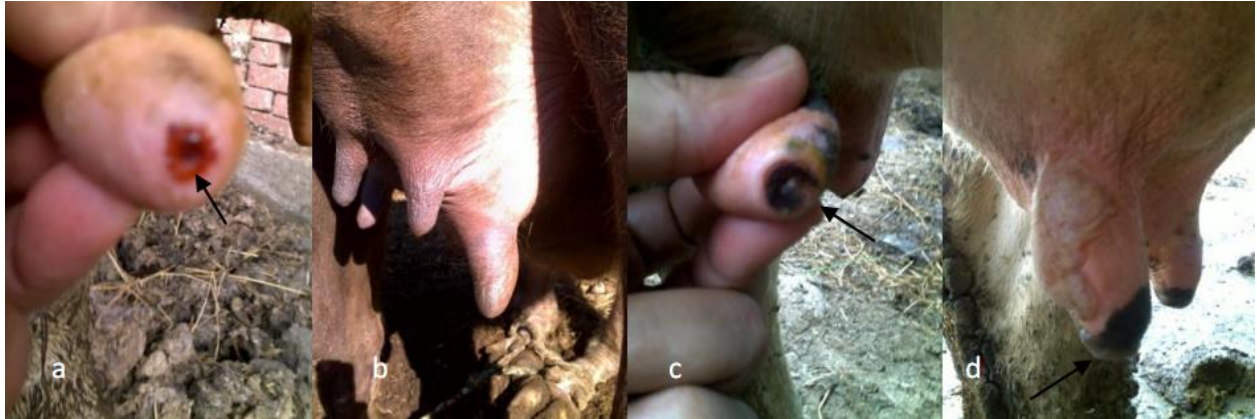
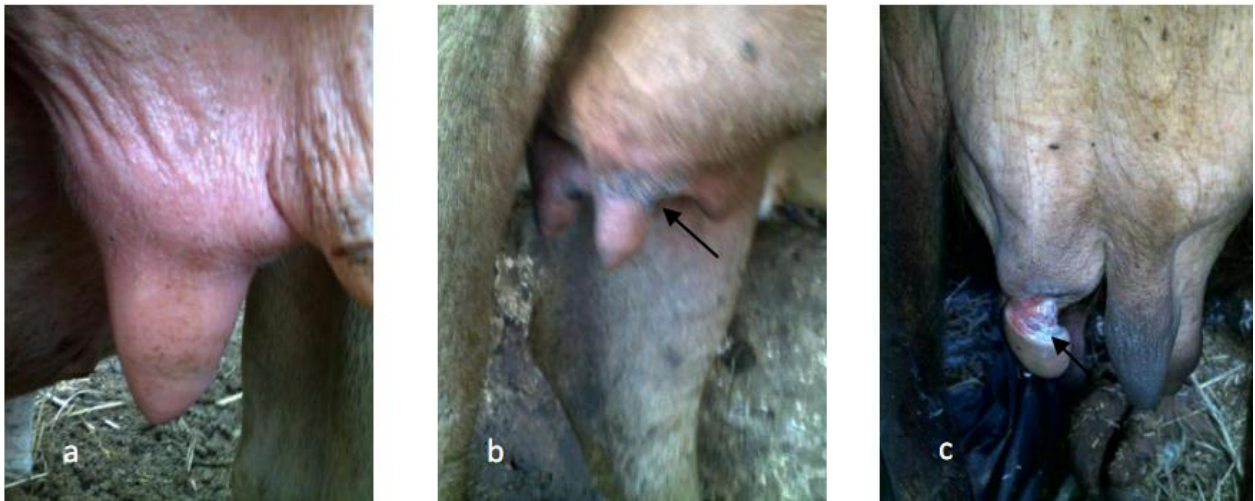
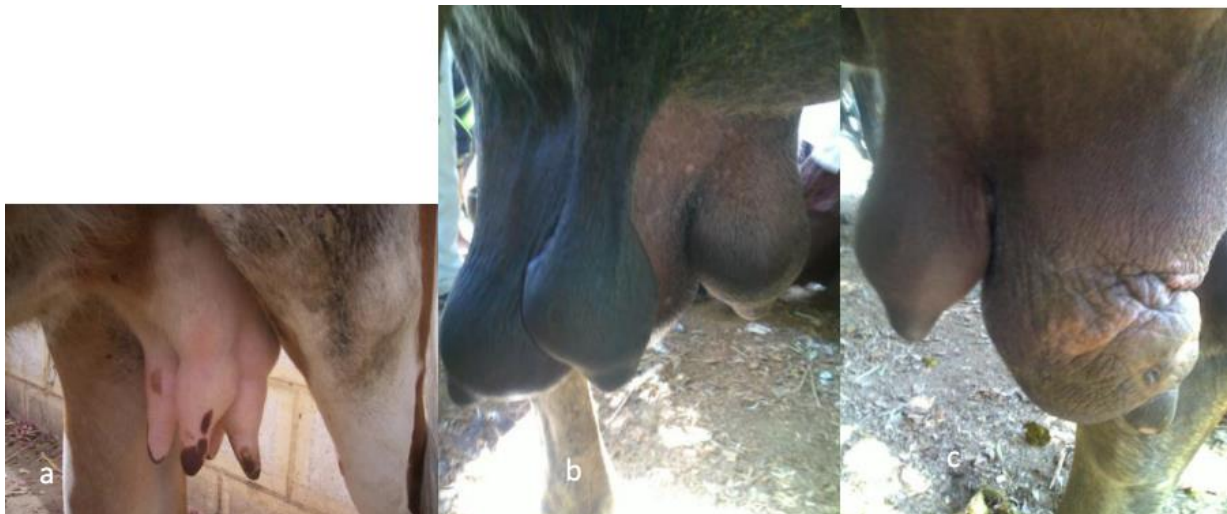
Fig-6: (a) Severe swelling with subcutaneous exudates along with a distinctive focal skin necrosis in the right fore quarter. (b) Surgical removal of the necrotic skin permeating a portal for further removal of the affected parenchymatous tissue. (c) The resultant defect going to obliterate after five weeks.



Figs-7: Different forms of teat lesions causing teat stenosis: (a) traumatic injury at the teat end in a cow,(b) Thelitis in a buffalo,(c) Scab formation at the teat orifice in a cow and (d) Vesicles of FMD involving teat orifice in a lactating cow.



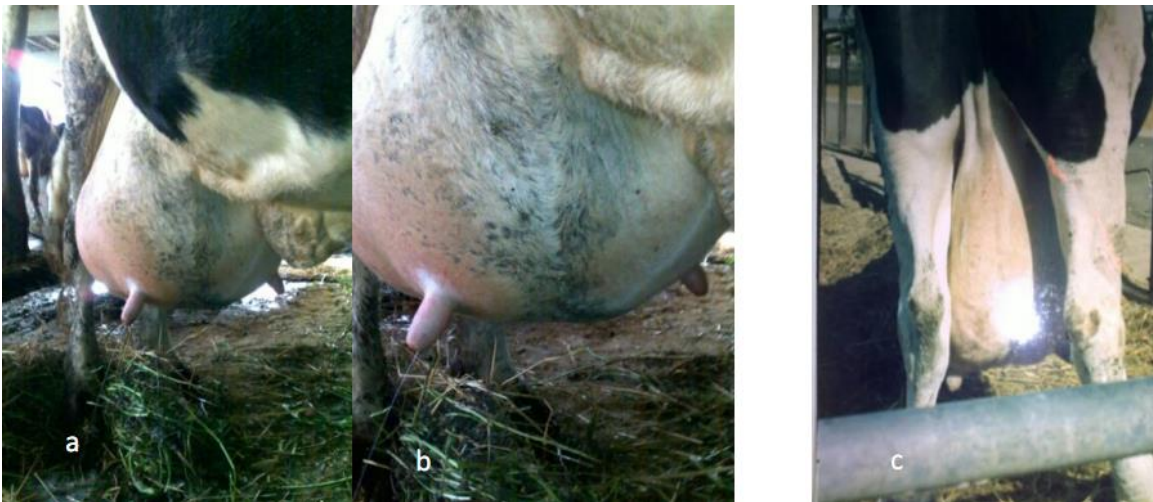
Figs-8: (a). Ulcerative thelitis in early stage form in a second lactating buffalo, (b) In necrotic stage in a first lactating buffalo and (c).after complete slough in a first lactating buffalo



Figs-9: (a) Teat cistern dilatation in a cow. (b)Teat cistern dilatation in a buffalo. (c). Note, the huge thelitis in the left hind teat in the same buffalo

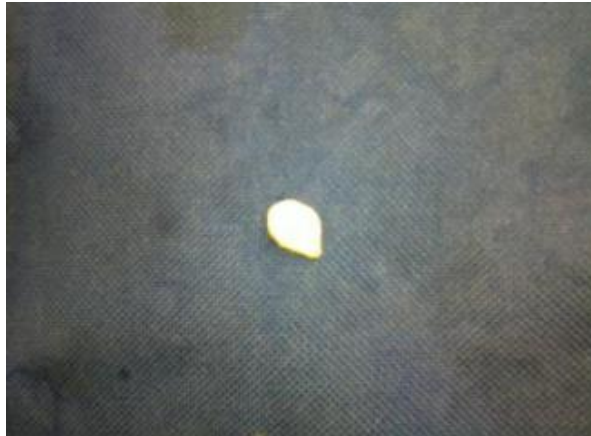

Fig. 10: Teat granuloma (pea) extracted from the teat cistern in lactating cow.



Figs. 11: (a) Dropped udder in a postparturient cow. (b) Close up view showing outward splaying of the teats along with loss of division between the two halves. (c) Posterior view in another cow showing dropped udder attached to the pelvic floor through constricted skin fold.



Fig-12: Fused teat with the left fore teat in a cow.

DISCUSSION

Veterinarians and dairy producers have been required to deal with udder and teat affections for many years. Rearing of cattle and buffaloes for milk production has been considered as an economic impact for both small holding group farmers and large dairy producers in Egypt. Studies on the surgical udder and teat affections in dairy cattle and buffaloes and their relative differences between each are scarce. The anomalies of the udder and teats in buffaloes are rarely reported as compared with those of cattle [30] in Qena, Upper Egypt, who reported that, neither udder or teat anomalies were recorded in buffaloes whereas, supernumerary teat type 1, type 2, type 4 and type 5 represents 20.7 %, 10.8 %, 4.05 % and 8.01 % in cattle. In Friesian cows and heifers, the supernumerary teat represents the higher congenital teat abnormalities (36.8 %) [21]. Previous reports found that, the incidence of supernumerary teats in Egyptian buffaloes was 1.6% [15], while Omar [16] met with 2.7% of this anomaly. In India, [17] reported 1.3 – 8.6 % of buffaloes were affected with hyperthelia. In Indian buffaloes, [19] recorded a higher incidence of teat anomalies (9.2%). A recent study records the higher incidence of polythelia 26.66%, oligothelia 8.88%, and fused teats 2.22% [20]. The lowest incidence recorded in the present study might be due to the variation in the management styles maintained by the farmers in India and Egypt rather than the cumulative genetic predisposition in Indian buffaloes. In addition to the interference in milking processes of the animals affected with teat anomalies, frequent attacks of mastitis in the corresponding quarters was evident in the present study. A finding which strongly supported by [2, 40]. Many farmers have a wrong dogma that, the presence of functioning hyperthelia is a good trait in dairy animals. Therefore, instructions should be established in extension programmes to discard the affected animals from the breeding system. It was evident that, udder abscesses were either preceded by mastitis or contusion to the udder which get infected. Local signs of the abscess were obvious and the diagnosis was confirmed by exploratory puncture [41]. The chronic suppurative form was higher in incidence and recoded only in cattle. It is worth mention that, clinical cure doesn't always mean bacteriological cure [42, 43]. A fact should be considered in mastitis treatment as almost of the recorded cases have been subjected to tentative treatment with subsequent relapse thereafter. Upon the pathological basis, the pus forming bacteria do not induce the degree of necrosis, vascular effects. These bacteria invoke a neutrophilic response that dominates the lesion and results in a buildup of necrotic leukocytic debris that typifies the suppurative response filling these with suppurative exudates [44]. Udder hematomas, regardless of the cause, are dangerous because blood accumulates subcutaneously, allowing massive blood loss. In addition, the exact location of the bleeding often impossible to determine clinically because of the extensive venous plexus. Furthermore,

the possibility of getting infection of the hematoma and/or the affected quarter(s) should be considered. However, in buffaloes [45] reported that, the etiology of hemolactia often lies in the method of milking, feeding of certain feedstuffs, vitamin C deficiency, intramammary infusion of irritants, chronic mastitis and some infections. However, the reported cases in the present study, proved complete cure within two weeks [40, 11]. It is important to use a smooth and comfortable milking technique. The knuckling or stripping method is used in the wrong belief that it is necessary in order to overcome the resistance in the teat sphincter. These milking methods might cause elongation and damage to the teats [46]. To the author's opinion, this might to be the real cause of teat cistern dilatation especially in buffaloes. A much more comfortable and appropriate method is the full hand technique. This technique imitates the calf's suckling and therefore better stimuli. However, some authors attributed this condition as a congenital defect in dairy cows and named it "bottle teat" or "teat hyperplasia" [21]. Cases of dropped udders were recorded only in cows. This could be referred to the big sized cow's udders in relative to the buffalo's one. Moreover, the heavy weight exerted on the supporting ligaments by the periparturant edema. The condition was characterized by suddenly developing pendulous udder with lateral outward or medially inward directed teats with dropping of the udder ventrally to the level of the hocks or lower. A findings which coincides with [36, 10] who reported that, breakdown of either the lateral or the medial support of the udder causes the medial longitudinal groove between the left and right halves of the udder to disappear while the loss of the lateral support laminae causes dropping of the udder ventrally to the level of the hocks or lower. The rupture of either the anterior or posterior section of the udder support ligament was not recorded in this study. However, all the various deficiencies of the udder support predispose to udder edema, teat and udder injuries and mastitis [10]. Teat stenosis expressed a wide variety of lesions which may be congenital or acquired as result of trauma of the teat end. Congenital teat stenosis was evident in four teats or affect only the rear or fore teats in first lactating animal. Whereas, the acquired lesion was mainly traumatic in origin as faulty milking process, untrimmed claws, long medial dew claws or being trotted on by the cow itself or by their neighbor animal. These traumas could result in a complete obstruction of the teat end or incontinentia lactis (Free milkers). Furthermore, ignorant interference and unprofessional treatment in the cases of teat stenosis may aggravate the condition. These observations agreed with those mentioned by [47]; [14] and [2] in cows and [16] in buffaloes. In the present study, difficult milking was also found in teats affected with ulcerative thelitis due to thickening of their walls results in narrowing the teat canal. The ruptured vesicles of foot and mouth disease especially those involving the teat orifice and result in desquamation of the mucocutaneous junction at the teat

papilla and teat canal with a tedious and very painful milking process. In a study for classification and evaluation of lesions causes milk flow obstruction, [48] pointed out just a small amount of animals (8.93%) showed causes for MFH that were inborn or non-traumatic, such as inflammations or foreign bodies. In the majority of cases (91.07%) covered teat lesions were diagnosed as causes for MFH. The inner orifice of the papillar duct and the papillar duct itself were found to be the by far most frequent locations of traumatic insult, which was diagnosed as avulsion of the mucosa in 86.16% of cases. Surgical cruciate incision at the teat papilla proved successful. Repeated treatment may be done in a few cases after one week. Acute gangrenous mastitis reported in newly calved cows were experienced severe systemic effects and necessitate comprehensive along with conservative treatment to overcome the toxemic effects of the disease. Such careful interventions were done by [12] proved successful results. The evidence of less intense symptoms with subsequent peeling off in some parts of udder skin. A common finding in affected quarters received long term inappropriate treatment. Although, the surgical intervention for enbloc dissection was tedious and take a long time in some cases, it could be easily removed or trimmed out in the most instances. However, ligation of blood vessels supplying the affected quarter to ensure ischemic necrosis and its sloughing was documented in such cases [49]. Although, a little reports documents the gangrenous mastitis in buffaloes [50, 51], it was never encountered in the present study. This is quite clearly that, buffaloes are less susceptible to mastitis than cattle due to both anatomical and physiological reasons [46, 45]. In addition to the variations in management and hygienic practices maintained for cattle and buffaloes. Based on the findings of the present study, it can be suggested that, early treatment of ulcerative thelitis with topical application of zinc oxide ointment 10% along with pure anti-inflammatory enzyme and antibiotic therapy can prevent ulceration, necrosis and consequent teat loss. The application of proples on teats at ulcerative stage speeds the healing and restores the normal milk production within two weeks. Other remedies were evaluated with a different curative efficacy in a trial carried by [22] in Murrah buffaloes. It was evident that, the absence of this lesion among cattle in the present study. However, cattle may be affected by herpes mammilitis virus II causing ulcerative thelitis with a quite wide range of lesions from animals that simply seroconvert with no lesions, to cows that become hard milkers but show no physical lesions, to animals that show mild lesions that eventually heal, to animals which show the very severe lesions. Recent histological studies have discovered the virus inclusion bodies in areas near the teat canals in cows that have simply become hard milkers with no evidence of lesions [52]. Irrespective to the superficial udder and teat wounds, the management of deep lacerations was selected to be evaluated with evidence of good healing in the udder

wounds. Actually, lacerations of the teat are variables and classified according to the duration from time of trauma, the localization and conformation of the laceration, and the thickness of the lesion (full or partial thickness). Consequently, different prognoses are associated with these classifications [5]. Unfortunately, the delayed presentation of the teat lacerations as well as being contaminated due to their situation near the ground. Despite these circumstances, refreshment of the wound edges, hydrotherapy, good apposition to the wound and finally tight bandage to the teat are contributing to good results especially in deep longitudinal lacerations. However, transverse, irregular and those involving the teat end had a poor healing and predispose to mastitis. In conclusion, the udder and teat affections are widely differ in incidence between cattle buffaloes. Some of these affections may be common or of higher incidence in cattle than buffaloes and vice versa. Primarily, this might be due to genetic factors as well as the anatomical and physiological characteristics of the buffalo's udder along with the environmental peculiarities under Egyptian relations as buffaloes are considered more resistant to diseases if compared with cattle especially those of imported or crossbred animals. The variations in the management and hygienic practices maintained for both animals should be considered.

REFERENCES

1. Tiwary R, Hoque M, Kumar B, Kumar P; Surgical condition of udder and teats in cows. *The Indian Cow* 2005; 25-27.
2. Abdel Hady AAA; Studies on the surgical udder and teat affections in dairy farms. M.V.Sc. Cairo University, Egypt. 1993.
3. Aiello SE; Udder diseases. In the merk veterinary manual, 8th edition, Whitehouse Station, NJ, USA, 1998; P. 1028.
4. Rambabu K, Sreenu M, Suresh Kumar RV, Rao TSC; Incidence Of Udder And Teat Affections In Buffaloes. *Tamilnadu J. Veterinary & Animal Sciences*, 2011; 7(6) 309-311.
5. Nichols S; Teat Surgery in cattle. In: *Current Veterinary Therapy: Food Animal Practice*. 2008; Chapter 82.
6. Contreras A, Luengo C, Sanchez A, Corrales JC; The role of intramammary pathogens in dairy goats. *Livest. Prod. Sci.*, 2003; 79, 273-283.
7. Schroeder JW; Mastitis Control Programs: Bovine Mastitis and Milking Management. 2009;[Online]. Fargo: North Dakota State University Agriculture and University Extension. Available from: <http://www.ag.ndsu.edu/pubs/ansci/dairy/as1129w.htm> [Accessed 25 May 2009].
8. Misk NA; Atlas of Veterinary Surgery, 2008; Faculty of Veterinary Medicine, Assiut University, Egypt
9. Paape MJ, Poutrel B, Contreras A, Marco JC, Capuco AV; Milk somatic cells and lactation in

- small ruminants. *J. Dairy Sci.*, 2001; 84(E. Suppl) E237-E244.
10. Lisie W; George, Thomas J. Divers, Norm Ducharme, and Frank L.W; Diseases of the Teats and Udder. In: *Rebhuns Disease of Dairy Cattle*. 2nd edition. Elsevier Health Sciences, Saunders W.B, 2008; Thomas J. Divers. 327-394.
 11. Balhara AK, Rana N, Phulia SK; Blood in milk- Causes and Control. (Online). Available form: <http://www.buffalopedia.cirb.res.in/> [Accessed in 4th April, 2014].
 12. Matthew S, Ila M, Lewis, John A, Scholten; Acute gangrenous mastitis due to *Clostridium perfringens* type A and *Escherichia coli* in a cow. *Can Vet J*, 1990; Volume 31: 523-524
 13. Jackson PGG, Cockcroft PD; Clinical examination of the udder. In: *Clinical Examination of Farm Animals*. 1st edition Blackwell Science; 2002; Chapter 12, P.154-166.
 14. Soliman AS; Bovine udder and teat affections in North Iraq. *J. V. Sc.*, 1988; 4(2): 473- 482.
 15. Khamis MY, Saleh M; Morphological studies on the buffalo teat. *Vet. Med. J. Fac. of Vet. Med.*, Cairo University, 1970; 17: 18-87.
 16. Omar MSA; Surgical affections of the buffalo udder. Thesis, M.V.Sc., Faculty of Veterinary Medicine, Cairo University, 1973.
 17. Dwivedi JN, Parbhu SS; Studies on supernumerary teats in Indian buffaloes. *J. Genet*, 1970; 60, 164-174.
 18. Fahmy L, Khamis Y, Hegazy A, Omar M; Further studies on the buffalo teat. Part I- Congenital Anomalies. *Proceedings of the 15th Arab Veterinary Medical Congress*, 1981; 21 – 26 March.
 19. Rao AVN, Murthy TS; Incidence of udder and teat anomalies in buffaloes. *Indian Veterinary Journal*, 1984; 61 (4):311-314.
 20. Rambabu K, Makkena S, Suresh Kumar RV, Rao TS; Incidence of udder and teat affections in buffaloes. *Tamilnadu J. Veterinary & Animal Sciences*, November - December, 2011;7 (6) 309-311.
 21. Nouh SR, Korittum AS, Elkammar MH, Barakat WM; Retrospective study of teat surgical affections in dairy farms of armed forces and their treatment. *Alexandria Journal of Veterinary Sciences*, 2014; 40:65-76.
 22. Lokanadhamu M, Sreedevi B, Venkata RT; Studies on etiology, symptomatology, diagnosis and therapy in ulcerative thelitis of buffaloes in Andhra Pradesh (INDIA). *Buffalo Bulletin*, 2005; Vol.24 No.3 (September) p. 56-69.
 23. Gibbs EPJ, Johnson RH, Osborne AD; The differential diagnosis of viral skin infections of bovine teat. *Veterinary Record*, 1970; 87: 602-609.
 24. Turner AJ, Morgan IR, Sykes WE; Nicholls WA; Bovine herpes mammillitis of dairy cattle in Victoria. *Australian Veterinary Journal*, 1976; 52: 170-173.
 25. Chauhan HVS, Gupta MK, Jha GJ, Pandey RS, Singh KK, Sinha RP, Prasad A; Studies on the bovine herpes mammillitis (BHM) in cattle. *Indian Veterinary Journal*, 1989; 66: 106-109.
 26. Janett F, Stauber N, Schraner E, Stocker H, Thun R; Bovine herpes mammillitis clinical symptoms and serological course. *Schweiz Arch Tierheilkd*, 2000; 142: 375-380.
 27. Sharma S, Singh KB, Oberoi MS, Sood N; Studies on the occurrence of bovine herpes mammillitis in buffaloes. *Buffalo Bulletin*, 1998; 17:79-81.
 28. Malleswara Rao UVN, Sreedevi B, Venkata Reddy T; Studies on ulcerative mammillitis of buffaloes in Andhra Pradesh (India). *Buffalo Bulletin*, 2003; 22 (4): 80-90.
 29. Misk NA; Atlas of the Common Surgical Affections in Domestic Animals, 2012; Faculty of Veterinary Medicine, Assiut University, Egypt.
 30. Abdel Kawey HA; Prevalent surgical affections in ruminants at Qena governorate. M. V. Sc. South Valley University, Egypt. 2015.
 31. Ducharme NG, Arighi M, Horney FD, Livesey MA, Hurtig MH, Pennock P; Invasive Teat Surgery in Dairy Cattle. I. Surgical Procedures and Classification of Lesions. *Can Vet J*, 1987; 28(12):757-762.
 32. Johnson L; Mammary gland. In: *Text book in Large Animal Surgery*, 2nd Ed. (ed. Oehme, F.W.). Williams and Wilkins. Baltimore, USA, 1988; 220 – 227.
 33. Alacam E, Dinc DA, Guler M; Diagnosis and treatment of various teat problems in dairy cows with special reference to radiographic techniques. *Doga, Turk Veterinerlik ve Hayavncilik Dergisi*, 1990; 14: 1-10.
 34. Singh J, Singh P, Arnold JP; The mammary glands. In: *Ruminant Surgery* (eds. Tayagi RPS and Singh J). CBS Publishers and Distributors, New Delhi, India, 1993; Pp: 167 – 174
 35. Athar M, Muhammad G, Shakoar A; Acquired contralateral teat spider in a cow and its successful treatment. *Pakistan Vet. J.*, 1999; 19 (1): 49-50.
 36. Blowey RW, Weaver AD; A color atlas of diseases and disorders of cattle. London provider, Nolfe, 1991; Chapter II, Udder and teat disorders. 177 – 188.
 37. Weaver AD; Teat Surgery. *Bovine surgery and Lameness*, Blackwell Scientific Publications, 1986; 141- 149.
 38. Singh P, Singh J, Sharma PD; Surgical conditions of udder and teats in buffaloes. *Intas Polivet*, 2003; 4(II): 362-365.
 39. Bleul UT, Schwantag SC, Bachofner C, Hassig MR, Khan WK; Milk flow and udder health in cows after treatment of covered teat injuries via thelorescopy: 52 cases (2000 – 2002). *JAVMA*, 2005; 226(7):1119 – 23.
 40. Weaver DA, Blowey R; Color Atlas of Diseases and Disorders of Cattle. Chapter 11: Udder and teat

-
- disorders, 2011; 203- 218 Elsevier Health Sciences – Amazon.com
41. Tyagi RPS, Singh J; Ruminant surgery. 2nd Ed. New Delhi, CBS, 2001; Publishers & Distributers.
 42. Preez JH du; Bovine mastitis therapy and why it fails. Journal of the South African Veterinary Association, 2000; 71(3): 201–208 (En.). Technology Transfer Division, ARC – Onderstepoort Veterinary Institute, Private Bag X05, Onderstepoort, 0110 South Africa.
 43. Mills B; Mastitis treatment: Extended therapy gives more flexibility. Dairy basis–Herd Health, April. 2014; 13: 13.
 44. Mc Gavin MD, Zachary JF; Pathologic Basis of Veterinary Diseases. 2012; Chapter 18 Female Reproductive System and Mammary Gland. 1125
 45. Purohit GN, Mitesh Gaur, Chandra Shekher; Mammary gland pathologies in the parturient buffalo. Asian Pacific Journal of Reproduction, 2014; 3(4): 322-336.
 46. Borghese A, Rasmussen M, Thomas CS; Milking management of dairy buffalo. Ital.J.Anim.Sci., 2007; vol. 6, (Suppl. 2), 39-50.
 47. Heidrich HJ, Renks W; Diseases of the mammary glands of domestic animals. W.B. Saunders Company, 1967; Philadelphia and London.
 48. Seeh C , Melle T, Medl M, Hospes R; Systematic classification of milk flow obstruction in cattle using endoscopic findings with special consideration of hidden teat injuries. Tierarztl Prax Ausg Grosstiere Nutztiere, 1998; 26(4):174-86
 49. Horney FD; Bovine skin and mammary gland. In: Jennings PB, ed. The Practice of Large Animal Surgery. Philidelphia: WB Saunders, 1984; 263-271.
 50. Singh BK, Singh SV, Singh HN; Gangrenous mastitis in a buffalo – A case report. Intas Polivet, 2006; 7. Pp 16 – 17.
 51. Singh KP, Singh SV, Singh JP; Therapeutic management of gangrenous mastitis in buffaloes. Intas Polivet, 2008; 9. Pp 255 – 257.
 52. Farnsworth RJ; Observations on Teat Lesions. National Mastitis Council Annual Meeting Proceedings, 1996; pg. 93.