

## **Surgical Correction of Intestinal Obstruction in a German Shepherd Dog**

**M. Raghunath<sup>1</sup>, P. Vidya Sagar<sup>2</sup>, B. Sailaja<sup>2</sup>, P. Ravi Kumar<sup>2</sup>**

<sup>1</sup>Associate Professor & Head, Dpt. Of TVCC, Teaching Veterinary Clinical Complex, N.T.R. College of Veterinary Science, SVVU, Gannavaram, Krishna (Dt.), Andhra Pradesh-521301

<sup>2</sup>Assistant Professor, Dept. of Surgery & Radiology, Teaching Veterinary Clinical Complex, N.T.R. College of Veterinary Science, SVVU, Gannavaram, Krishna (Dt.), Andhra Pradesh-521301

### **\*Corresponding Authors**

**Name:** P. Ravi Kumar

**Email:** [doctorpentyala@gmail.com](mailto:doctorpentyala@gmail.com)

---

**Abstract:** A 15 month old German shepherd dog was presented with a history of chronic vomitions, anorexia, dehydration and loss of condition. Physical examination revealed a hard palpable object in mid abdominal region and lateral abdominal radiograph revealed a radiolucent foreign body with moderate distension of intestinal loops. Emergency exploratory enterotomy was performed and maize corn was retrieved. The animal recovered uneventfully and started taking normal food without any post-operative complications.

**Keywords:** Maize corn, Intestinal foreign body, Enterotomy, Management

---

### **INTRODUCTION**

Gastro intestinal obstruction can result from neoplasia, foreign bodies, polyps, gastric dilatation, volvulus, gastric hypertrophy, intussusceptions and incarceration [1]. Surgical interventions related to the treatment of small intestinal obstruction represents approximately 0.5-1 percent of all surgical procedures in dogs [2].

The present paper describes the surgical management of intestinal obstruction due to a radiolucent foreign body, maize corn in a German shepherd dog.

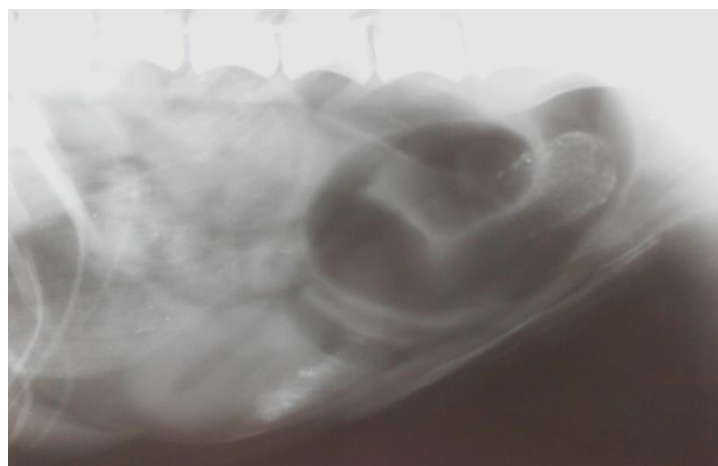
### **CASE HISTORY AND CLINICAL OBSERVATIONS**

A 6 month old male German shepherd dog weighing 15kg was presented to the teaching veterinary

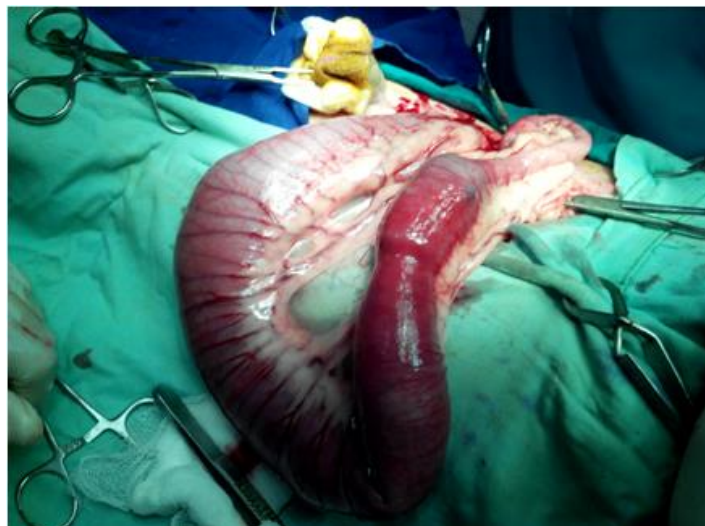clinical complex with a history of chronic vomitions with in 15 min after feeding since 2 days. Physical examination revealed moderate dehydration, sunken eyes and pale mucus membranes.

Abdominal palpation revealed a hard intra-abdominal mass and lateral radiograph of caudal abdomen revealed gas filled moderately distended intestinal loops and a radio lucent foreign body, in the caudal abdominal region (Fig. 1). Haematological examination showed anaemia and mild neutrophilia.

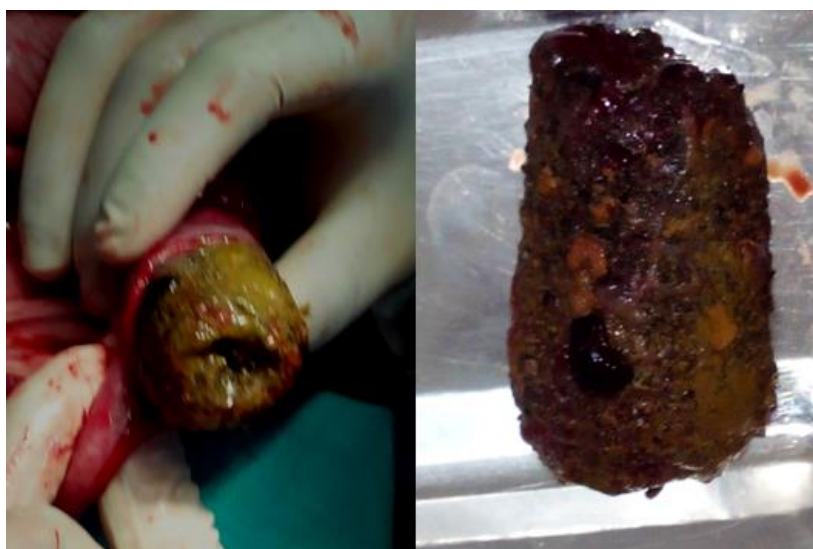Based on the clinical and radiographic examination the case was diagnosed as intestinal obstruction due to a radiolucent foreign body and prepared for the emergency exploratory laparotomy.



**Fig-1: Photo radiograph showing obstruction of radiolucent foreign body and gas filled loop of intestine at caudal abdominal region**



**Fig-2: Photograph showing obstruction of foreign body at caudal jejunum**



**Fig-3: Photograph showing removal of maize corn from the caudal jejunum**

### **TREATMENT AND DISCUSSION**

After routine aseptic surgical preparation, the dog was premedicated with atropine sulphate @ 0.04 mg/kg body weight subcutaneously and general anaesthesia was induced with diazepam @0.5 mg/kg body weight and thiopentone sodium hydrochloride @ 10mg/kg body weight intravenously and maintained by inhalant anaesthesia using isoflurane. Ringers lactate was administered pre operatively and throughout the operation period until it recovered from anaesthesia.

Exploratory laparotomy through ventral midline incision was performed. Exteriorization of intestine revealed obstruction at caudal portion of jejunum (Fig. 2).The abdomen was packed with sterile drape to prevent spillage of intestinal contents into the peritoneal cavity. A full thickness stab incision was made distal to the foreign body and maize corn was removed (Fig. 3).The enterotomy incision was closed with no 3-0 vicryl in double layer simple continuous

apposition suture pattern. The loops of intestine were thoroughly lavaged with normal saline and checked for patency before repositioned into the abdomen. Laparotomy incision was closed in routine manner with no 1 vicryl in simple interrupted pattern. The animal was recovered uneventfully from anaesthesia.

Post operatively the dog was administered cefotaxim @ 20 mg/kg bwt twice daily for 7 days, atropine sulphate @0.04 mg/kg bwt subcutaneously once a day for 3 days; meloxicam@ 0.2 mg/kg bwt and ranitidine@ 0.5mg/kg b wt intramuscularly once a day for 3 days. Antiseptic dressing was performed daily and sutures were removed on 12th post operative day.

An oral liquid diet was started 24 h after surgery and solid diet was started after 3 days. Intravenous fluid therapy using 250ml of normal saline and 250ml of ringers lactate solution twice daily was given for 3 days to counter act dehydration and acid

---

base imbalances. The dog was recovered and started normal solid and liquid food intake after 3 days. Obstructive condition of alimentary tract was one of the most common ailments noticed in dogs. The higher incidence of GIT obstruction reported in young male dogs might be because of their voracious, indiscriminate feeding habits and playful nature [3]. In the present case, maize corn was by passed through the pylorus and obstructed in the distal jejunum. Obstruction due to foreign bodies most often occurs in small intestine due to its smaller luminal diameter [4].

Most common foreign bodies retrieved in canine gastrointestinal obstruction include stones, plastics, fabrics, coins, rubber objects, food wrappings, bottle caps, fish hooks, sewing needles, marbles, corn cobs, hair balls, fruit seeds, tampons and bones [4]. Symptomology of intestinal obstruction is usually nonspecific which include vomitions which do not respond to antiemetic, anorexia, dehydration and loss of condition as observed in the present case [5]. Along with the clinical signs abdominal palpation helps in making a presumptive diagnosis in git obstruction [6]. The common post-operative complications after enterotomy include intestinal suture dehiscence leading to peritonitis and ileus. In the present case, none of these complications were observed and recovered uneventfully.

## REFERENCES

1. Atray M, Raghunath M, Singh T, Saini NS; Ultrasonographic diagnosis and surgical management of double intestinal intussusception in 3 dogs. *The Canadian Veterinary Journal*, 2012; 53(8):860.
2. Crha M, Lorenzova J, Urbanova L, Fitchel T, Necas A; Effect of preoperative motility in dogs with small bowel obstruction. *Acta veterinaria Brno*, 2008; 77:257-261.
3. Kumar DD, Ameerjan K, David WA; Gasro intestinal tract obstruction in dogs. *I J VER SUR*, 2000; 21: 43-44.
4. Papazoglou LG, Patsikas MN, Rallis T; Intestinal foreign bodies in dogs and cats. *Comp on con edu for the pract vet.*, 2003; 25: 830-43.
5. Capak D, Berrick A, Harapin I, Mticiv D, Radisic B; Treatment of the foreign body induced occlusive ileus in dogs. *Veterinary archive*, 2001; 71: 345-59.
6. Pepler C, Amort M, Thiel C, Kramer M; Linear foreign body as a cause of ileus in cats- incidence, diagnosis and treatment. *Small animal vet pract.*, 2008; 38:437-42.