

## Clinical, Cytological and Chemotherapy aspects of Plasmacytoid Sticker Tumor in a dog – case report

Ana Paula de Farias Rocha<sup>1</sup>, Aline Rocha Nunes<sup>2</sup>, Vivian Hirdes Beskow<sup>2</sup>, Katiellen Ribeiro das Neves<sup>2</sup>, Marta Zielke<sup>2</sup>, Jéssica Hellen Bastos Lavadouro<sup>2</sup>, Viégas Abdala<sup>2</sup> Luiz Fernando Jantzen Gaspar<sup>2</sup>, Luzia Cristina Lencioni Sampaio<sup>2\*</sup>

<sup>1</sup>Department of Veterinary Clinics, Faculty of Veterinary, Universidade da Região da Campanha – Bagé, RS (URCAMP), Brazil.

<sup>2</sup>Department of Veterinary Clinics, Faculty of Veterinary, Universidade Federal de Pelotas (UFPeL), Brazil.

### \*Corresponding Authors

**Name:** Luzia Cristina Lencioni Sampaio

**Email:** [sampaio.cris@gmail.com](mailto:sampaio.cris@gmail.com)

**Abstract:** Sticker tumor or transmissible venereal tumor (TVT) is a contagious cancer of high prevalence in dogs which spread usually occurs through sexual contact. Macroscopically are cauliflower-like and can be pedunculated, nodular, papillary or multilobulated. During palpation, the tumor shows firm consistency, friable and hemorrhagic. Often the surface displays ulcerations. Clinical signs associated with cytology findings allow the diagnosis of the disease. This report aims to describe the clinical and cytological findings of a Plasmacytoid Sticker Tumor diagnosed in a male canine, as well as the involution of the tumor after the established antineoplastic therapy.

**Keywords:** Transmissible Venereal Tumor, TVT, vincristine sulfate, cancer, neoplasia

### INTRODUCTION

Sticker tumor or Transmissible Venereal Tumor (TVT) is a contagious cancer of high prevalence in Brazil [1]. The spread occurs most commonly through sexual contact, although it can be transmitted through licking or direct contact with affected sites [2]. It presents a single or multiple forms, being located in the mucosa of the external genitalia, nose, mouth, eyes or skin. In rare cases it can extend into adjacent tissues and reach the lymphatic and /or blood stream, causing metastases in other organs distant from the primary site such as the breast, lung, spleen and brain. In primary sites have structure like cauliflower, pedunculated, nodular, papillary or multilobulated. During palpation, the tumor shows firm consistency, friable, hemorrhagic and often the surface displays ulcerations [3].

These tumors are classified according to morphology of the predominant cell type in: plasmacytoid TVT and lymphocytoid TVT. Plasmacytoid tumor has ovoid morphology, more abundant cytoplasm and eccentric nucleus; while lymphocytoids tumors have rounded morphology, little and finely granular cytoplasm with presence of vacuoles that accompany the periphery of the cell. The nucleus is central, rounded, with coarse chromatin present and one or two prominent nucleoli. The significant difference in DNA damage between TVT cell types indicates the existence of distinct cell lineages in which the type plasmacytoid is associated with higher amounts of DNA breaks. In view of this, it is believed that this type is more aggressive and has a

higher degree of malignancy, compared with the lymphocytoid or mixed morphology [4]. Diagnosis is based on clinical signs, macroscopic characteristics and cytological or histopathological findings. Cytology is often the method of choice [5].

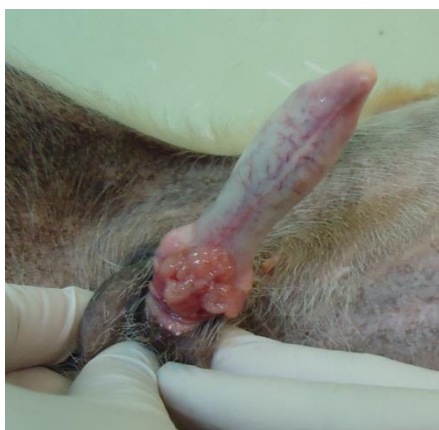The most effective treatments are chemotherapy, particularly vincristine sulfate, and radiotherapy. Most of these tumors respond very well to treatment with vincristine sulfate; but others, both genital and extragenital, may prove unresponsive. In these cases the recommended treatment includes doxorubicin, methotrexate or radiotherapy [1]. This report aims to describe a case of Plasmacytoid Sticker Tumor in a male canine, as well as its clinical, diagnostic and therapeutic implications.

### CASE HISTORY

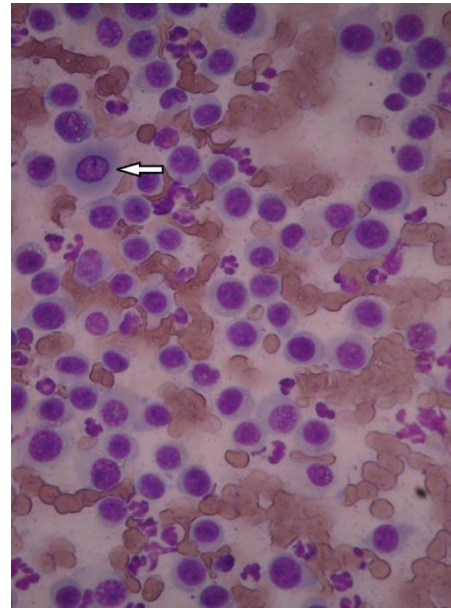
A male canine, cross breed, about 12 years old, 13.5 kg, was referred to the Veterinary Hospital of the Federal University of Pelotas (HCV-UFPeL). The patient was removed from the street and taken to clinical evaluation, when it was observed vision impairment with presence of pigmentation in both corneas and intense pruritus in both ear canals. All the other parameters assessed during the physical examination were within physiological limits. The examination of the genital area detected, after complete exposure of the penis, injury with cauliflower appearance, about 3 cm, erythematous, irregular, friable and hemorrhagic (Figure 1). Palpation revealed the presence of an adhered mass of soft consistency. No

other dermatologic or systemic change was detected during clinical examination.

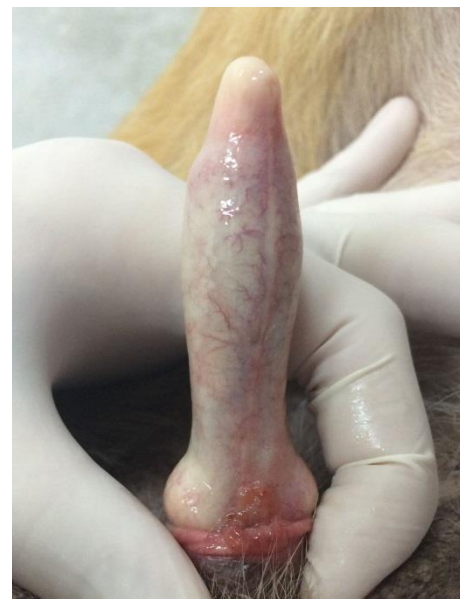
Samples were collected through "imprint" of penile mass to perform cytological examination. Cytology showed the presence of ovoid cells with eccentric nuclei and abundant cytoplasm (Figure 2). Considering the cell pattern observed in cytological examination and the clinical characteristics of the lesion, we conclude that this is Sticker tumor subtype plasmacytoid. Prior to the start of treatment was carried out blood count and biochemical analysis of the enzyme alkaline phosphatase (AP), alanine aminotransferase (ALT), aspartate aminotransferase (AST), creatinine and urea, as well as albumin. No alterations were detected in the results of the examinations. Then, antineoplastic therapy was established with vincristine sulfate, 0.5 mg /m<sup>2</sup> intravenously weekly, until tumor remission. After the first administration of vincristine sulfate, there was a reduction of approximately 30% of penile tumor mass. In the second application was observed reduction of around 20% more mass. In the third session, the dose of antineoplastic went to 0.7mg/m<sup>2</sup> in order to increase the therapeutic response. Hematological and blood chemistry monitoring was performed weekly, during the drug administration period; aiming to detect any changes resulting from the use of this drug. No changes were observed in the red blood cells during the period. There was mild leucopenia with significant reduction in total leukocyte count and neutrophils after the first administration, but these values fluctuated during the rest periods. Serum levels of AP, ALT, AST, urea and creatinine enzymes, as well as the serum albumin levels remained physiological parameters during the chemotherapy period. After the end of the three chemotherapy sessions, there was obtained complete remission of the tumor (Figure 3). One last chemotherapy session was held in the fourth week for excluding the possibility of presence, even minimal, of tumor cells. The negative for TVT was obtained by cytological examination by fine needle aspiration and "imprint" (Figure 4).



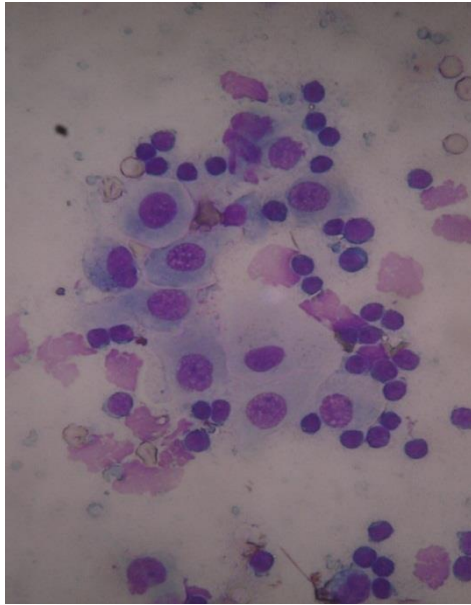
**Fig 1: Injury with cauliflower appearance, erythematous, irregular, friable and hemorrhagic approximately 3cm**



**Fig 2: Observe oval morphology of cells, eccentric nucleus, loose chromatin, with abundant basophilic cytoplasm and discretely vacuolated (TVT type plasmacytoid). (1000x)**



**Fig 3: Complete remission of tumor after the third week of treatment**



**Fig 4: Cytomorphology after the last chemotherapy session. Note the presence of superficial epithelial cells, small lymphocytes, and degenerated material. Noteworthy is the absence of typical cell TVT. (1000x).**

## DISCUSSION

Sticker tumors are tumors with unique characteristics, preferred location in external genitals and look like cauliflower. The pedunculated, nodular, papillary or multilobulated appearance; as well as firm, crumbly and hemorrhagic consistency, is characteristics of this type of cancer [3, 6]. In the present study we observed a tumor in the male genitalia of a canine patient with characteristics very similar to those described in the literature. The cytological evaluation of the tumor allows the determination of diagnosis of TVT, with or without histopathology [7]. Furthermore, the technique is simple to use, minimally invasive, fast and low cost [3]. In our study we used the “imprint” method (printing on microscope slide) for cytological assessment and we identified characteristic cell pattern of Sticker tumor.

The TVT diagnosed was classified as plasmacytoid, in view of its present aspect cells similar to plasma cells. According to some authors, the plasmacytoid tumors have higher malignancy and often show poor responses to chemotherapy treatment [8]. In our study we observed that the patients responded favorably to chemotherapy with vincristine sulfate intravenously, with regression of the tumor tissue after the second administration of chemotherapy and complete physical and cytological regression after the third application. Our results were similar to those reported by Olgivie [9], which achieved cure in 90% of dogs with TVT plasmacytoid after 3 vincristine sulfate applications.

Successes and failures of therapy with vincristine sulfate have been described in the literature.

Some authors have reported that tumors in advanced stage not satisfactorily respond to treatment as vincristine sulfate, whose effectiveness is higher in tumors diagnosed early [10, 11]. Other studies analyzed the mitochondrial DNA fragments TVT and observed the existence of different cell lines with different levels of aggressivity, which might also explain the variation of response to chemotherapy [12]. It was not possible to determine the time course of tumor of this report, given that it was a stray dog.

Hematologic findings previously found the beginning of antineoplastic therapy showed RBC and leukocyte levels within normal values. We observed that the evaluated parameters related to red blood cells did not change throughout the treatment period. The leukocytic values showed an initial drop in the first week after treatment and remained swings up and down throughout the period. However, there was no significant leukopenia in time, suggesting that the prescribed therapy has low toxicity on these cells.

Some authors report changes in serum levels of certain liver enzymes due to treatment with vincristine sulfate. These changes are attributed to hepatic metabolism and biliary excretion of the drug [13, 14]. We found no changes in enzymes evaluated throughout the treatment period. We believe that the protocol used in this patient and the finding of no previous liver damage treatment contributed to the therapy did not result in damage to liver function. Also, we did not find changes in levels of urea and creatinine. Our results agree with those described in the literature when referring to the lack of toxicity of this antineoplastic drug on renal function [15].

## CONCLUSION

Sticker tumor is a neoplasm with unique clinical features and can be diagnosed accurately, quickly and inexpensively through cytological evaluation. Therapy with Vincristine sulfate is effective even for tumors of plasmacytoid type with no or minimal liver and renal toxicity. The prevalence of this cancer is high in places where there is no effective population control of dogs. Therefore, there is an urgent need to implement preventive measures to reduce spending, the morbidity and mortality caused by the disease.

## REFERENCES

1. Brandão CVS, Borges AG, Ranzani JJT, Rahal SC, Teixeira CR, Rocha NS; Tumor venéreo transmissível: estudo retrospectivo de 127 casos (1998-2000). - Rev. Educ. Contin. CRMV-SP - São Paulo. 2002; 5: 25-31
2. Nelson RW, Couto CG; Medicina Interna de Pequenos Animais 4ed, Elsevier, Rio de Janeiro – RJ, 2010.
3. Nielsen SW, Kennedy PC; Tumors of the genital systems. In: Tumors in domestic animals. -

- 
- University of California Press - Los Angeles. 1990; 3: 479-517.
4. Amaral AS; Tumor venéreo transmissível canino: critérios citológicos de malignidade e caracterização citomorfológica correlacionada a imunocitoquímica e lesões de DNA. -Tese (Doutorado - Faculdade de Medicina Veterinária e Zootecnia, Universidade Estadual Paulista) – Botucatu. 2005
  5. Lorimier LP, Fan TM; Canine Transmissible Venereal Tumor. In: Withrow S J, Vail DM: Small Animal Clinical Oncology. Philadelphia. 2007; 799-804
  6. Batamuzi EK, Bittegeko SBP; Anal and perianal transmissible venereal tumour in a bitch - Veterinary Record, 1991; 129:25-26.
  7. Rocha NS; Citologia aspirativa por agulha fina em medicina veterinária (I). Cães e Gatos. 1998; 75: 15-16.
  8. Amaral AS, Silva SB, Ferreira I, Fonseca LS, Andrade FHE, Gaspar LFJ, Rocha NS; Cytomorphological characterization of transmissible canine venereal. - Revista Portuguesa de Ciências Veterinárias - Lisboa. 2007; 102: 563-564.
  9. Olgivie GK; Chemotherapy. In: Withrow JS, MacEwen EG. Small Animal Clinical Oncology. Philadelphia. 1996; 70.
  10. Boscos CM, Tontis DK, Samartzi FC; Cutaneous involvement of TVT in dogs: a report of two cases - Canine Practice – 1999; 24: 6-11.
  11. Pérez J, Bautista MJ, Carrasco L, Gómez-Villamandos JC, Mozos E; Primary extragenital occurrence of transmissible venereal tumors: three case reports. - Canine Practice – 1994; 19:7-10.
  12. Murgia C, Pritchard JK, Kim SY, Fassati A, Weiss RA; Clonal origin and evolution of a transmissible cancer. – Cell. 2006; 126: 477-487.
  13. Hoque M, Singh GR, Pawde A; Electrosurgery versus scalpel surgery in canine transmissible venereal tumor. - Indian Journal of Veterinary Research – Nova Déli. 1995; 4:51-54.
  14. Perez RR, Silva MAML, Varzim FLB, Oliveira SB, Hucke EETS; Ação do decanoato de nandrolona sobre parâmetros hematológicos e proteína total plasmática de ratos com depressão medular induzida após a administração de sulfato de vincristina. - Ciência Rural - Santa Maria, 2005; 35: 11-22.
  15. Gandotra VK, Chauhan FS, Sharma RD; Occurrence of canine transmissible venereal tumor and evaluation of two treatments. - Indian Veterinary Journal – 1993; 70:854-857.