

## Endoscopic Balloon Dilation of Rectal Stricture and Intramural Use of Triamcinolone in A Canine – Case Report

Vanessa Milech<sup>1\*</sup>, Álvaro José Chávez Silva<sup>1,2</sup>, Anelise Bonilla Trindade<sup>1</sup>, Michelli Westphal de Ataíde<sup>1</sup>, Hellen Fialho Hartmann<sup>1</sup>, Luciana Gonçalves Teixeira<sup>1</sup>, Roberta do Nascimento Libardoni<sup>1</sup>, Maurício Veloso Brun<sup>3</sup>

<sup>1</sup>Laboratory of Experimental Surgery, University Veterinary Hospital, Federal University of Santa Maria, Santa Maria, Brazil

<sup>2</sup>Department of Animal Welfare, National Autonomous University of Nicaragua, Leon, Nicaragua

<sup>3</sup>Department of Small Animal Clinics, Federal University of Santa Maria, Santa Maria, Brazil

### Case Report

#### \*Corresponding author

Vanessa Milech

#### Article History

Received: 06.06.2018

Accepted: 18.06.2018

Published: 30.06.2018

#### DOI:

10.36347/sjavs.2018.v05i06.007



**Abstract:** This case report presents a surgical case of rectal stricture, resulting from a surgical resection, which used endoscopic dilation therapy, associated with intramural triamcinolone application. A male canine showing dischezia and hematochezia, diagnosed with rectal neoplasm through colonoscopy. The patient was submitted to two surgical procedures for neoplasm resection, presenting post-surgical rectal stricture, undergoing two sessions of endoscopic balloon dilation and intramural application of triamcinolone. The triamcinolone associated with endoscopic balloon dilation was efficient in the treatment of this patient's rectal stricture.

**Keywords:** Colonoscopy, corticosteroids, endotracheal tube, neoplasm.

### INTRODUCTION

Intestinal tumors in dogs frequently affects the rectum and colon, meanwhile in felines, they commonly manifest on the small intestine [1], colorectal adenocarcinoma is a rare tumor in dogs [2]. Surgical resection is the main treatment for tumors, however, stricture may occur in consequence of the post-surgical inflammatory and fibrotic process [3], resulting in partial or complete obstruction [4].

Treatment for rectal stricture was limited to surgical interventions. Although, surgery does not eliminate the stricture possibility or the occurrence of post-surgical complications, therefore, it has been substituted for endoscopic balloon dilation that has proved to be efficient [3], with or without intralesional steroid application, considered the most common treatment method of benign rectal stricture in humans [4], and esophageal stricture in cats and dogs [5].

Triamcinolone stands out as a choice for hardly treatable stenotic lesions since it is believed that it interferes with the collagen's "crosslink", which results in wound retractions, and decreases the inflammatory response [6].

This case report aims to describe a clinical surgical case in which the association of modified endoscopic balloon dilation with intramural application of triamcinolone was used as a rectal treatment of stenosis, resulting from malignant surgical resection of neoplasm.

### CASE REPORT

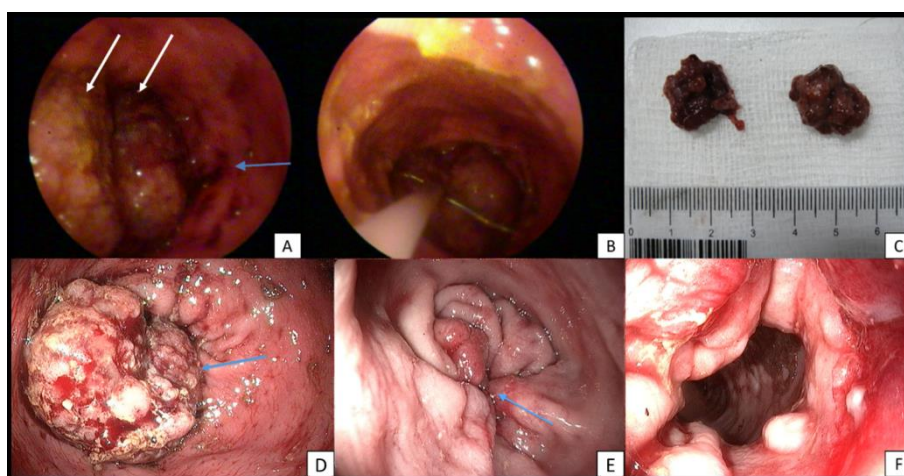
An eight – year – old, German shepherd, male dog, showing dyschezia and hematochezia attended a private veterinary clinic. With no alteration detected by the laboratory tests, the patient was referred for a colonoscopy, in which were observed, irregular and

hemorrhagic neoformations, approximately 8 centimeters away from the anus, which obstructed 90% of the rectal lumen (Figure 1A). Through a polypectomy loop, fragments were collected for a histological investigation (Figure 1B), two fragments were removed by strangling, measuring 2.5 x 2.0 cm each (Figure 1C).

Approximately 30 days after the first colonoscopy, the patient was referred to the University Veterinary Hospital of the Federal University of Santa Maria. A new colonoscopy was performed, whereas was determined the presence of a single neoplasm proliferation, of considerable extent, involving the inner anal sphincter region (Figure 1D). The dissection of the neoplasms was performed through retro – rectal traction of the neoplasms using standard hemostatic clamps at the edges of the lesion, and to the muscular layer in some portions, followed by the exeresis, then a 3 – 0

polydioxanone suture was applied in a simple interrupted stitch. However, at 20<sup>th</sup> day post-surgery, the patient presented accentuated dyschezia, and its feces presented an extremely reduced size, thereafter it was submitted to a new colonoscopy that confirmed stricture (Figure 1E). It was opted for starting the first endoscopic dilation but using endotracheal tubes of different sizes (initially tubes of size 8), that permitted distension of the cuffs filled with NaCl 0.9%. In each procedure, four dilations, of two minutes per session, were performed. After the second initial dilation, a greater diameter tube was employed (n° 10) to amplify the intestinal lumen.

A new dilation was promoted nine days after the first. In both cases, triamcinolone was used in a 40 mg dose, applied among four main quadrants. Therefore, a spinal needle was inserted into an adapted tracheal tube. It was exposed for intramural application of the medication, after the introduction of the tracheal tube under the guidance of the endoscope vision. After the last rectal dilation was done, the patient was directed to chemotherapeutic treatment. Three chemotherapy sessions were done, on intervals of 21 days, using 300mg/m<sup>2</sup> doses of carboplatin, intravenously. After 958 days of post-surgical, the patient did not shown recurrences either of neither rectal stricture nor neoplasm (Figure 1F).



**Fig-1: A= Dorsolateral left portion of the rectum, presenting neoplasm formations (white arrows); irregular mucous membrane near to neoplasm formations (blue arrow). B= Polypectomy loop, englobing neoplasm formations to collect biopsy samples. C= endoscopically removed neoplasm formations. D= Aboral look of the neoplasm presented during the second colonoscopy. E= Severe rectal stricture, after extirpate the neoplasm. F= Rectal diameter after two dilatation sessions with intramural application of triamcinolone**

## DISCUSSION

The initial biopsy histological report revealed villous rectal polyps, with atypical focuses. The last histological evaluation performed after complete resection of the mass through transrectal access, showed the presence of rectal adenocarcinoma. This case agrees with the description that most polyps are either hyperplastics or adenomatous, wherein epithelial alterations do not cross to the muscular layer, however, some are atypical and considered *in situ* carcinomas [1].

The most common treatment for large intestine neoplasms is surgical resection, that it, excision through an abdominal incision, rectal pullthrough or appropriated perineal resection for serous or perirectal tissues invasive tumors [1]. In this case, the prioritized technique can be considered more efficient for neoplasms surgical resection through the least invasive access point (transluminal) in comparison with the remaining possibilities. However, considering the resections necessary extension, rectal stricture postsurgical occurred. We believed that the fundamental factor for the stricture formation was the

extension length of the tissue removed for reaching a neoplasm free margin, given that immediately after the opposition of the tissue edges there was a verification of intestinal diameter reduction that increased after cicatrization.

The balloons expansion exercises a radius vector upon the tissue, stretching and rupturing the collagen-rich tissue that comprises the stricture [4]. Due to lack of a specific balloon, it was opted for tracheal tube cuffs filled with NaCl 0.9% solution through video-guidance. The balloon's diameter, as well as the number of procedures needed for the lumens opening may vary, in which, the goal of performing several procedures during different days, gradually increases the stricture diameter, without excessive damage or inflammation, reducing restrictions possibility [4].

Triamcinolone is a corticoid that besides reducing inflammatory response, it interferes with the collagen synthesis, fibrosis and chronic cicatrization [7]. When combined with dilation via balloon, intralesional triamcinolone injections could has better

success rates than balloon dilation solely [4]. Intralésional application of triamcinolone could prevent the stricture contraction after its dilation, being that the dosage for dogs may vary between 20 to 40 mg, applied among four quadrants, one-fourth of the dose each [8]. In this case, association of 40 mg of triamcinolone applied intramurally, and balloon dilatation, into two sessions was performed, achieving treatment success for the stricture.

Therefore, it is concluded that the use of triamcinolone associated to an endoscopic balloon dilation was efficient on the treatment of this patient's rectal stricture.

## REFERENCES

1. Hedlund CS, Fossum TW. Surgery of the digestive system. In: Small Animal Surgery. 3th ed. (Fossum, T. W.), Elsevier, Philadelphia. 2008. Pp. 339-530.
2. Kumagai D, Shimada T, Yamate J, Ohashi F. Use of an incontinent end-on colostomy in a dog with annular rectal adenocarcinoma. J Small Anim Practice. 2003; 44 (8): 363-366.
3. Bravi I, Ravizza D, Fiori G, Tamayo D, Trovato C, Roberto G, Genco C, Crosta C. Endoscopic electrocautery dilation of benign anastomotic colonic strictures: a single-center experience. Surg Endosc. 2016; 30 (1): 229-232.
4. Chavkin JA, Spector DJ, Stanley SW. Balloon dilation and intralesional steroid for benign rectal stricture management in a cat. J Feline Med Surg. 2010; 12: 663-665.
5. Webb CB, McCord KW, Twedt DC. Rectal strictures in 19 dogs: 1997-2005. J Am Anim Hosp Assoc. 2007; 43 (6): 332-336.
6. Lee M, Kubic CM, Polhamus CD, Brady CE, Kadakia SC. Preliminary experience with endoscopic intralesional steroid injection therapy for refractory upper gastrointestinal strictures. Gastrointes Endosc. 1995; 41 (6): 598-601.
7. Broor SL, Raju GS, Bose PP, Lahoti D, Ramesh GN, Kumar A, Sood GK. Long term results of endoscopic dilatation for corrosive oesophageal strictures. Gut. 1993; 34: 1498-1501.
8. Corgozinho KB, Neves A, Belchior C, Toledo F, Souza HJM, Hora AS. Local triamcinolone in a cat with esophageal stricture. Acta Sci Vet. 2006; 34 (2): 175-178.