

## Effect of Platelet-Rich Fibrin on Soft Tissue, Periodontal Pocket Healing, and Alveolar Bone Height after Third Molar Surgery: A Randomized Clinical Trial

Lam Cu Phong<sup>1\*</sup>, Nguyen Thi Bao Ngoc<sup>1</sup>, Nguyen Thi Bich Ly<sup>2</sup>

<sup>1</sup>DDS, M.D., Lecturer, Department of Oral Surgery, Faculty of Odonto-Stomatology, University of Medicine and Pharmacy, Ho Chi Minh City, Viet Nam

<sup>2</sup>DDS, Ph.D., Department of Oral Surgery, Faculty of Odonto-Stomatology, University of Medicine and Pharmacy, Ho Chi Minh City, Viet Nam

DOI: [10.36347/sjds.2023.v10i07.001](https://doi.org/10.36347/sjds.2023.v10i07.001)

| Received: 07.06.2023 | Accepted: 11.07.2023 | Published: 17.07.2023

\*Corresponding author: Lam Cu Phong

DDS, M.D., Lecturer, Department of Oral Surgery, Faculty of Odonto-Stomatology, University of Medicine and Pharmacy, Ho Chi Minh City, Viet Nam

### Abstract

### Original Research Article

**Background:** More and more studies were being conducted to improve healing after third molar surgery. The aim of this study was to evaluate the effect of PRF on soft tissue and periodontal pocket healing, alveolar bone resorption distal to the second molar after lower third molar surgical removal. **Methods:** A Randomized, controlled clinical trial and split-mouth design was performed on 26 healthy patients who had an indication of impacted lower third molars extraction on both sides with symmetrical orientation and the same difficult index. All patients had the same extraction protocol on both sides at the Department of Oral Surgery, Faculty of Odonto-stomatology, University of Medicine and Pharmacy, Ho Chi Minh City. PRF was applied on one side, whereas the other was left empty as the control group. Assessing the soft tissue healing, periodontal pocket depth and distal bone resorption of the study and control groups after third molar removal surgery. Data obtained were statistically analyzed. **Results:** There is a statistically significant difference in soft tissue healing on the 3<sup>rd</sup> and 7<sup>th</sup> postoperative days and distal bone resorption ( $p < 0.05$ ) on the 3<sup>rd</sup> and 6<sup>th</sup> postoperative months between two groups. Periodontal pocket depth of the study group showed more reduction than the control group but was not significantly different. **Conclusion:** Using PRF can help improve soft tissue healing and lower distal bone resorption after surgical extraction of impacted lower third molars. PRF appears to reduce periodontal pocket depth but still needs more research to conclude.

**Keywords:** Distal bone resorption, periodontal pocket, platelet-rich fibrin, soft tissue healing, third molar surgery.

Copyright © 2023 The Author(s): This is an open-access article distributed under the terms of the Creative Commons Attribution 4.0 International License (CC BY-NC 4.0) which permits unrestricted use, distribution, and reproduction in any medium for non-commercial use provided the original author and source are credited.

## INTRODUCTION

Third molar removal surgery is one of the most common surgeries in dental practice. There are many reasons leading to the decision of third molar teeth extraction such as tooth decay, food impaction, infection, tumor, cystic lesion, or extraction according to the indication of orthodontics or prosthodontics. In cases of mesially or horizontally inclined lower third molars, it is easy to form a periodontal pocket distal to the adjacent second molar. Besides, the surgeon may have to remove the buccal bone to expose the teeth as well as create a fulcrum for elevation. This may exacerbate adjacent periodontal tissue defects. Thus, it is necessary to have more supportive treatments for distal periodontal tissue healing and reconstruction.

In recent years, the use of platelet concentrates to improve wound healing has become more and more widely used in the medical and dental fields. Platelet-rich fibrin (PRF) was first introduced by Choukron in 2001, with the growth factors or chemical mediators released gradually and continuously in the fibrin scaffold [1]. There have been many authors applying PRF to support healing after wisdom teeth extraction. PE Jeraya (2018) reported that PRF helps reduce postoperative complications such as swelling, pain, trismus, improves soft tissue healing and hard tissue regeneration [2]. Besides that, M Zahid (2018) suggested that there was no difference in periodontal pocket depth distal to the second molar between the PRF group and the control [3].

With the desire to find out and clarify a supportive treatment, we conducted a study to evaluate the effect of PRF on soft tissue healing on 3<sup>rd</sup> and 7<sup>th</sup> postoperative days; periodontal pocket depth distal to second molar at 1<sup>st</sup>, 3<sup>rd</sup> and 6<sup>th</sup> postoperative months, the alveolar bone height of distal to adjacent teeth at 3<sup>rd</sup> and 6<sup>th</sup> postoperative months between study and control group.

## MATERIALS AND METHODS

### Research Sample

The study was designed as a split-mouth randomized clinical trial on patients who had demand and indication for extraction of misaligned lower wisdom teeth to be examined and extracted at the Department of Oral Surgery, Faculty of Odonto-Stomatology, University of Medicine and Pharmacy, Ho Chi Minh City.

### Inclusion Criteria

- Patients over 18 years old.
- Good general health.
- Bilateral lower third molars equivalent in inclination and Pell and Gregory's impaction classification (classification II, III and B, C). The assessment of equivalence between two mandibular third molars was determined on the panoramic radiograph.
- The difference in third molar inclination on both sides is not greater than 15 degrees.
- The patient consented to participate in the study after hearing the explanation of the purposes and requirements of the study.

### Exclusion Criteria

- Patients with any systemic disease are contraindicated for surgery.
- Presence of acute inflammation or infection at third molar areas.

- Patients refused to participate in the study, did not comply with treatment, or did not come to the follow-up examination as required.
- The difference in surgical time between the two groups was more than 10 minutes.

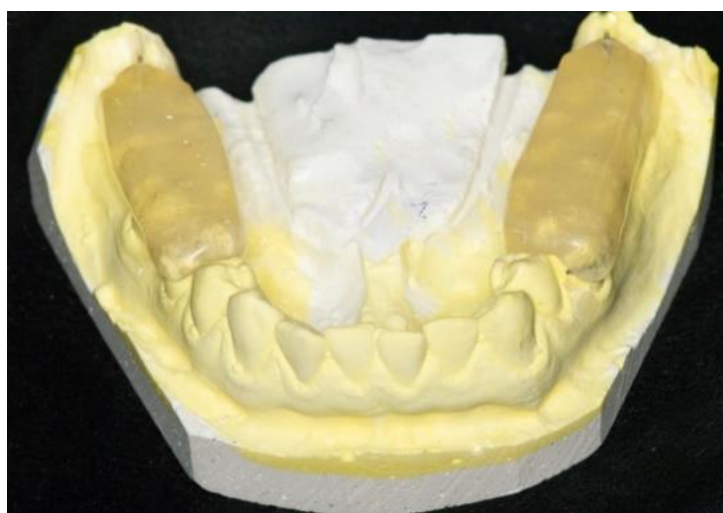The study was approved by the Research Ethical Committee in Biomedical Research of the University of Medicine and Pharmacy in Ho Chi Minh City, licensed code 414/DHYD-HDĐĐ on August 21st, 2019.

### Patient Preparation

26 patients (17 females and 9 males), who met the inclusion criteria were selected to participate in this study. Preoperatively, patients were fully informed about the purposes of this study, surgical procedure, the requirement for information, and follow-up examination and signed the consent form to participate in the study.

The patients were drawn to determine the study side (with PRF), and the other would be the control side (without PRF). The second third molar surgery would be conducted 1 month after the first surgical appointment.

Mandibular impressions were taken to make occlusal stents to ensure consistency of positions between measurements. Each stent was 2mm thick covering the occlusal surfaces from the second premolar to the second molar. At the distal surface of the second molar, the stent was extended 4mm apically from occlusal surfaces. During polymerization, grooves were made on the distal buccal and distal lingual of the stent at the second molar position. Consequently, distal buccal and lingual grooves were 6mm in length. A 5mm metal wire was also inserted into the distal surface of the stent to assess alveolar bone height evaluation according to the proportion on periapical radiographs (Figure 1).



**Figure 1: Occlusal stent with mandibular impression**

### Surgical Procedure

Patients had their third molars extracted by the same experienced surgeon following standardized procedures at the Department of Oral Surgery, University of Medicine and Pharmacy, Ho Chi Minh City on both sides with the same surgical approach. After the removal of the lower third molar and socket curettage, the extraction sockets on the study side were filled with PRF clot, whereas the other side sockets were left empty and underwent natural healing. The third molar sockets on both sides were sutured as primary healing with 3-0 silk sutures.

The surgical duration was counted from flap incision to complete socket closure. If the difference in surgical duration on both sides was greater than 10 minutes, the patient was excluded from the study.

### PRF Preparation

20ml blood samples of patients were taken into two 10ml glass-coated tubes. Blood centrifugations were performed with A-PRF+ mode (1300rpm within 8 minutes) of the Dou Quattro PRF system (Process for PRF, Nice, France) (Figure 2). After centrifugation, the PRF clots were dissected from the red blood cells (Figure 3).



Figure 2: Dou Quattro PRF system (Process for PRF, Nice, France)

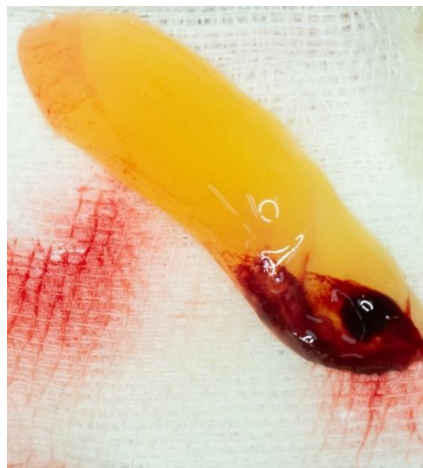

Figure 3: A-PRF+ clot after preparation and dissection

### Postoperative Care

Each patient was given the same medications which were prepared by the research team to ensure homogeneity. The prescription was:

- Amoxicillin 500mg thrice daily, 5 days.
- Ibuprofen 400 mg thrice daily, 3 days.
- Acetaminophen 500mg thrice daily, 3 days.

### Research Outcome Evaluation

The outcome assessor was blind to clinical measurements.

### Soft Tissue Healing

Soft tissue around wisdom teeth was assessed according to Landry's (1998) healing index on the 3<sup>rd</sup> and 7<sup>th</sup> postoperative days [4]. This scale consists of 5 scores from 1 corresponding to very poor healing to 5

corresponding to excellent healing. Each score will have specific evaluation criteria (Table I).

**Table I: Healing Index by Landry (1998)**

Very poor	Tissue color: $\geq 50\%$ gingiva red Response to palpation: bleeding Granulation tissue: present Suppuration: present
Poor	Tissue color: $\geq 50\%$ gingiva red Response to palpation: bleeding Granulation tissue: present Suppuration: none
Good	Tissue color: $\geq 25\%$ but $< 50\%$ gingiva red Response to palpation: no bleeding Granulation tissue: none Suppuration: none
Very good	Tissue color: $< 25\%$ gingiva red Response to palpation: no bleeding Granulation tissue: none Suppuration: none
Excellent	Tissue color: All tissue is pink and healthy Response to palpation: no bleeding Granulation tissue: none Suppuration: none

#### Periodontal Pocket Depth

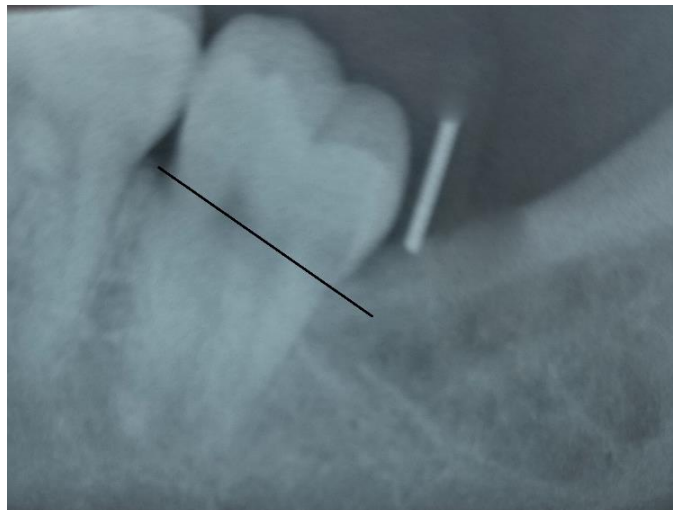
Periodontal pocket depth was measured at the distal buccal (DB) and distal lingual (DL) positions of the second molar before surgery (T0) and at the 1<sup>st</sup>, 3<sup>rd</sup>, and 6<sup>th</sup> postoperative months (T1, T3, T6). All probing measurements were obtained by UNC-15 periodontal probe (Hu-Friedy, USA) from the gingival margin to the bottom of the pocket. To ensure the probing positions were the same, the periodontal probe was maintained in the groove. The periodontal pocket reduction was determined by differences between each assessment time before surgery pocket depth.

#### Distal Bone Resorption

Periapical radiographs were taken to measure the distance between CEJ to distal bone of the second molar (L) with the guide of the stent at the time immediately after surgery and 3<sup>rd</sup>, 6<sup>th</sup> (T3, T6) postoperative months (Figure 4).

$$L = \frac{5 \times \text{CEJ to bone height}}{\text{length of a metal wire on the radiograph}}$$

Distal bone resorption was determined as differences in (L) between the time right after surgery and each assessment time.



**Figure 4: Periapical radiograph to assess the distal bone resorption**

#### Statistically Analysis

The statistical data were analyzed by SPSS software 22. Soft tissue healing was evaluated with a Wilcoxon test. Distal bone resorption follows a normal

distribution, so we used the paired T-test to compare the difference between the two groups. Since periodontal pocket depth is not a normality distribution, Mann-Whitney non-parametric test was performed to compare

the differences between two groups. The results were statistically significant when *p*-values were less than 0.05.

**RESULT**

**Sample Characteristics**

26 patients participated in our study ranging from 19 to 27 years old, with a mean age of 23.346 ± 3.298 years old. 9 patients were male (34.615%) and 17 patients were female (65.385%). There were no surgical complications and none were excluded postoperatively. In 8 of 26 cases (30.769%), third molars were IIB according to Pell-Gregory’s impaction classification and the others were IIIB (69.231%) (Table II).

**Table II: Sample distribution**

Gender	Study sample	
	Male	9 (34.615%)
Female	17 (65.385%)	
Age	23.346 ± 3.298	
Pell-Gregory classification	IIB	8 (30.769%)
	IIIB	18 (69.231%)

**Soft Tissue Healing**

On the 3<sup>rd</sup> postoperative day, soft tissue healing in the study group was mostly “excellent” (17 cases), while in the control group was “good” and “very good” (both 11 cases). On the 7<sup>th</sup> postoperative day, the study group had 22 cases with “excellent” healing, only 4 cases remained with "very good" healing while the

control group still had a few cases remaining with "good" healing (3 cases). In general, at both assessment times, the soft tissue healing of the study group was better than that of the control group, the difference was statistically significant (Table III). The most significant clinical sign of the study group was tissue color, which was healthy pink and similar to surrounding soft tissue.

**Table III: Soft tissue healing**

		HI index (case, %)					<i>p</i>
		1	2	3	4	5	
3 <sup>rd</sup> day	Study	0(0%)	0(0%)	3(11,538%)	6(23,077%)	17(65,385%)	0,001*
	Control	0(0%)	0(0%)	11(42,308%)	11(42,308%)	4(17,384%)	
7 <sup>th</sup> day	Study	0(0%)	0(0%)	0(0%)	4(17,384%)	22(84,616%)	0,014*
	Control	0(0%)	0(0%)	3(11,538%)	7(26,922%)	16(61,540%)	

\*: statistically different

**Periodontal Pocket Depth**

At T1, the reduction of pocket depth in the study group was greater than in the control group at both DB and DL sites, but this difference was not statistically significant. At T3 and T6, the mean pocket depth continued to decrease in both DB and DL sites but the difference was also not statistically significant.

We also noted that the difference in periodontal pocket depth reduction between T1-T3 and T3-T6 was no statistical significance. The greatest decrease in pocket depth was between T0 and T1. After that, the pocket depth continued to change, but not much (Table IV, Table V).

**Table IV: Mean periodontal pocket depth at T0, T1, T3, T6**

	DB (mm)				DL (mm)			
	T0	T1	T3	T6	T0	T1	T3	T6
Study	3.115 ± 1.633	2.615 ± 1.329	2.500 ± 0.860	2.231 ± 0.815	3.308 ± 1.379	2.500 ± 0.812	2.308 ± 0.8317	2.154 ± 0.784
Control	3.385 ± 1.856	3.115 ± 1.532	2.846 ± 1.255	2.577 ± 1.206	3.308 ± 1.320	2.923 ± 0.977	2.615 ± 0.941	2.500 ± 0.990
<i>p</i>		0.350	0.724	0.900		0.288	0.384	0.320

**Table V: Periodontal pocket depth reduction at T1, T3, T6**

	DB (mm)			DL (mm)		
	T1	T3	T6	T1	T3	T6
Study	0.769± 0.951	0.923± 1.017	1.115± 1.211	1.115± 1.177	1.231± 1.210	1.346± 1.130
Control	0.539± 0.859	0.808± 0.939	1.039± 1.113	0.731± 0.827	0.923± 1.017	1.039± 1.039
<i>p1</i>	0.350	0.724	0.900	0.288	0.384	0.320
<i>p2</i>	0.253			0.446		

<i>p</i> 2	0.794	0.134
------------	-------	-------

At both T3 and T6 evaluations, we noted that the resorption of distal alveolar bone of the study group was less than that of the control group this difference was statistically significant (Table VI).

### Distal Bone Resorption

**Table VI: Distal bone resorption at T3, T6**

	Distal bone resorption (mm)			
	T3	<i>p</i>	T6	<i>p</i>
Study	0.393 ± 0.163	0.002*	0.705 ± 0.217	0.001*
Control	0.546 ± 0.209		0.880 ± 0.238	

\*: statistically different

## DISCUSSION

Our study is a randomized controlled clinical trial with a split-mouth design to evaluate the effect of PRF on soft tissue and periodontal tissue healing. To control bias, the lower third molars of each participant on both sides had similar difficulty, impaction classification, and symmetrical orientation on panoramic radiograph. Third molar extraction on both sides was performed by the same surgeon of the Department of Oral Surgery, Faculty of Odonto-Stomatology, University of Medicine and Pharmacy, Ho Chi Minh City. We excluded cases if the surgical duration on the study side and control side were different by more than 10 minutes. In addition, clinical measurements are taken by an independent measurer (the outcome assessor was blind).

Soft tissue healing was assessed on the 3<sup>rd</sup> and 7<sup>th</sup> postoperative days. We found that the soft tissue healing score of the study group was higher than the control group at both assessment times. This effect was probably because PRF was a continuous and effective source of growth factors, including growth factors such as TGF- $\beta$ 1 that played a role in tissue repair, extracellular matrix synthesis, differentiation, PDGF in cell migration and proliferation, FGF in fibroblast growth, VEGF in angiogenesis, provides a source of nutrients as well as oxygen for soft tissue healing. In addition, the white blood cells in A-PRF+ such as neutrophils, lymphocytes, and eosinophils all play an important role in the immune regulation of the healing process. This finding was similar to Daugela (2018) [5].

As mentioned above, the periodontal pocket depth reduction of the study group was higher than the control group but not significantly different, despite higher soft tissue healing scores. This finding could be affected by patients' age according to a systematic review and meta-analysis by Soo-Hoong Low [6]. The participants were mainly young patients with an average age of 23.346. Consequentially, the healing ability of young patients gives a hand to the periodontal pocket reduction potential, which made the healing supportive effect of PRF unclear. The results of periodontal pocket depth reduction in our study were

similar to Zahid (2019) [3]. When compared to preoperative pocket depth, Zahid found that there was a significant improvement in pocket depth in both groups. However, when comparing two groups, although the mean pocket depth of the study group was lower than the control group, this difference was not statistically significant at T1, T3, and T6 at both sites. The study of Passareli (2020) also gave similar results on the healing effect of periodontal pockets [7]. When looking at the reduction in pocket depth between evaluation times, it could be seen that the change in pocket depth occurred mainly 1 month after surgery. This is also consistent with periodontal tissue healing. According to Proye (1982), the healing process of periodontal pockets occurs mainly in the first 3 weeks [8]. The healing effect of PRF on the periodontal pocket distal to the second molar after mandibular third molar extraction is controversial and perhaps more studies are needed to confirm the actual effect of PRF.

Lack of physical stimulation and blood supply from the periodontal ligament may lead to physiological bone loss after tooth extraction. The effect of PRF on distal bone resorption of our finding was similar to Bagoury (2015) [9], and Temmerman (2016) [10]. This result could be because growth factors within PRF help improve angiogenesis and blood supply in extraction sockets and reduce bone resorption. Furthermore, PRF also acted as a scaffold attracting cell proliferation and differentiation, which may help in bone regeneration. However, the effect of PRF on bony tissue was still debated.

## CONCLUSION

From the study results, we found that PRF was effective in improve soft tissue healing and reduce distal bone resorption of second molar after third molar extraction. In addition, PRF may help reduce periodontal pocket depth faster but not significantly.

### Limitation

Larger sample sizes may reveal more variable changes in each group to have an accurate conclusion for the effect of platelet-rich fibrin especially on periodontal pocket depth.

**CONFLICT OF INTEREST**

The authors have no conflicts of interest relevant to this article.

**External Funding:** None

**REFERENCES**

1. Naik, B., Karunakar, P., Jayadev, M., & Marshal, V. R. (2013). Role of Platelet rich fibrin in wound healing: A critical review. *Journal of conservative dentistry: JCD*, 16(4), 284.
2. Jeyaraj, P. E., & Chakranarayan, A. (2018). Soft tissue healing and bony regeneration of impacted mandibular third molar extraction sockets, following postoperative incorporation of platelet-rich fibrin. *Annals of maxillofacial surgery*, 8(1), 10.
3. Zahid, T. M., & Nadershah, M. (2019). Effect of advanced platelet-rich fibrin on wound healing after third molar extraction: a split-mouth randomized double-blind study. *J Contemp Dent Pract*, 20(10), 1164-70.
4. Sharma, A., Ingole, S., Deshpande, M., Ranadive, P., Sharma, S., Kazi, N., & Rajurkar, S. (2020). Influence of platelet-rich fibrin on wound healing and bone regeneration after tooth extraction: A clinical and radiographic study. *Journal of oral biology and craniofacial research*, 10(4), 385-390.
5. Daugela, P., Grimuta, V., Sakavicius, D., Jonaitis, J., & Juodzbalsys, G. (2018). Influence of leukocyte-and platelet-rich fibrin (L-PRF) on the outcomes of impacted mandibular third molar removal surgery: A split-mouth randomized clinical trial. *Quintessence International*, 49(5).
6. Low, S. H., Lu, S. L., & Lu, H. K. (2021). Evidence-based clinical decision making for the management of patients with periodontal osseous defect after impacted third molar extraction: a systematic review and meta-analysis. *Journal of dental sciences*, 16(1), 71-84.
7. Passarelli, P. C., Romeo, A., Lopez, M. A., De Angelis, P., Desantis, V., Piccirillo, G. B., ... & D'Addona, A. (2020). Evaluation of the periodontal healing of the second mandibular molar distal site following insertion of PRF in the third molar post extraction alveolus. *Journal of Biological Regulators and Homeostatic Agents*, 34(5 Suppl. 3), 111-118.
8. Proye, M., Caton, J., & Polson, A. (1982). Initial healing of periodontal pockets after a single episode of root planing monitored by controlled probing forces. *Journal of Periodontology*, 53(5), 296-301.
9. El Bagoury, E. Z. F., Hassan, M., & Thabet, H. H. (2015). Evaluation of platelet-rich fibrin on alveolar bone height after removal of impacted lower third molar. *Egyptian Journal of Oral & Maxillofacial Surgery*, 6(2), 50-54.
10. Temmerman, A., Vandessel, J., Castro, A., Jacobs, R., Teughels, W., Pinto, N., & Quirynen, M. (2016). The use of leucocyte and platelet-rich fibrin in socket management and ridge preservation: a split-mouth, randomized, controlled clinical trial. *Journal of clinical periodontology*, 43(11), 990-999.