

Original Research Article

Maxillary Sinus, Frontal Sinus and Nasal Septum Patterns in Personal Identification in Forensics Using CBCT- A Retrospective Study

Dr. Saraswathi Gopal¹, Dr. Alana Paul²

¹Head of the Dept., Dept. of oral medicine and radiology, Meenakshi Ammal dental College, Chennai-95

²Dept of Oral Medicine and Radiology, Meenakshi Ammal dental College, Chennai-95

*Corresponding author

Dr. Alana Paul

Email: alnap70@gmail.com

Abstract: This study is aimed at assessing the reliability of morphometric measurements performed on the frontal sinus, nasal septum and maxillary sinus in personal identification using three dimensional Cone Beam Computed Tomography. This study propounds the significance of combined use of all three particularly maxillary sinus and nasal septum pattern in individual identification. This retrospective study includes 100 CBCT volumes with 200 sides of images (left and right) acquired using PLANMECA MID PROMAX 3D machine using Romexis software. CBCT images obtained from department of Oral medicine and radiology Meenakshi Ammal Dental College, Chennai, India. Volume of maxillary sinus is measured using geometric equation. The frontal sinus is classified as symmetry, asymmetry, unilateral or bilateral aplasia. The nasal septum is classified based on the deviations in the septa as straight, deviation to right or left, sigmoid type and reverse sigmoid type. The overall value of maxillary sinus decreased with progressing age and greatest volume of maxillary sinus was observed with reverse sigmoid nasal septum pattern. Frontal sinus symmetry was observed in 50 % of the individuals and asymmetry in 50% of the individuals. Unilateral and bilateral aplasia was not observed in this study. Straight nasal septum was seen in 50% of the individuals, right deviation in 11% of individuals, and left deviation in 12% of the individuals. Sigmoid was seen in 4% and reverse sigmoid in 3% of the individuals. To conclude, the combined use of values obtained from frontal sinus, maxillary sinus and nasal septum patterns can be used in personal identification.

Keywords: Cone beam CT, Maxillary sinus, Frontal sinus, Nasal septum, Forensics, Personal identification

INTRODUCTION

The study of anthropometry is of fundamental importance in personal identification and plays a vital role in medico legal investigation of death. Use of features unique to each human being helps in personal identification and is widely accepted in forensics. On comparing the ante-mortem reports recorded during life time and post-mortem records, a forensic odontologist can identify the age at time of death, race and even sex [1] by study of the skull's osteological features. Personal identification can be done using various body parts, the skull, the pelvis, the long bones, the foramen magnum and the paranasal sinuses [2]. In mass disasters like natural calamities, criminal investigations, aircraft crashes and in situation where visual identification is difficult, maxillary sinuses and frontal sinus can be used as a parameter because of their diversity and resistance to external changes [1].

During fetal development, the paranasal sinuses originate as invagination of the nasal mucosa into the lateral nasal wall, frontal, ethmoid, maxilla and

the sphenoid bones thereby explaining the anatomical variability of these structures [3]. Identification by dental means began in 66A.D where a victim was recognized by tooth. Modern forensic began in 1897, where a general dentist identified a disaster victim in Paris [1]. Matching specific features detected on the dead bodies with data recorded during the life of an individual (radiographs, study casts) is an important aspect in forensics. CBCT is a recently developed CT technology that is used primarily in maxillofacial applications that generates 3-D images at a lower cost and absorbed dose compared to CT. CBCT may also be very useful in forensic contexts, offering several advantages for postmortem forensic imaging. Previous studies were done with frontal sinus and nasal septum pattern for personal identification and maxillary sinus in gender determination. The present study was designed to determine the reliability and accuracy of maxillary sinus, frontal sinus and nasal septum as a technique for personal identification using morphometric analysis using CBCT.

MATERIALS AND METHOD

100 CBCT scans (65males and 35 females) of bilateral maxillary sinuses, 200 frontal sinuses and 100 nasal septum images were retrospectively retrieved from the database of Oral Medicine and Radiology. Based on the age, the study consisted of 3 Groups .Group -I consist of 39 images obtained from age ranges from 21 to 30years, Group -II consisted of 48 images obtained from age range of 31 to 40years and Group III consisted of 13 images ranges from 41 to 50years. The linear measurements of Maxillary sinus with height, width and depth were performed. The width and depth

were measured in axial section and height was measured in coronal section. The width was defined as the longest distance perpendicular from the medial wall of the sinus to the most lateral wall of the maxillary sinus in the axial view ⁴. The depth was defined as the longest distance from the most anterior point to the most posterior point of the medial wall in the axial view. The height was measured away from the inner surface of the anterior border of maxillary sinus and was defined as the longest distance from the lowest point of the sinus floor to the highest point of the sinus roof in the coronal view [4] (Figure A,B,C).

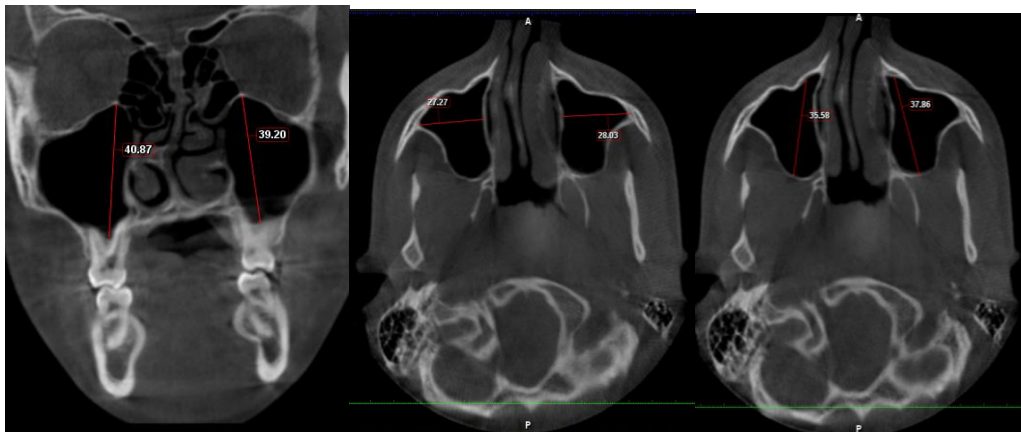
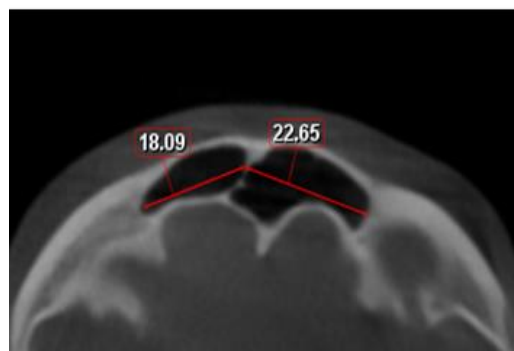


Fig A) Height in coronal view B) width in axial view C) length in axial view

Volume of maxillary sinus was determined using geometric calculation method according to geometrical equation: Volume of Pyramid = Base surface area x 1/3 Height [5].

Frontal sinus was observed and classified as symmetry and right or left dominant asymmetry. The

greatest horizontal dimension was measured from the central septum on either side (Fig D). The difference in the right and left side dimensions was divided by the greatest dimension and multiplied by 100. If the percentage was more than 20% then it was classified as asymmetrical[6].



Measurement of frontal sinus (Fig D)

The **Nasal septum** was classified according to the deviations in the septa as simple deviation to right or left, sigmoid type, reverse sigmoid type and straight

(Fig E) .The combined maxillary sinus, frontal sinus and nasal septum pattern was recorded for each individual.

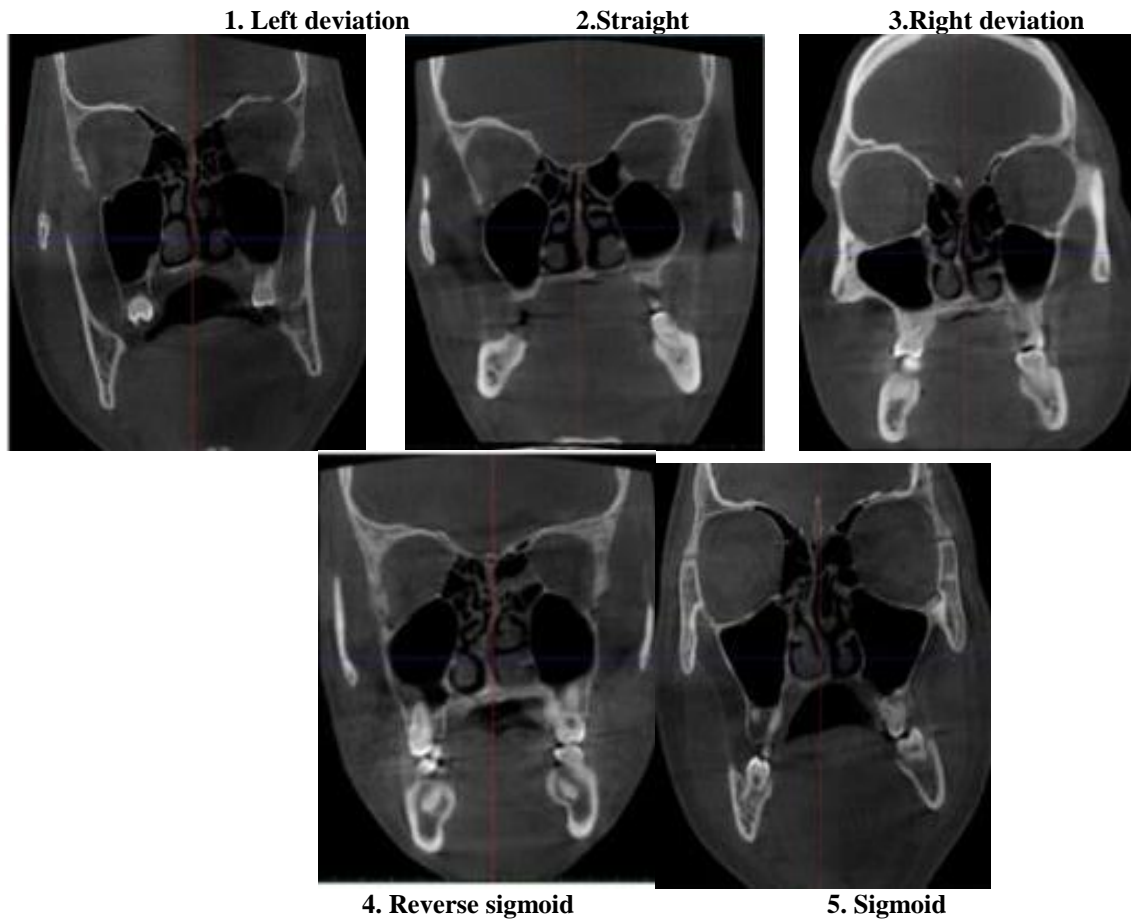


Fig E: Various patterns of Nasal septum (1, 2, 3, 4, 5)

This retrospective study consists of 100 CBCT images. In this study we have evaluated the linear measurements of maxillary sinus and frontal sinuses. We also evaluated the patterns of nasal septum. All this data were tabulated and statistically analysed (n=100) Group I (n= 39) Group II (n=48) and Group III (n=13) by using

- Sample t test
- Chi square test
- Pearson Correlation test.

RESULTS

FRONTAL SINUS

The frontal sinus was classified as symmetrical, asymmetrical (right or left), unilateral aplasia (right or left) and bilateral aplasia. The formula used for calculation of symmetry is the greatest dimension horizontally was measured from the central

septum on both sides. The difference between the right and left side dimensions were divided by the greatest dimension and then multiplied by 100. In this study, incidentally we have obtained images of patients who have only symmetry or asymmetry, since the incidence of unilateral aplasia and bilateral aplasia is less and was also not observed in our study.

The frontal sinus has maximum symmetry in male patient age ranges between 21 to 30 and least in female age ranges 41 to 50 which is statistically significant, P<0.5 (Table -1 Graph – 1). The frontal sinus has maximum asymmetry in male patient age ranges between 31 to 40 and least in female age ranges 41 to 50 which are statistically significant. P<0.5 (Table -2 and Graph – 2).

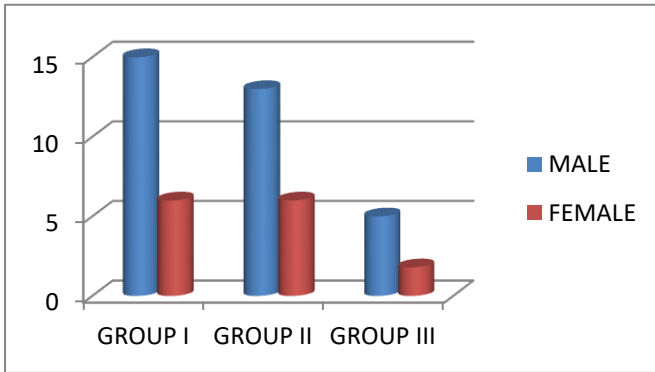
FRONTAL SINUS SYMMETRY

Table 1: Asymmetry

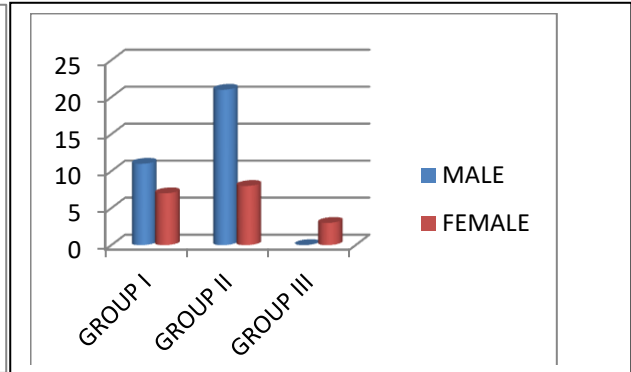
| | MALE | FEMALE | TOTAL | P<0.5 |
|-----------|------|--------|-------|-------|
| GROUP I | 15 | 6 | 21 | |
| GROUP II | 13 | 6 | 19 | |
| GROUP III | 5 | 5 | 10 | |
| TOTAL | 33 | 17 | 50 | |

Table 2

| | MALE | FEMALE | TOTAL | P<0.5 |
|-----------|------|--------|-------|-------|
| GROUP I | 11 | 7 | 18 | |
| GROUP II | 21 | 8 | 29 | |
| GROUP III | 0 | 3 | 3 | |
| TOTAL | 32 | 18 | 50 | |



Graph-1



Graph - 2

Table 2 and Graph -2 inference: The frontal sinus has maximum asymmetry in male patient age ranges between 31 to 40 and least in male age ranges 41 to 50 which is statistically significant P<0.5

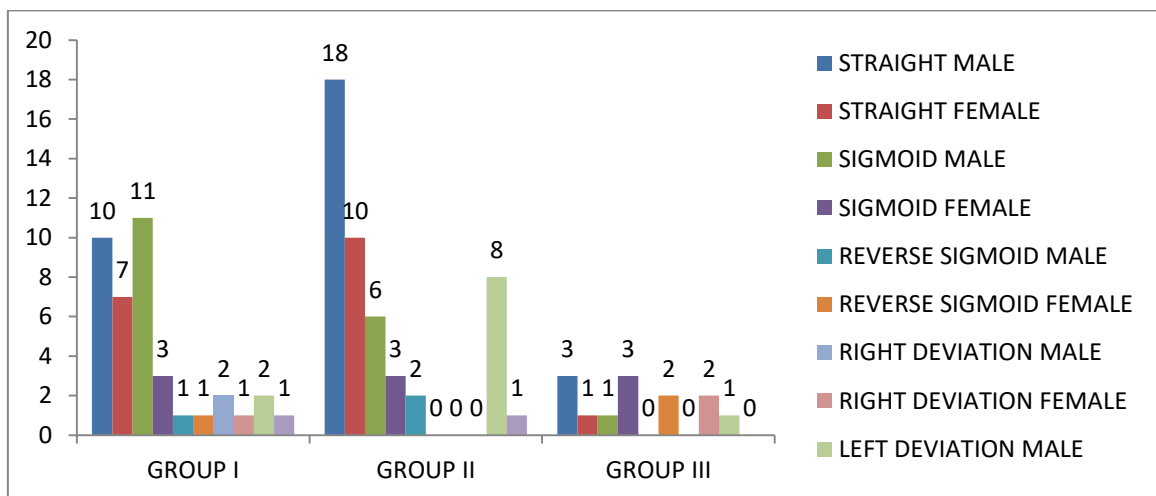
left deviation. Most images obtained in Group I and Group II has straight, whereas in Group III straight and sigmoid are equal in number. Male have more straight nasal septum in Group III, II and sigmoid in Group I. Female have more straight nasal septum in Group I, II and in sigmoid in Group III (Table- 3 and Graph- 3).

NASAL SEPTUM PATTERNS

The nasal septum pattern was evaluated as straight, sigmoid, reverse sigmoid, right deviation and

Table-3

| | STRAIG HT | SIGMOID | REVERSE SIGMOID | RIGHT DEVIATION | LEFT DEVIATION | P<0.5 |
|-----------|-----------|---------|-----------------|-----------------|----------------|-------|
| GROUP I | 17 | 14 | 2 | 3 | 3 | |
| GROUP II | 28 | 9 | 2 | - | 9 | |
| GROUP III | 4 | 4 | 2 | 2 | 1 | |



Graph- 3

Table- 3 and Graph- 3 inference: The nasal septum patterns compared between groups reveals maximum images obtained were straight which is statistically significant $P < 0.5$

MAXILLARY SINUS

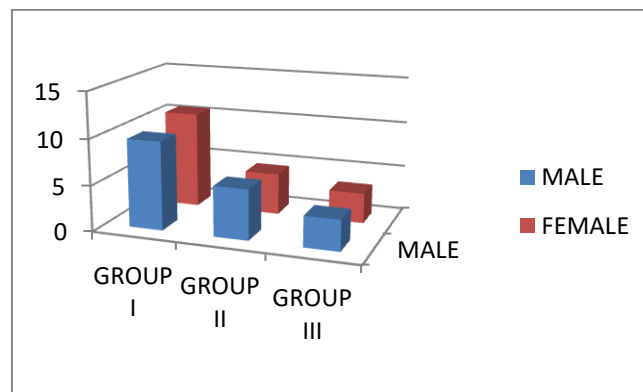
Volume of Maxillary Sinus

The volume of maxillary sinus is calculated by geometric calculation method according to the

geometrical equation: Volume of Pyramid = Base Surface Area X 1/3 Height. The volume of maxillary sinus decreases with increase in the age. The volume of maxillary sinus decrease with a correlation coefficient of -0.93%. The volume of maxillary sinus between the Groups are highly significant $P < 0.01$ (Table - 4 and Graph- 4).

Table – 4

| MEAN MAXILLARY SINUS VOLUME | MALES | FEMALES | P<0.5 |
|-----------------------------|-------|---------|-------|
| GROUP I | 9.64 | 10.59 | |
| GROUP II | 5.48 | 4.55 | |
| GROUP III | 3.34 | 3.30 | |



Graph - 4

Table -4 & Graph- 4 inference: The volume of maxillary sinus between the Groups is highly significant. $P < 0.01$.

MULTIPLE COMPARISONS

Frontal Sinus with Nasal Septum

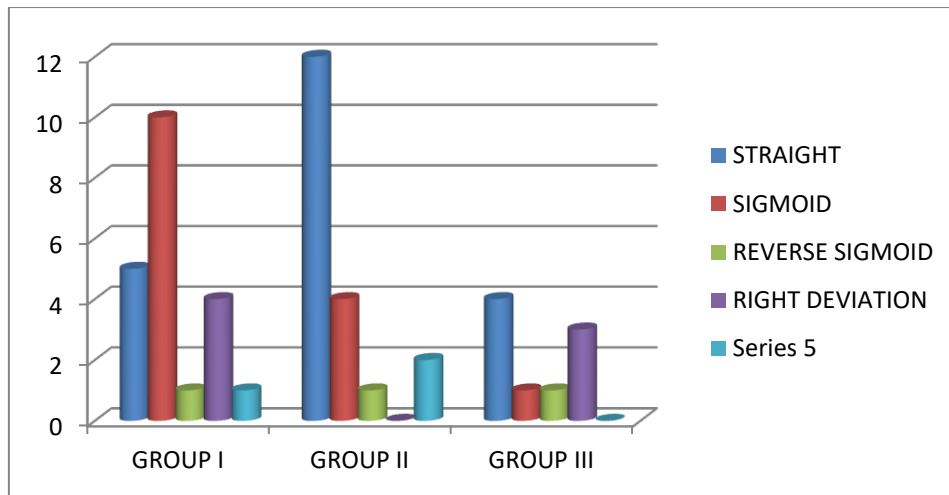
On comparing the nasal septum pattern with the frontal sinus symmetry the maximum number of

images obtained was having a straight nasal septum in Group II with age ranges from 31 to 40 which was statistically significant. $P < 0.01$. Equal number of reverse sigmoid pattern were observed in all the three Groups. In Group III reverse sigmoid and sigmoid pattern were equal in number (Table- 5 and Graph- 5).

If Frontal Sinus Was Symmetry

Table-5

| | STRAIGHT | SIGMOID | REVERSE SIGMOID | RIGHT DEVIATION | LEFT DEVIATION | *P<0.01 |
|-----------|----------|---------|-----------------|-----------------|----------------|---------|
| GROUP I | 5 | 10 | 1 | 4 | 1 | |
| GROUP II | 12 | 4 | 1 | 0 | 2 | |
| GROUP III | 4 | 1 | 1 | 3 | 0 | |



Graph-5

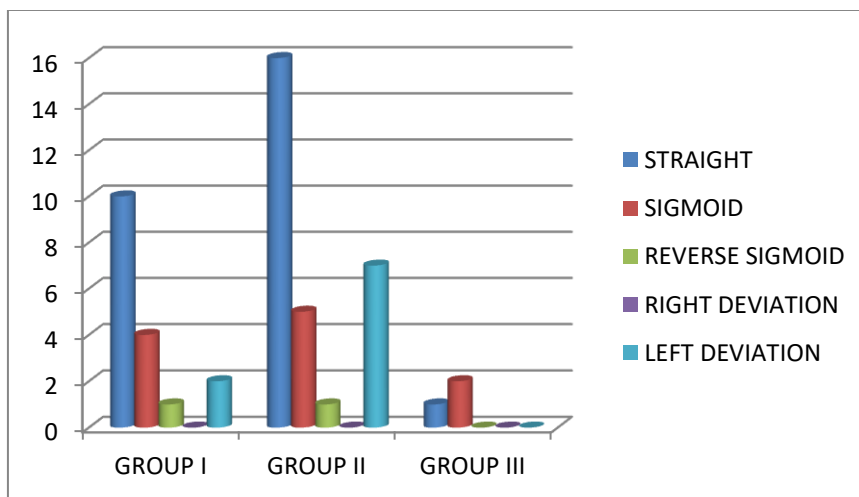
Table- 5 & Graph -5 inference: On comparing the nasal septum pattern with the frontal sinus symmetry the maximum number of images obtained was having a straight nasal septum in Group II with age ranges from 31 to 40 which was statistically significant $P < 0.01$

On comparing the nasal septum pattern with the frontal sinus asymmetry the maximum number of images obtained was having a straight nasal septum in Group II with age ranges from 31 to 40 which was statistically significant $P < 0.01$. The comparison of nasal septum patterns with the frontal sinus shows even more significant when evaluated separately. Hence the combination of frontal sinus and nasal septum is more significant (Table -6 and Graph- 6)

IF FRONTAL SINUS WAS ASYMMETRY

Table – 6

| | STRAIGHT | SIGMOID | REVERSE SIGMOID | RIGHT DEVIATION | LEFT DEVIATION | P<0.01 |
|-----------|----------|---------|-----------------|-----------------|----------------|--------|
| GROUP I | 10 | 4 | 1 | 0 | 2 | |
| GROUP II | 16 | 5 | 1 | 0 | 7 | |
| GROUP III | 1 | 2 | 0 | 0 | 0 | |



Graph – 6

Table- 6 & graph- 6 inference: On comparing the nasal septum pattern with the frontal sinus asymmetry the maximum number of images obtained was having a straight nasal septum in Group II with age ranges from 31 to 40 which was statistically significant $P < 0.01$.

MAXILLARY SINUS WITH FRONTAL SINUS

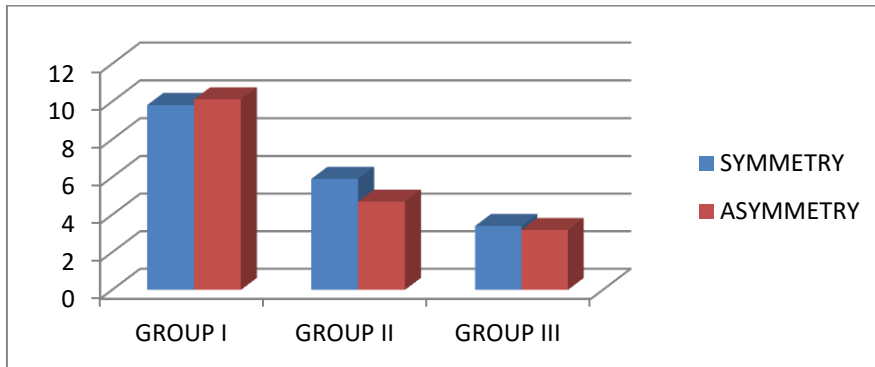
On comparing the maxillary sinus volume with the frontal sinus there was no volumetric changes in relation to the frontal sinus hence the data was not significant $P > 0.5$.

The maxillary sinus volume was compared with the frontal sinus and was found to be not significant since there was no marked changes in the volume of maxillary sinus with variations in the frontal

sinus, since they both are individual anatomical structures in personal identification, cannot be compared together in personal identification. (Table- 7 and Graph- 7)

Table 7

| MEAN VOLUME OF MAXILLARY SINUS | FRONTAL SINUS SYMMETRY | FRONTAL SINUS ASYMMETRY | P>0.5 |
|--------------------------------|------------------------|-------------------------|-------|
| GROUP I | 9.82 | 10.12 | |
| GROUP II | 5.91 | 4.70 | |
| GROUP III | 3.40 | 3.19 | |



Graph -7

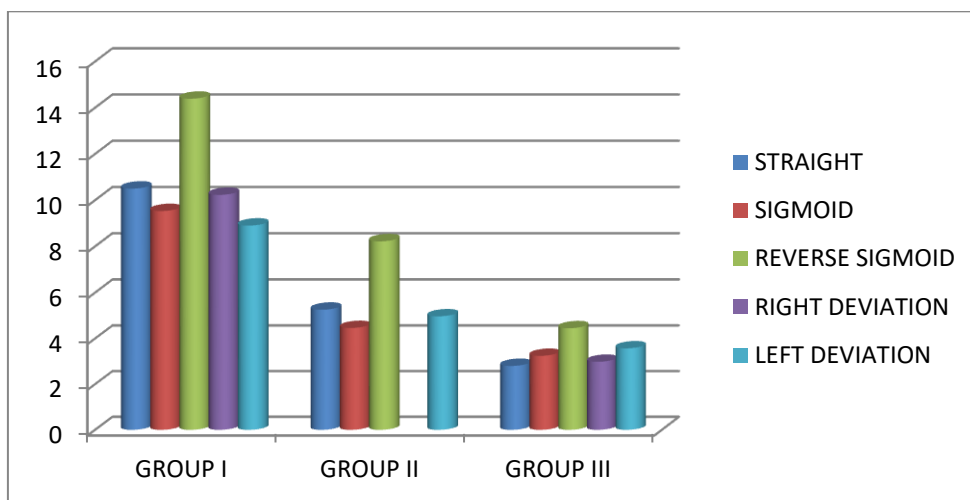
Table- 7 & Graph -7 inference: On comparing the maxillary sinus volume with the frontal sinus there was no volumetric changes in relation to the frontal sinus hence the data was not significant P>0.5.

On comparing the maxillary sinus volume with the nasal septum pattern there was significant changes in the reverse sigmoid pattern in all the groups which implies nasal septum pattern aids in the volumetric changes of the maxillary sinus. Reverse sigmoid pattern was observed with increasing maxillary sinus volume in all the Groups (Table- 8 and Graph- 8).

MAXILLARY SINUS WITH NASAL SEPTUM PATTERNS

Table-8

| | STRAIGHT | SIGMOID | REVERSE SIGMOID | RIGHT DEVIATION | LEFT DEVIATION | P<0.01 |
|-----------|----------|---------|-----------------|-----------------|----------------|--------|
| GROUP I | 10.50 | 9.53 | 14.39 | 10.23 | 8.9 | |
| GROUP II | 5.26 | 4.46 | 8.22 | | 4.97 | |
| GROUP III | 2.80 | 3.24 | 4.45 | 2.98 | 3.57 | |



Graph -8

Table- 8 & Graph- 8 inference: On comparing the maxillary sinus volume with the nasal septum patterns there were volumetric changes evident with reverse sigmoid pattern which is significant in all Groups $P < 0.01$.

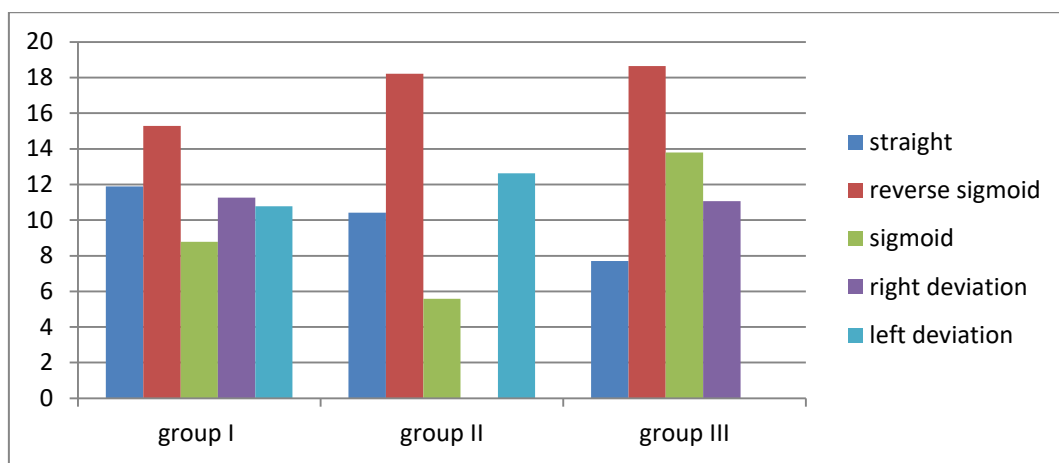
COMPARING MAXILLARY SINUS, FRONTAL SINUS AND NASAL SEPTUM PATTERNS

When Frontal sinus is symmetry

On comparing symmetrical frontal sinus with mean maxillary sinus volume and nasal septum there were no left deviation in Group III, no right deviation was observed in Group II and greatest maxillary sinus volume was observed with reverse sigmoid pattern. $p > 0.5$ was not significant (Table- 9 and Graph -9).

Table-9

| MEAN MAXILLARY SINUS VOLUME | STRAIGHT | REVERSE SIGMOID | SIGMOID | RIGHT DEVIATION | LEFT DEVIATION | P>0.5 |
|-----------------------------|----------|-----------------|---------|-----------------|----------------|-----------------|
| GROUP I | 11.89 | 15.29 | 8.79 | 11.26 | 10.77 | |
| GROUP II | 10.41 | 18.22 | 5.58 | | 12.62 | |
| GROUP III | 7.71 | 18.64 | 13.79 | 11.06 | | |



Graph-9

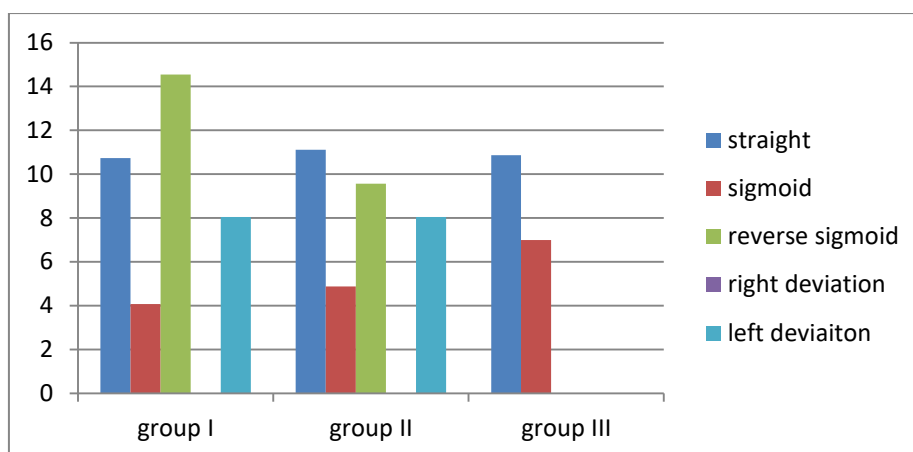
Table- 9 and Graph -9 inference: On comparing maxillary sinus volume with symmetrical frontal sinus and nasal septum patterns there were no significant changes and the $P > 0.5$.

When Frontal sinus is asymmetry

When asymmetrical frontal sinus is compared with mean maxillary sinus volume and nasal septum patterns, right deviations were absent in all the three groups. Reverse sigmoid and left deviation patterns were not observed in Group III. $p > 0.5$ was not significant (Table -10 and Graph- 10).

Table 10

| MEAN MAXILLARY SINUS VOLUME | STRAIGHT | SIGMOID | REVERSE SIGMOID | RIGHT DEVIATION | LEFT DEVIATION | P>0.5 |
|-----------------------------|----------|---------|-----------------|-----------------|----------------|-----------------|
| GROUP I | 10.74 | 4.07 | 14.54 | | 8.04 | |
| GROUP II | 11.11 | 4.88 | 9.57 | | 8.04 | |
| GROUP III | 10.86 | 6.99 | | | | |



Graph 10

Table-10 and Graph -10 inference: On comparing maxillary sinus volume with asymmetrical frontal sinus and nasal septum patterns there were no significant changes and the $P > 0.5$.

DISCUSSION

The use of radiological techniques became widespread during the 21st century by the creation of newer techniques which helps in forensic identification [7]. Various studies by Cameriere R *et al.*; in 2008 [8], Ponde JM *et al.*; in 2008 [9], Maria PD *et al.*; in 2010 [10], Karjodkar FR *et al.*; 2012 [11], Silva FR *et al.*; in 2015, have been done to use frontal sinus for personal identification.

The sample size in the present study was 100, in comparison with other studies done by Bolzan and Tuncan-duva in 2012 [12] and Ruder *et al.*; in 2012 which included 40 and 125 cases respectively. The reason for this sample size is due to the fact that analysis were made only on the basis of CBCT images as compared to that of similar studies which included radiographs. This study is first of its kind and which includes Frontal sinus, Maxillary sinus and nasal septum patterns in personal identification.

Images of individuals were selected randomly between the ages of 21 to 50 years which was in accordance with the study done by Tiwari P *et al.*; in 2016 [13], David and Saxena in 2010 [14], Porobonikava in 1974 [15], Krogman in 1962 [16], and Libersa and Faber in 1957 [17]. The frontal sinus was compared for its symmetry in both the genders. The data from our studies show maximum symmetry of frontal sinus in male patients of Group-I(30%) and least in Group-III(10%). Similarly maximum asymmetries of frontal sinus were observed in male patients of Group-II (42%) and least in Group 3(null). From the above inference, the male patients of Group-III showed least symmetry and asymmetry. Results of our study were in concordance with that of the study by David and Saxena [14] (58% & 32%).

Various patterns of nasal septum were observed in our study. The nasal septum pattern was evaluated as straight, sigmoid, reverse sigmoid, right deviation and left deviation. Most images obtained in Group I and Group II has straight, whereas in Group III straight and sigmoid are equal in number. Male have more straight nasal septum in Group III, II and sigmoid in Group I. Female have more straight nasal septum in Group I, II and in sigmoid in Group III

We proposed in our study to do multiple comparisons by combining the frontal sinus and Nasal septum patterns to elicit the possibilities of identification of humans. In the present study, the comparison of nasal septum pattern with frontal sinus symmetry and asymmetry showed straight nasal septum in Group-II which was statistically significant ($P < 0.01\%$) and in concordance with study conducted by Saraswathi *et al.*; in 2016. Tanuguchi *et al.*; in 2002 [18], studied possible use of nasal septum and frontal sinus patterns in radiographic identification by use of orthopantomograms. However, the previous study was overcome in our study by the use of CBCT which provides accurate measurements of images than orthopantomogram and accuracy is obtained with higher probability leading to systematic identification. There was significant correlation between the patterns of frontal sinus with Nasal septum than their individual patterns.

The volume of the maxillary sinus calculated by geometric calculation yielded results that were highly significant between the groups ($p < 0.5$). The present study shows the volume of maxillary sinus to decrease with increase in the age. Also it decreases with a correlation co-efficient of -0.93% . However comparison of the maxillary sinus volume with the nasal septum patterns there was volumetric changes evident with reverse sigmoid pattern which is significant in all groups. ($P < 0.01$).

Further in our study, we have elicited the relationship between frontal sinus, Maxillary sinus and

Nasal septum patterns. Frontal sinus with symmetry and asymmetry when compared with the similar volumetric change of maxillary sinus showed higher values in Group-II with reverse sigmoid pattern being predominant. However the correlation between them were not significant ($P>0.5$). Maxillary sinus, Frontal sinus and Nasal septum patterns comparing together was not applicable, since Maxillary sinus and Frontal sinus are two different anatomical structures in personal identification. Frontal sinus and Maxillary sinus individually is more accurate in personal identification when nasal septum is used as an adjuvant. Considering the above described results, the combined use of nasal septum patterns with frontal sinus will be helpful for screening in mass disasters. However for comparison ante mortem and post mortem records are necessary to give a possible identification. The limitations of the study include that of involving the individuals between 20-50 years of age. Further studies are required with more number of images for comparison in future to arrive at a positive identification.

CONCLUSION:

Forensic in identification of individuals requires ante and post mortem records. However in present study a significant correlation between the frontal sinus and Nasal septum patterns was found which could be used in forensics for identification by exclusion and comparison of maxillary sinus with nasal septum also aids in personal identification.

REFERENCES:

1. Pramod JB, Marya AV, Sharma V. Role of forensic odontologist in post mortem person identification. Dental research journal. 2013 May 1; 9(5).
2. Sidhu R, Chandra S, Devi P, Taneja N, Sah K, Kaur N. Forensic importance of maxillary sinus in gender determination: a morphometric analysis from Western Uttar Pradesh, India. European Journal of General Dentistry. 2014 Jan 1; 3(1):53.
3. RuhiSidhu, Sunira Chandra1, Parvathi Devi, Neeraj Taneja2, Kunal Sah3, NavdeepKau)
4. Tambawala SS, Karjodkar FR, Sansare K, Prakash N. Sexual dimorphism of maxillary sinus using cone beam computed tomography. Egyptian Journal of Forensic Sciences. 2016 Jun 30;6(2):120-5.
5. Hamdy RM. Three-dimensional linear and volumetric analysis of maxillary sinus pneumatization. Journal of advanced research. 2014 May 31;5(3):387-95.
6. David MP, Saxena R. Use of frontal sinus and nasal septum patterns as an aid in personal identification: A digital radiographic pilot study. Journal of forensic dental sciences. 2010 Jul 1;2(2):77.
7. Tiwari P, Bhovi TV, Jaju PP, Gupta M, Shrivastava K. Frontal Sinus-A Useful Personal Identification Tool. Journal of Oral Medicine, Oral Surgery, Oral Pathology and Oral Radiology. 2016;2(1):11-22.
8. Cameriere R, Ferrante L, Molleson T, Brown B. Frontal sinus accuracy in identification as measured by false positives in kin groups. Journal of forensic sciences. 2008 Nov 1;53(6):1280-2.
9. Ponde JM, Metzger P, Amaral G, Machado M, Prandini M. Anatomic variations of the frontal sinus. Minim Invasive Neurosurg. 2003;46:29-32
10. David MP, Saxena R. Use of frontal sinus and nasal septum patterns as an aid in personal identification: A digital radiographic pilot study. Journal of forensic dental sciences. 2010 Jul 1;2(2):77.
11. Patil N, Karjodkar FR, Sontakke S, Sansare K, Salvi R. Uniqueness of radiographic patterns of the frontal sinus for personal identification. Imaging science in dentistry. 2012 Dec 1;42(4):213-7.
12. Bolzan JD, Tucunduva MJ. Estudo radiográfico da cavidade nasal e dos seios paranasais e suas variações. Sci. Health. 2012 Jan;3(1):23-31.
13. Tiwari P, Bhovi TV, Jaju PP, Gupta M, Shrivastava K. Frontal Sinus-A Useful Personal Identification Tool. Journal of Oral Medicine, Oral Surgery, Oral Pathology and Oral Radiology. 2016;2(1):11-22.
14. Besana JL, Rogers TL. Personal identification using the frontal sinus. Journal of forensic sciences. 2010 May 1;55(3):584-9.
15. Pobornikova S. An x-ray investigation of the development of the frontal sinuses in children. Folia medica. 1973 Dec; 16(4):213-20.
16. Krogman WM. The human skeleton in forensic medicine. Thomas, Springfield. 1962
17. Libersa C, Faber M. Etude anatomo-radiologique du sinus frontal chez l'enfant. Lille Med. 1958;3:453.
18. KAMIKODAI Y, FUJITA Q. Possible Use of Nasal Septum and Frontal Sinus Patterns to Radiographic Identification of Unknown Human Remains. Osaka city med. J. 2003;49:31-8.