

Management of Open Apex in Permanent Anterior Teeth- Case Reports

Dr. Payal Patel¹, Dr. Zarna Patel^{2*}, Dr. Kamal Bagda³, Dr. Kailash Attur⁴, Dr. Kruti Kachoriya⁵

¹Post Graduate Student; Department of Conservative Dentistry and Endodontics; Narsinhbhai Patel Dental College and Hospital; Visnagar India

²Post Graduate Student; Department of Conservative Dentistry and Endodontics; Narsinhbhai Patel Dental College and Hospital; Visnagar India

³Professor and Head of the Department; Department of Conservative Dentistry and Endodontics; Narsinhbhai Patel Dental College and Hospital; Visnagar India

⁴Professor and Head of the Department; Department of Conservative Dentistry and Endodontics; Narsinhbhai Patel Dental College and Hospital; Visnagar India

⁵Post Graduate Student; Department of Conservative Dentistry and Endodontics; Narsinhbhai Patel Dental College and Hospital; Visnagar Gujarat India

*Corresponding author: Dr. Zarna Patel

| Received: 02.06.2019 | Accepted: 12.06.2019 | Published: 19.06.2019

DOI: [10.36347/sjds.2019.v06i06.002](https://doi.org/10.36347/sjds.2019.v06i06.002)

Abstract

Case Report

There are three clinical cases exhibiting teeth with open apices and were treated using these protocols. The first case was managed with biodentine. In the second case, an apical plug of mineral trioxide aggregate (MTA) was used before obturation with gutta-percha and sealer and treatment was completed during 2 appointments. In the third case, the tooth, which had a divergent root canal system, was completely obturated with biodentine and treatment was also completed over 2 appointments. In all 3 cases, signs of bone healing were observed after treatment

Key words: Apexification, MTA, biodentine, PRF.

Copyright © 2019: This is an open-access article distributed under the terms of the Creative Commons Attribution license which permits unrestricted use, distribution, and reproduction in any medium for non-commercial use (NonCommercial, or CC-BY-NC) provided the original author and source are credited.

INTRODUCTION

The new developments have greatly enhanced the clinician's ability to achieve the biologically-based objectives of root canal treatment, which include removal of all tissue, bacteria and bacterial products and substrates from the root canal system, shaping and filling the canal system [1].

Open apices are a problem for the realization of the root canal treatment because [2]

- The infected root canal space cannot be disinfected with the standard root canal protocol with the aggressive use of endodontic files.
- After disinfection filling the root canal is difficult because the open apex provides no barrier for stopping the root filling material before impinging on the periodontal tissues.
- Also, the roots of these teeth are thin with a higher susceptibility to fracture [3]
- And hence can have a negative effect on the apical healing process.

These problems can be overcome by the process of creating a hard tissue barrier at an open apex or at an over instrumented apex which is termed as apexification[4].

Calcium hydroxide was the material of choice earlier. But it has certain limitations like the length of time needed to form apical barrier, the number of dressings needed for complete closure of apex, etc[5].

Mineral Trioxide Aggregate (MTA) was first described in dental scientific literature in 1992 and both white and grey MTA formulae contain 75% Portland cement, 20% bismuth oxide and 5% gypsum by weight. It is bio - compatible and forms dentinal bridge, cementum and periodontal ligament regeneration. It has the ability to stimulate cytokine release from the bone cells, indicating that it actively promotes hard tissue formation [6].

Apart from these Biodentine a calcium silicate based cement is also available having physical properties similar to MTA.

Therefore, present case report highlights the management of permanent teeth with immature apices using MTA, Biodentine matrix.

CASE REPORT 1

A 21-year-old male patient was referred to the Department of Conservative Dentistry and Endodontics with a chief complaint of fractured and discolored maxillary left central incisor. Patient gave a

history of trauma at the age of 10 years. Intraoral examination revealed a discolored maxillary left central incisor. Patient had pain on percussion. Radiographic examination revealed an immature apex associated with

a periapical lesion and internal resorption in relation to 21 (figure 1). Diagnosis of periapical abscess with internal resorption in relation to 21.

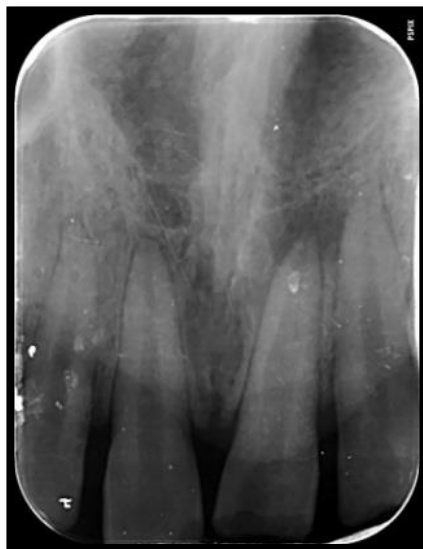

Fig-1: Preoperative radiograph

Considering the age of the patient and the surgical trauma that could occur, it was decided to opt for nonsurgical root canal treatment. The tooth was isolated under rubber dam, and endodontic access cavity was prepared. The root canal was explored with #25 K-file (Mani, Tamil Nadu, and India). The canal was patent, wide, and the largest file to bind to apical extent of the canal was #80 K-file. An intraoral periapical radiograph (IOPA) was taken to determine the working length (figure 2). The root canal was gently, circumferentially filed with #80K-

file. The canal was irrigated intermittently with 3% sodium hypochlorite (NaOCl) and normal saline. Finally, passive irrigation with Endovac was carried out for 1 minute with NaOCl as irrigant. The root canal was then dried with sterile absorbent points. A thick paste of Calcium hydroxide (RC CAL) was placed in the root canal (figure 3) and the patient was recalled after 2 weeks. At 2-week recall appointment, CH was removed using H-files (Mani, Tamil Nadu, India).

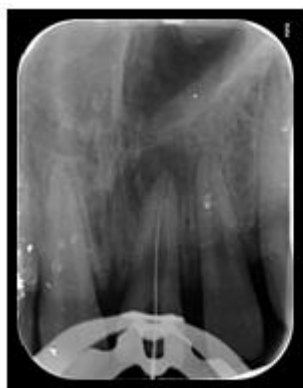

Fig-2

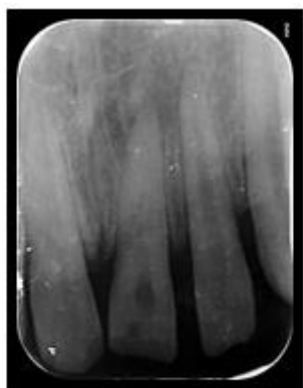

Fig-3

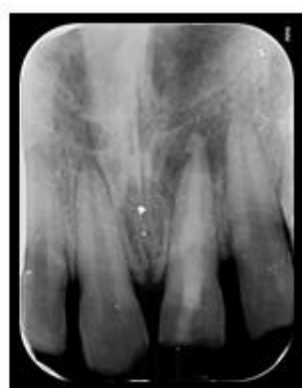

Fig-4

Fig-2: Working length determination, Fig-3-intracanal medicament, Fig-4- immediate post-operative radiograph

PRF membrane as an internal matrix was used at the apical foramen prior to biodentine placement. Ten milliliters of patient's venous blood was drawn by venipuncture from the anticubital vein, and was collected in 10 ml test tube without anticoagulant and immediately centrifuged

(Process[®] centrifuge PC-02; Process Ltd., Nice, France) at 3000 rpm for 15 minutes. The fibrin clot was separated from the lower most layer of the centrifugation product. The PRF clot was gently pressed into a membrane form with sterile moist

gauze and placed on a sterile glass slab. The required quantity of PRF membrane was introduced into the canal and positioned apically with a hand plugger at the apical foramen and into the bony space beyond it.

Biodentine (septodont,) was mixed with sterile water as per manufacturer instructions and placed in the apical third using hand pluggers and compacted with absorbent points. Thus, whole canal with the resorbed defect was filled with biodentine

(figure 4). Access cavity was sealed with permanent restoration using composite resins (3M ESPE, Seefeld, Germany).

Patient was recalled after one week and was completely asymptomatic. Further, the tooth was restored with porcelain fused to metal (PFM) crown. The patient was recalled after 3 months. At 6 months of follow-up,(figure 5) the patient was asymptomatic and periapical radiograph demonstrated satisfactory healing.

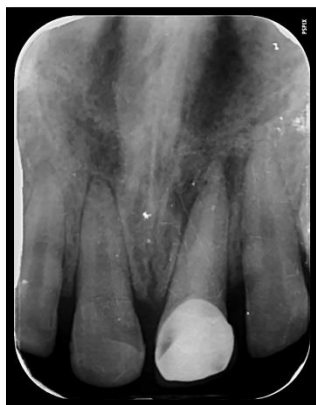

Fig-5: Follow-up after 6 months

CASE REPORT 2

A 19-year-old, male patient was referred to the department of conservative dentistry and endodontics with a complaint of broken tooth and pus discharge in relation to upper left front tooth region of the jaw since 15 days. Upon further investigations patient revealed a history of dental trauma due to car accident 10 years

ago. A periapical radiograph was taken(figure 6) which revealed the presence of fracture in the dental crown, root apex with incomplete formation and periradicular radiolucent lesion. Gutta percha tracing (figure 7) revealed the involved tooth. There was no spontaneous pain and/or positive responses to thermal and electrical testing.

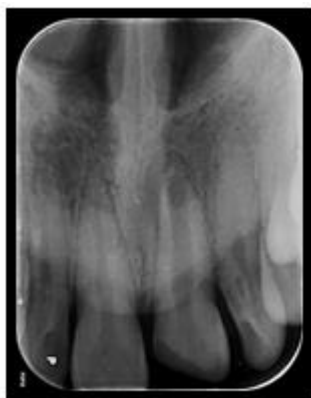

Fig-6

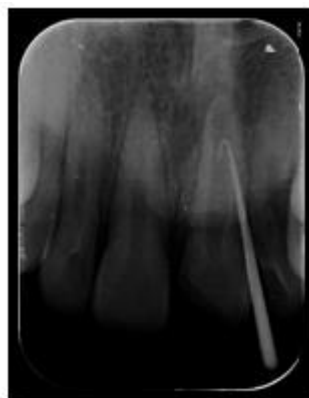

Fig-7

Fig-6-preoperative; Fig-7-sinus tract tracing using gutta-percha

The treatment plan was nonsurgical endodontic treatment followed by MTA apexification. After gaining the coronal access, the root canal was irrigated with 3% sodium hypochlorite and normal saline, 80 K-file (Mani, Tamil Nadu, India) was inserted 2 mm short of the estimated radiographic initial image, to obtain instrumentation length(figure 8).

Upon completion of the chemo-mechanical preparation, irrigation was performed similar to case report 1. Calcium hydroxide with iodoform base was used as an Intracanal medicament for 21 days. Following this in the next appointment the medicament was removed. PRF membrane was used as an internal matrix at the apical foramen prior to MTA placement. Following

procedure was similar to case report 1. Then MTA (Angelus, Londrina, PR, BR) was mixed according to the manufacturer instructions and apical barrier was placed, in approximately 4 mm thickness in the apical third of the root canal (figure 9). A #80 gutta-percha point was used for confirmation of the apical barrier. obturation was done with resin-based sealer (MTA Fillapex; Angelus, Londrina, SP, BR), by lateral condensation technique. Access cavity was sealed with

permanent restoration using composite resin (3M ESPE, Seefeld, Germany) (figure 10). After 6 months, a new clinical and radiographic control was performed (figure 11). There were no clinical signs of abnormality in the alveolar mucosa, and the treated tooth showed no sensitivity in vertical and or horizontal percussion. The radiographic assessment indicated local anatomical normality and total regression of the initial radiolucent lesion.

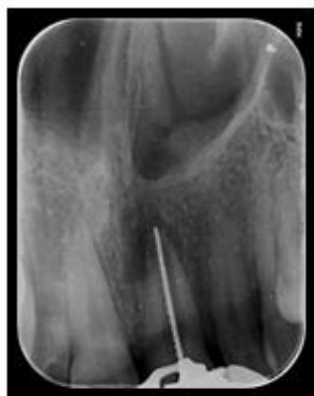

Fig-8

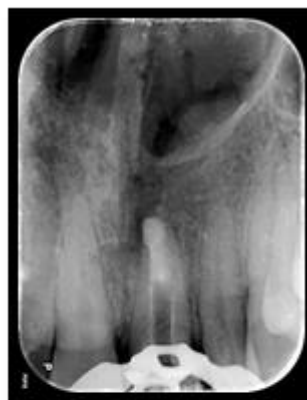

Fig-9

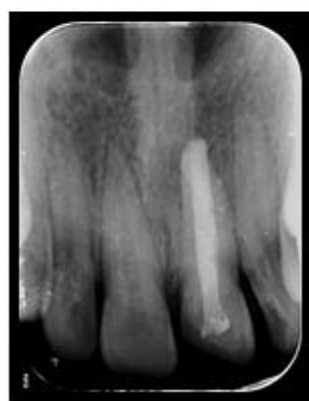

Fig-10

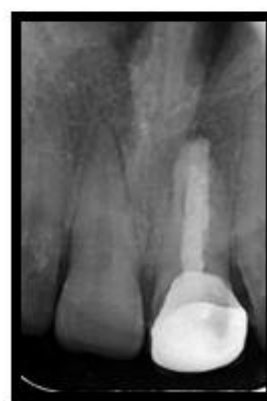

Fig-11

Fig-8: Working length determination; Figure 9-MTA plug; Figure 10-immediate post-operative radiograph; Figure 11-follow-up after 6 months

DISCUSSION

Root-end closure previously referred to as apexification is the induction of an artificial calcified barrier across the open apex. An immature root has a considerably wide apical opening that may be apically diverging or parallel with thin canal walls [4]. The teeth described in these 3 cases had different degrees of open apices and associated apical abscess [7].

The factors essential for success are thorough debridement and disinfection of the root canal space [4]. When treating nonvital teeth, a main issue is eliminating bacteria from the root canal system. Instrumentation is a problem in teeth

with open apices; cleaning and disinfection of the root canal system rely on the chemical action of NaOCl as an irrigant and calcium hydroxide as an intracanal dressing [7]. NaOCl is known to be toxic, especially in high concentrations.

Irrigation for teeth with open apices, there can be increased risk of pushing the irrigant beyond the apical foramen. Therefore, it is advisable to use less concentrated NaOCl, which is less toxic. In all 3 cases, 3% NaOCl was used and final irrigant was allowed to flow passively using the endovac (apical negative pressure irrigation) (figure 12).

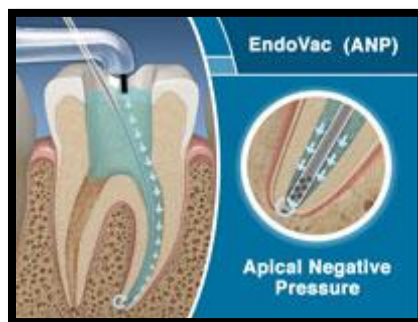


Fig-12: Apical negative pressure irrigation technique

The currently introduced technique of using PRF membrane was considered as an apical matrix. Platelet-rich fibrin is an autologous fibrin gel with cicatricial properties; it is a new platelet concentrate, which has advantages of low cost, ease of procedure, does not dissolve quickly after application, and is biocompatible.

There is increasing popularity with one visit apexification technique using Mineral Trioxide Aggregate (MTA) (figure 13) as osteoconductive apical

barrier. Certain properties of MTA are non-cytotoxic and stimulate Cementogenesis. Also has the ability to induce cementum like hard tissue when used adjacent to the periradicular tissues. MTA is a promising material as a result of its superior sealing property, its ability to set in the presence of blood and its biocompatibility. Added advantage is that the presence of moisture does not affect its sealing ability. Despite its good physical and biologic properties, extended setting time has been a main disadvantage [6].

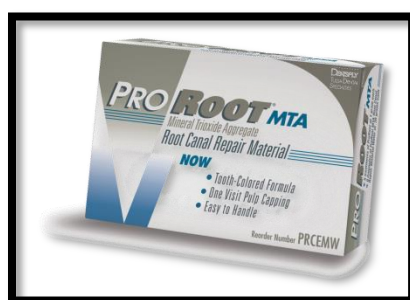


Fig-13 : MTA

Biodentine (figure 14) can also be used as an effective alternative to MTA as highlighted through this case presentation. Apexification with Biodentine requires significantly less time. This can lessen the treatment time between the patient’s first appointment

and the final restoration. The importance of this approach lies in the effective cleaning and shaping of the root canal, followed by apical seal with a material that favors regeneration.

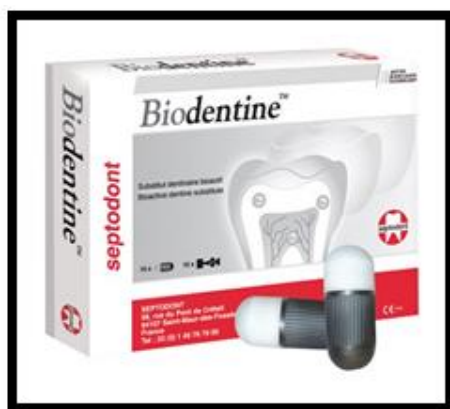

Fig-14: Biodentine

Kokate and Pawar conducted a study that compared the microleakage of glass ionomer cement, MTA, and Biodentine™ when used as a retrograde filling material and concluded that Biodentine™ exhibited the least microleakage when compared to other materials used. Research suggests that a high pH and released calcium ions are required for a material to stimulate mineralization in the process of hard tissue healing. Sulthan carried out a study to evaluate the pH and calcium ion release of MTA and Biodentine™ when used as root end fillings. He concluded that Biodentine™ presented alkaline pH and ability to release calcium ions similar to that of MTA. This case report emphasizes the novel approach of using Biodentine to achieve single visit apexification of the cases with an open apex and large periapical lesion. The use of Biodentine has been demonstrated to induce faster periapical healing for single visit apexification of the cases with large periapical lesions. The material is still under study and many more advancements in its clinical applications are expected in near future [8].

CONCLUSION

This case reports demonstrates that teeth with wide open apices can be treated successfully with nonsurgical treatment using PRF as internal apical matrix under MTA apical plug for one-step apexification procedure. And also the efficacy of Bio Dentine as a dent in substitute is yet to be clinically proven for its therapeutic indications; it may be a promising material for apexification. Further long-term randomized clinical trial need to be conducted to evaluate the successful outcomes.

REFERENCES

1. Regan J, Gutmann J. Preparation of the root canal system. *Harty's Endodontics In Clinical Practice*. 6th Edition. 77-94
2. Magro MG, Kuga MC, Ricci WA, Keine KC, Tonetto MR, Lima SL, Borges AH, Belizário LG, Bandeca MC. Endodontic Management of Open Apex Teeth Using Lyophilized Collagen Sponge and MTA Cement: Report of Two Cases. *Iranian endodontic journal*. 2017;12(2):248.
3. Trope M. Treatment of the immature tooth with a non-vital pulp and apical periodontitis. *Dent Clin North Am*. 2010;54(2):313-24.
4. Pawar R, Margsayam S, Shenoy V, Shaikh S. Management of a Traumatized Open Apex Tooth with a Combination of Mineral Trioxide Aggregate Apical Plug and Platelet-rich Fibrin Apical Matrix. *Journal of contemporary dentistry jan-apr*. 2016;6(1):57-62.
5. Muhamad A, Abdulgani A, Abdulgani M. Open Apex with Mineral Trioxide Aggregate- Case Report. *Journal of Dental and Medical Sciences*; OCT. 2016;15(10):81-87.
6. Muhamad A, Azzaldeen A, AHanali. Mineral Trioxide Aggregate (MTA) in apexification. *Endodontology*. Dec 2013; 25(2); 97-101.
7. Khetarpal A, Chaudhary S, Talwar S, Verma M. Endodontic management of open apex using Biodentine as a novel apical matrix. *Indian Journal of Dental Research*. 2014; 513-16;25(4).