

Complications of Miniscrew Anchorage in Orthodontics- A Literature Review

Sharath Kumar Shetty¹, Vijayananda K. Madhur², Mohammed Mazvin Nihal^{3*}, Mahesh Kumar Y⁴

¹Professor & HOD, Department of Orthodontics and Dentofacial Orthopaedics, K. V. G. Dental College and Hospital, Sullia, Karnataka, India

²Reader, Department of Orthodontics and Dentofacial Orthopaedics, K. V. G. Dental College and Hospital, Sullia, Karnataka, India

³Post Graduate Student, Department of Orthodontics and Dentofacial Orthopaedics, K. V. G. Dental College and Hospital, Sullia, Karnataka, India

⁴Professor, Department of Orthodontics and Dentofacial Orthopaedics, K. V. G. Dental College and Hospital, Sullia, Karnataka, India

*Corresponding author: Mohammed Mazvin Nihal

| Received: 02.03.2019 | Accepted: 05.03.2019 | Published: 30.03.2019

DOI: 10.36347/sjds.2019.v06i03.017

Abstract

Review Article

Miniscrew anchorage has greatly expanded the limit of clinical orthodontics. Even without patient compliance, miniscrews can provide stationary anchorages for various tooth movements and even make it possible to move the tooth in directions which have been impossible with traditional orthodontic mechanics. On the other hand, the clinical use of miniscrew anchorage may include some complication. We have to understand these risks and complications of miniscrew anchorage which will lead to their failure and pay attention for their safety-conscious use.

Keywords: Miniscrew, orthodontics, compliance.

Copyright © 2019: This is an open-access article distributed under the terms of the Creative Commons Attribution license which permits unrestricted use, distribution, and reproduction in any medium for non-commercial use (NonCommercial, or CC-BY-NC) provided the original author and source are credited.

INTRODUCTION

Anchorage control is one of the key issues to be taken into account when planning orthodontic treatment [1]. To get the appropriate anchorage, numerous anchorage devices are proposed and used for more than a century. Extraoral anchorages such as headgears or facemasks are the most powerful tools but they have a weak point that their effectiveness depends on the patient compliance. Intermaxillary elastics also have the same disadvantage. Intraoral anchorages, i.e. transpalatal arch, lingual arch, holding arch and so on, do not require patient compliance but it is impossible to provide absolute anchorage.

For clinicians, common concerns about skeletal anchorage are success rates and risk factors for failure. However, few human studies examined factors associated with the stability of skeletal anchorage.^{2,4} Chung et al⁴ reported that failure was more likely when screws were placed in nonkeratinized mucosa. In human and animal studies, it was reported that the success rates of miniscrews in the mandible were significantly lower than in the maxilla, even though mandibular dental implants have a higher success rate [2,4-6].

Shapiro and Kokich[7] proposed that endosseous implants can be used to provide anchors for tooth and bone movement. Compared with traditional anchorage reinforcements such as transpalatal arches and extraoral appliances, mini-implants are

advantageous because of their smaller size, convenient insertion and removal procedures, relatively low cost, and the fact that immediate orthodontic loading is possible after surgery [8,9]. However, a practical issue is mini-implant loosening, which can compromise the success rate of the procedure.

The clinical use of miniscrew anchorage accompanies some risks and complications, which occur during screw insertion, under orthodontic loading, and during removal [10]. Screw fracture might be one of the most undesirable side effects in clinical use of miniscrew anchorage, which occurs in not only the placement but also the removal [11].

Screw failure

Most of screw failure occurs in a week after the implantation (Fig. 1). A lot of factors are proposed for the relation with screw failure. For the host factors, age [12, 13], smoking¹⁴, oral hygiene control [15, 16], implant site [17, 14, 12, 15, 16]. Keratinized tissue¹⁸, cortical bone thickness [19, 20], bone density [19, 21] are reported.

For the technical factors, screw diameter [15,19,21,22] screw length [15, 23], screw taper [24, 25], shape of screw thread [21], insertion method (selfdrilling vs self-tapping)[26, 27], insertion torque [14,28,25,27], insertion angle [29, 30] treatment period [23], amount of loading¹⁵, direction of loading [31], microfracture of alveolar bone³² are suggested (Table 1).

Papageorgiou *et al.* [14] recently reported a meta-analysis in 82 scientific papers describing success rates of orthodontic miniscrews or risk factors for screw failure. They analyzed a lot of factors and found the two factors closely related with the success rates, which are the screw contact to the adjacent root and screw placement in the mandible.

Kuroda *et al.* [33] initially reported that screw root proximity was one of the major risk factors for screw failure. They analyzed dental radiographs taken after the screw insertion and each screw was classified

according to its proximity to the adjacent root; category I, the screw was absolutely separate from the root; category II, the apex of the screw appeared to touch the lamina dura; and category III, the body of the screw was overlaid on the lamina dura. Category I and II showed high success rates of 92.9% and 87.2%, respectively, but category III showed 62.5%. This tendency was more obviously demonstrated in the mandible. Several reports recently indicated same conclusion by using a three-dimensional computed tomography [34, 35].

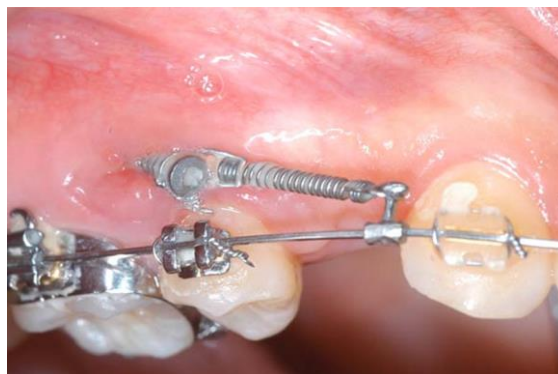

Fig-1: A screw failed during loading. Slight inflammation was shown around the screw

To avoid the screw root proximity, screws can be placed out of dentition, i.e. midpalate or retromolar area. However, the screws require some complicated auxiliaries for loading to teeth, which sometimes make the patients discomfort. Therefore, we strongly recommend an oblique angle insertion of interradicular miniscrews. Roots get thinner when it goes close to the apex, and the interradicular spaces become wider [36]. Hence the position of screw insertion had better be placed high as possible to avoid the root proximity, however; the alveolar bone apart from the clinical crown is normally covered with non-keratinized tissue. Some reports suggested that screw placed through non keratinized mucosa had higher failure rate [18], and it sometimes become cause of pain and discomfort. Then, screw should be placed through keratinized mucosa (attached gingiva) with an oblique angle insertion. The oblique insertion decreases the possibility of screw root contact not only in insertion but also during active tooth movement, which is quite useful in the cases of molar intrusion or group distalization. Moreover, the oblique inserted miniscrews increase the cortical bone—screw contact and must contribute to enhance the initial stability.

Root contact

Root contact during insertion is associated with increased the failure rates of mini implants. The rate and pattern of root contacts have been reported to be associated with the surgery site and the operator's experience. Root contact produces greater stresses [37]. Which could result in irreversible loss of mini implant stability [38]. Mini implants with root contact were

found to be surrounded by increased volumes of soft tissues, with inflammation around the mini implants, but the damaged areas of the roots were finally repaired with a narrow zone of mineralized tissue deposited on the root surface after screw removal [39, 40]. Close proximity of the mini-implant body and adjacent roots should be avoided in order to avoid periodontal and root damage, although histological studies show that cellular cementum repair occurs after root trauma [39, 41, 42-47]. The major problem with close implant–root proximity is that this provides inadequate bone coverage for the threads, destabilizes the mini-implant, and increases failure rates [48-53]. Root proximity appears to be more of a risk factor than variations in cortical thickness.⁵³Root contact, or proximity, is usually detected during mini-implant insertion by a sharp increase in insertion resistance blunting of the mini-implant tip, patient discomfort [39, 44, 54]. These signs should be taken as indicators of close proximity and the mini-implant withdrawn and re-inserted at a different location or angle.

Pain and discomfort after implantation

When the miniscrew insertion is proposed to patients, most of them are initially afraid and ask “Is it OK to put a screw through the gingiva? Is it painful?” But it is true that placement and removal of miniscrew are not invasive and most patients do not feel pain during and after implantation [55, 56]. We previously evaluated the postoperative pain and discomfort after implantation of miniscrews, screws, and miniplates using a retrospective questionnaire in 75 patients [55]. Most patients receiving screws or mini-plates with

mucoperiosteal flap surgery reported pain 1 day after the implantation, and 35% of them have still felt pain a week after. Moreover, most patients appealed the discomfort and swelling after the surgical procedure. On the other hand, 35% of the patients placed miniscrews without flap surgery reported slight pain immediately after the implantation, and only 8% of them felt pain at 1 day after. None reported pain at one week after the insertion. Conclusively, miniscrews placed without flap surgery have suitable characteristics as orthodontic anchorage because of less pain and discomfort.

Placement in the median plate

Mini implants are placed in maxillary and mandibular buccal alveolar bone and are used to improve anchorage for space closure or molar intrusion in patients with open bite. The screws are used during orthodontic treatment to improve orthodontic anchorage and ensure that teeth move predictably and without reciprocal movement. Those inserted into the median palate can be used to provide anchorage for full-arch distalization. Orthodontic mini-screws placed in the palatal bone at the midpalatal suture have failed because of a lack of ossification [57-60]. Nienkemper *et al.* [61] found that orthodontic mini-screw stability depended mainly on mechanical maintenance, which should increase with insertion depth, because of the larger bone-to-implant contact area. Clinicians must avoid nearby anatomical structures, such as the nasal cavity, because nasal cavity perforation can cause infection [62, 63]. Therefore, sufficient topographical knowledge of the median palate regions and proper placement technique is desirable. Use of excessively long mini-screws increases the risk of nasal cavity perforation and related complications [64, 65]. Thus, clinicians must have sufficient tomographic knowledge of the midpalatal region before performing this procedure.

Tooth movement to the edentulous area

Tooth movement through bone-deficient areas (e.g., the maxillary sinus, the atrophic alveolar ridge) is a challenging matter for orthodontist. Emergence of implant-anchored orthodontics can clear mechanical considerations, however; environmental factors still remain. Several reports demonstrated that tooth movement to the bone-deficient areas might reduce the alveolar bone height and/or the root length [66, 67]. In contrast, some reports have suggested that a tooth with

normal supporting apparatus height can be orthodontically moved through the maxillary sinus while maintaining pulp vitality and bone support and exhibiting normal width of the periodontal ligament on both the compression and tension sides [68]. Recently, we moved the maxillary first molar of 20 mice toward the palatal side for 1–14 days, and evaluated the bone remodeling around the root [69]. When proper mechanical stress was applied to the tooth, the periodontal ligament on the palatal side was immediately compressed to approximately half of its original width. At the same time, osteoblasts deposited new bone on the sinus wall prior to bone resorption by osteoclasts on the periodontal ligament side. As a result of these sequential processes, bone on the sinus wall maintained a consistent thickness during the entire observation period. No root resorption was observed. On the other hand, strong force application stimulated more bone formation on the sinus wall but bone resorption on the periodontal ligament side was delayed because of the hyalinization of periodontal ligament. The resulting temporary increase in total thickness of the sinus wall essentially indicates that strong force application will not accelerate tooth movement. Moreover, some root resorption was induced under the excessive force application. Conclusively, mechanotransduction of appropriate mechanical stress can be exploited to induce bone formation in the maxillary sinus so that tooth can be moved into the sinus without abnormal bone and root resorption. However, excessive force decreases efficiency of tooth movement and induces root resorption.

Damage of soft tissues

When a screw is inserted with an oblique angle to the bone surface, a clinician has to take care not to slip the screw. To prevent the soft tissue damage by the slippage, a self-tapping method, pre-drilling with a round bar on the cortical bone, must be effective. Screws placed through the non-keratinized gingiva or movable gingiva stimulates surrounding soft tissue and sometimes evokes the peri-implantitis. Chang *et al.* [70], reported that miniscrew placement through non-keratinized tissue sometimes caused screw failure. Moreover, the screws are often covered with surrounding movable mucosa and it will become cause of pain and discomfort (Fig. 2). Therefore, miniscrews had better be implanted in the range of attached/keratinized gingiva.

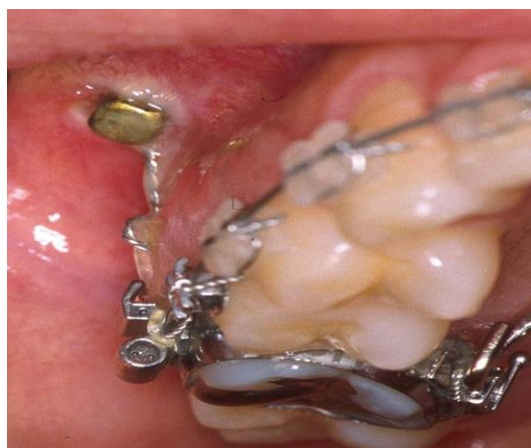

Fig-2: A screw through non-keratinized oral mucosa. Slight inflammation was shown around the screw head

The screw head placed close to the mucogingival junction irritates the movable mucosa and it becomes cause of ulcer. Auxiliaries attached between the screw head and the archwire, i.e. coil springs, elastomeric chains, hooks, and ligation wires, should be adjusted not to touch the gingiva or oral mucosa to avoid the pain and discomfort a patient. A palatal miniscrew sometimes induces pain and injury on the surface of tongue. Use of miniscrews makes it possible to distalize the whole dentition, which breaks the methodological limitation of tooth movement. However; an excessive distal movement causes impaction of the second molar under the gingiva and evokes peri-coronitis, especially in the mandible. Proper diagnosis based on the clinical examinations is important in the implant-anchored orthodontics.

Surgical complications

Any number of complications can occur during or after the placement of dental implants. Most are immediately apparent; however, some can occur. Christman and colleagues [1] recommended the use of a safety checklist before the placement of

implants; this checklist includes a review of the patient's medical and dental history, a diagnostic workup, a determination of the periodontal stability of adjacent teeth, and effective communication with restorative partners much later.

Bleeding

Minor bleeding is inherent during the placement of dental implants, as with any surgical procedure. However, major bleeding is uncommon and can be life threatening. The causes of major bleeding may be related to systemic issues or regional anatomy.

Maxilla

Bleeding with the placement of maxillary implants is rare. Moderate or severe maxillary bleeding may result from injury to intraosseous vessels lying within the walls of the maxilla. The vessels can be seen on computed tomography (CT), but not on plain radiographic films (Fig. 3). Anterior or posterior nasal bleeding, which may be profuse, and rapid swelling of the gingiva are common signs associated with an injury to one of these vessels.

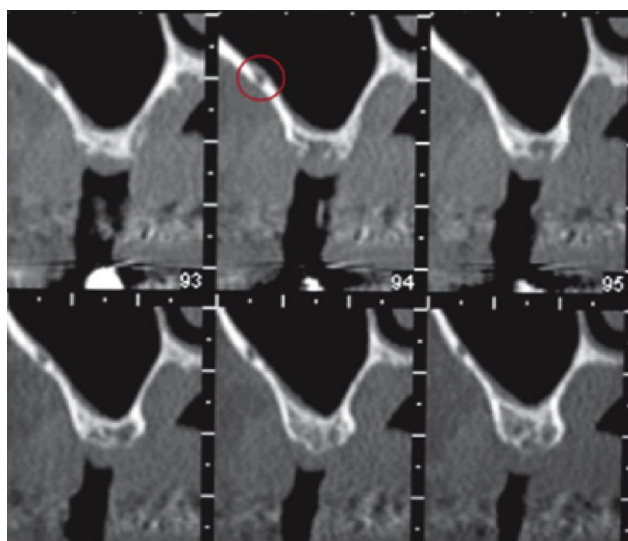


Fig-3: Cone beam computerized tomography of a patient who had a large hematoma after a sinus lift. Red circle indicates vessel in the bony of the maxillary sinus

Mandible

Multiple publications have reported bleeding, in some cases life-threatening hemorrhage, after the placement of implants in the anterior mandible. The cause of bleeding during implant placement in the anterior mandible is perforation of the lingual cortex, resulting in injury to the terminal branches of the sublingual or submental artery [71, 72]. The risk of perforation is high when the lingual fossa is very deep and is even higher when no flap is elevated during the procedure.

Infection

Postoperative infections can occur after implant placement with or without grafting of the site. A variety of local and systemic factors may play a role in the development of such infection. Our review of the literature suggests an inconsistency in the definition of postoperative infection. In this section, we define postoperative infection as the presence of purulent drainage (either spontaneously or by incision) or fistula in the operative region, together with pain or tenderness, localized swelling, redness, or fever (>38°C). Early infection is defined as infection occurring within 1 week postoperatively, and late infection, as infection occurring from 1 week postoperatively to the time of abutment connection (3–8 months postoperatively).⁷³ It is believed that bacterial contamination during implant insertion can cause early failure of the dental implant. Contamination of the implant surface by bacterial biofilms during operative procedures can lead to an inflammatory process in the hard and soft tissues, thus decreasing the implant success rate. Infections around biomaterials are very difficult to treat and nearly all infected implants may fail at some time after placement.

Nerve injury

Injuries to the inferior alveolar nerve and, less frequently, the lingual nerve have been reported and are

of concern when posterior mandibular implants are placed. Management of these injuries is predicated on the degree of nerve injury. Prevention can be simplified to careful preoperative planning. The readers are referred to the article by Drs Al-Sabbagh, Okeson, Khalaf and Bertolli elsewhere in this issue for more details about the management and prevention of these injuries.

Malpositioning of implants

Malpositioning of implants can occur during implant surgery and may be the result of a number of factors, such as the quantity or quality of residual available bone, dental inclinations adjacent to the surgical implant site, and lack of previous prosthodontic planning. Managing an implant that is poorly positioned may require a modified prosthetic attachment or surgical removal. The choice of treatment depends on the degree to which the poorly positioned implant will compromise the restorative plan.

Injury to adjacent teeth

When partially edentulous patients are treated, there is a risk of direct or indirect (thermal) injury to the roots of the adjacent teeth (Fig. 4)[74]. Depending on the severity of the injury, the tooth may be sensitive to cold and tender to percussion, and may cause mild discomfort when the patient is eating [75], although the injured tooth may respond normally to vitality tests. Treatment may involve extraction or endodontic treatment [76]. When an implant is in direct contact with an adjacent tooth, immediate removal of the implant may avoid major complications to the tooth. In some instances, implant removal may be accomplished with counter clockwise movement. In other instances, an internal device (Implant Retrieval Tool, Nobel Biocare, Kloten, Switzerland) can be used to unscrew the implant.

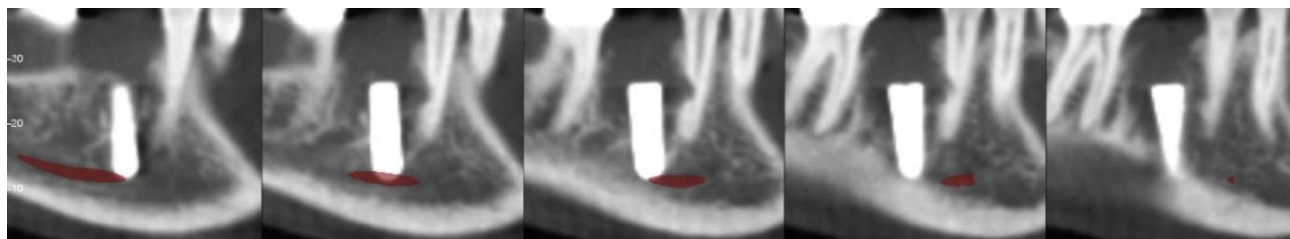


Fig-4: Cone beam images obtained 3 months after placement of an implant in a lower first molar site. The second bicuspid was sensitive to percussion

Screw fracture

Screw fracture during placement is closely related with insertion torque. Insertion torque of miniscrews generally ranges from 3 to 10 N cm, which is much smaller than the breaking torque disclosed by the manufacture's instruction [77, 78]. Therefore, majority of miniscrew fracture can be prevented by attending to their insertion torque. Screw fracture frequently occurs in the mandible where cortical bone

thickness is significantly thicker than the maxilla [79]. Screw insertion in the mid-palate also has a tendency of high insertion torque; therefore, the place 3 mm apart from the midpalatal suture is suitable for implantation avoiding excessive insertion torque [80]. Moreover, insertion torque might be enlarged when miniscrews are touched to the adjacent root. The miniscrew root proximity should be avoided for preventing screw fracture during screw insertion. Miniscrews are easily

removed with a screwdriver even though they are retained in the bone for more than a year during the active orthodontic treatment. We measured removal torque of orthodontic miniscrews and looked for the related factors affecting the torque. Sixty-eight screws placed with a self-tapping method and retained for more than 3 months were subjected (Absoanchor, Dentos Inc., Daegu, South Korea; diameter, 1.4 or 1.5 mm; length, 6–8 mm). The average removal torque was -

4.56 +/- -1.65 N cm (-1.74 N cm to -8.95 N cm). The removal torque showed no statistical significances between gender, screw length, screw diameter, jaw type, placement sites, and retention period. The breaking points of miniscrews used in the study was at least 20 N cm, therefore, the screws could be basically removed without fracture. However, screw fracture happens when osseointegration is completed (Fig.5).



Fig-5: A screw fractured at the removal. After the fracture, the tip of screw was carefully removed with a flap surgery

Indeed, some screws showed a partial osseointegration after removal. We have removed 191 miniscrews (Absoanchor; Dual-top auto screw, Jeil Co., Seoul, South Korea; Induce MS, Ortholution Co., Ltd., Seongnam, South Korea) in the latest three years and experienced one screw fracture (0.5%). Suzuki and Suzuki [81] removed 280 miniscrews with a diameter of 1.5 mm and reported four fractures (1.4%). Therefore, orthodontists always have to be aware of the possibility of screw fracture in removing procedure. Most fracture is occurred at the neck through cortical bone because mechanical stress in the miniscrew is concentrated at that point. To prevent the fracture, a screwdriver has to be turned slowly without changing the axis. If screw fracture unfortunately happens, the broken screw is tried to remove surgically. However, it is sometimes retained inside of alveolar bone to avoid excessive surgical invasion because of its biocompatibility.

CONCLUSION

This article has highlighted the potential complications for clinical usage of orthodontic anchor screws with the hope of educating clinicians. Clinicians should keep in mind that screw fracture will occur not only at placement but also at removal. All possible efforts need to be made for preventing screw fracture and failure. To reduce patient discomfort during implant-anchored orthodontics, a complicated placement surgery should be avoided and simple treatment mechanics is recommended. Miniscrews will give a better result if it is properly used.

REFERENCES

1. Sarul M, Minch L, Park HS, Antoszewska-Smith J. Effect of the length of orthodontic mini implants on their long-term stability: a prospective study. *Angle Orthod.* 2015;88:33-38.
2. Kuroda S, Sugawara Y, Deguchi T, Kyung HM, Takano-Yamamoto T. Clinical use of miniscrew implants as orthodontic anchorage: success rates and postoperative discomfort. *Am J Orthod Dentofacial Orthop.* 2007;131:9-15.
3. Miyawaki S, Koyama I, Inoue M, Mishima K, Sugahara T, Takano-Yamamoto T. Factors associated with the stability of titanium screws placed in the posterior region for orthodontic anchorage. *Am J Orthod Dentofacial Orthop.* 2003;124:373-8.
4. Cheng SJ, Tseng IY, Lee JJ, Kok SH. A prospective study of the risk factors associated with failure of mini-implants used for orthodontic anchorage. *Int J Oral Maxillofac Implants.* 2004;19:100-6.
5. Deguchi T, Takano-Yamamoto T, Kanomi R, Hartsfield JK Jr, Roberts WE, Garetto LP. The use of small titanium screws for orthodontic anchorage. *J Dent Res.* 2003;82:377-81.
6. Chuang SK, Cai T, Douglass CW, Wei LJ, Dodson TB. Frailty approach for the analysis of clustered failure time observations in dental research. *J Dent Res.* 2005;84:54-8.
7. Shapiro P, Kokich V. Uses of implants in orthodontics. *Dent Clin North Am.* 1988;32:539-50.

8. Cope JB. Temporary anchorage devices in orthodontics: a paradigm shift. *Semin Orthod.* 2005;11:3-9.
9. Reynders R, Ronchi L, Bipat S. Mini-implants in orthodontics: a systematic review of the literature. *Am J Orthod Dentofacial Orthop.* 2009;135:564.e1-19.
10. Kravitz ND, Kusnoto B. Risks and complications of orthodontic miniscrews. *Am J Orthod Dentofacial Orthop.* 2007;131:S43—51.
11. Suzuki EY, Suzuki B. Placement and removal torque values of orthodontic miniscrew implants. *Am J Orthod Dentofacial Orthop.* 2011;139:669—78.
12. Moon CH, Lee DG, Lee HS, Im JS, Baek SH. Factors associated with the success rate of orthodontic miniscrews placed in the upper and lower posterior buccal region. *Angle Orthod.* 2008;78:101—6.
13. Chen YJ, Chang HH, Huang CY, Hung HC, Lai EHH, Yao CCJ. A retrospective analysis of the failure rate of three different orthodontic skeletal anchorage systems. *Clin Oral Implants Res.* 2007;18:768—75.
14. Papageorgiou SN, Zogakis IP, Papadopoulos MA. Failure rates and associated risk factors of orthodontic miniscrewimplants: ametaanalysis. *Am J Orthod Dentofacial Orthop.* 2012;142:577—95.
15. Park HS, Jeong SH, Kwon OW. Factors affecting the clinical success of screw implants used as orthodontic anchorage. *Am J Orthod Dentofacial Orthop.* 2006;130:18—25.
16. Wu TY, Kuang SH, Wu CH. Factors associated with the stability of mini-implants for orthodontic anchorage: a study of 414 samples in Taiwan. *J Oral Maxillofac Surg.* 2009;67:1595—9.
17. Kuroda S, Sugawara Y, Deguchi T, Kyung HM, Takano-Yamamoto T. Clinical use of miniscrew implants as orthodontic anchorage: success rates and postoperative discomfort. *Am J Orthod Dentofacial Orthop.* 2007;131:9—15.
18. Cheng SJ, Tseng IY, Lee JJ, Kok SH. A prospective study of the risk factors associated with failure of mini-implants used for orthodontic anchorage. *Int J Oral Maxillofac Implants.* 2004;19:100—6.
19. Shah AH, Behrents RG, Kim KB, Kyung HM, Buschang PH. Effects of screw and host factors on insertion torque and pullout strength. *Angle Orthod.* 2012;82:603—10.
20. Ozdemir F, Tozlu M, Cakan DG. Cortical bone thickness of the alveolar process measured with cone-beam computed tomography in patients with different facial types. *Am J Orthod Dentofacial Orthop.* 2013;143:190—6.
21. Chen Y, Kyung HM, Gao L, Yu WJ, Bae EJ, Kim SM. Mechanical properties of self-drilling orthodontic microimplants with different diameters. *Angle Orthod.* 2010;80:821—7.
22. Lee NK, Baek SH. Effects of the diameter and shape of orthodontic mini-implants on microdamage to the cortical bone. *Am J Orthod Dentofacial Orthop.* 2010;138:e1—8.
23. Chen Y, Kyung HM, Zhao WT, Yu WJ. Critical factors for the success of orthodontic mini-implants: a systematic review. *Am J Orthod Dentofacial Orthop.* 2009;135:284—91.
24. Song YY, Cha JY, Hwang CJ. Mechanical characteristics of various orthodontic mini-screws in relation to artificial cortical bone thickness. *Angle Orthod.* 2007;77:979—85.
25. Kim JW, Baek SH, Kim TW, Chang YI. Comparison of stability between cylindrical and conical type mini-implants. *Angle Orthod.* 2008;78:692—8.
26. C,ehreli S,O" zc,ırpıcı AA. Primary stability and histomorphometric bone-implant contact of self-drilling and self-tapping orthodontic microimplants. *Am J Orthod Dentofacial Orthop.* 2012;141:187—95.
27. Chen Y, Shin HI, Kyung HM. Biomechanical and histological comparison of self-drilling and self-tapping orthodontic microimplants in dogs. *Am J Orthod Dentofacial Orthop.* 2008;133:44—50.
28. Motoyoshi M, Hirabayashi M, Uemura M, Shimizu N. Recommended placement torque when tightening an orthodontic mini-implant. *Clin Oral Implants Res.* 2006;17:109—14.
29. Wilmes B, Su YY, Drescher D. Insertion angle impact on primary stability of orthodontic mini-implants. *Angle Orthod.* 2008;78:1065—70.
30. Noble J, Karaiskos NE, Hassard TH, Hechter FJ, Wiltshire WA. Stress on bone from placement and removal of orthodontic miniscrews at different angulations. *J Clin Orthod.* 2009;43:332—4.
31. Lin TS, Tsai FD, Chen CY, Lind LW. Factorial analysis of variables affecting bone stress adjacent to the orthodontic anchorage mini-implant with finite element analysis. *Am J Orthod Dentofacial Orthop.* 2013;143:182—9.
32. Yadav S, Upadhyay M, Liu S, Roberts E, Neace WP, Nanda R. Microdamage of the cortical bone during mini-implant insertion with self-drilling and self-tapping techniques: a randomized controlled trial. *Am J Orthod Dentofacial Orthop.* 2012;141:538—46.
33. Kuroda S, Yamada K, Deguchi T, Hashimoto T, Kyung HM, Takano-Yamamoto T. Root proximity is a major factor for screw failure in orthodontic anchorage. *Am J Orthod Dentofacial Orthop.* 2007;131:S68—73.
34. Asscherickx K, Van de Vannet B, Wehrbein H, Sabzevar MM. Success rate of miniscrews relative to their position to adjacent roots. *Eur J Orthod.* 2008;30:330—5.
35. Jung YR, Kim SC, Kang KH, Cho JH, Lee EH, Chang NY, Chae JM. Placement angle effects on the success rate of orthodontic microimplants and other factors with cone-beam computed

- tomography. *American Journal of Orthodontics and Dentofacial Orthopedics*. 2013 Feb 1;143(2):173-81.
36. Lee KJ, Joo E, Kim KD, Lee JS, Park YC, Yu HS. Computed tomographic analysis of tooth-bearing alveolar bone for orthodontic miniscrew placement. *Am J Orthod Dentofacial Orthop*. 2009;135:486–94.
 37. Motoyoshi M, Ueno S, Okazaki K, Shimizu N. Bone stress for a mini-implant close to the roots of adjacent teeth—3D finite element analysis. *Int J Oral Maxillofac Surg*. 2009;38:363-8.
 38. Yu WJ, Kim MR, Park HS, Kyung HM, Kwon OW. Finite element analysis of peri-implant bone stresses induced by root contact of orthodontic microimplant. *Korean J Orthod*. 2011;41:6-15.
 39. Chen YH, Chang HH, Chen YJ, Lee D, Chiang HH, Jane Yao CC. Root contact during insertion of miniscrews for orthodontic anchorage increases the failure rate: an animal study. *Clinical oral implants research*. 2008 Jan 1;19(1):99-106.
 40. Asscherickx K, Vannet BV, Wehrbein H, Sabzevar MM. Root repair after injury from mini-screw. *Clin Oral Implants Res*. 2005;16:575-8.
 41. Lee YK, Kim JW, Baek SH, Kim TW, Chang YI. Root and bone response to the proximity of a miniimplant under orthodontic loading. *Angle Orthodontist*. 2010 May;80(3):452-8.
 42. Rooban T, Krishnaswamy NR, Mani K, Kalladka G. Root damage and repair in patients with temporary skeletal anchorage devices. *American Journal of Orthodontics and Dentofacial Orthopedics*. 2012 May 31;141(5):547-55.
 43. Brisceno CE, Rossouw PE, Carrillo R, Spears R, Buschang PH. Healing of the roots and surrounding structures after intentional damage with miniscrew implants. *American Journal of Orthodontics and Dentofacial Orthopedics*. 2009 Mar 31;135(3):292-301.
 44. Hembree M, Buschang PH, Carrillo R, Spears R, Rossouw PE. Effects of intentional damage of the roots and surrounding structures with miniscrew implants. *American Journal of Orthodontics and Dentofacial Orthopedics*. 2009 Mar 31;135(3):280-e1.
 45. Kadioglu O, Büyükyılmaz T, Zachrisson BU, Maino BG. Contact damage to root surfaces of premolars touching miniscrews during orthodontic treatment. *American Journal of Orthodontics and Dentofacial Orthopedics*. 2008 Sep 30;134(3):353-60.
 46. Maino BG, Weiland F, Attanasi A, Zachrisson BU, Buyukyilmaz T. Root damage and repair after contact with miniscrews. *Journal of Clinical Orthodontics*. 2007 Dec;41(12):762.
 47. Renjen R, Maganzini AL, Rohrer MD, Prasad HS, Kraut RA. Root and pulp response after intentional injury from miniscrew placement. *American Journal of Orthodontics and Dentofacial Orthopedics*. 2009 Nov 30;136(5):708-14.
 48. Motoyoshi M, Uemura M, Ono A, Okazaki K, Shigeeda T, Shimizu N. Factors affecting the longterm stability of orthodontic mini-implants. *American Journal of Orthodontics and Dentofacial Orthopedics*. 2010 May 31;137(5):588-e1.
 49. Asscherickx K, Vande Vannet B, Wehrbein H, Sabzevar MM. Success rate of miniscrews relative to their position to adjacent roots. *Eur J Orthod* 2008; 30: 330–335.
 50. Dao V, Renjen R, Prasad HS, Rohrer MD, Maganzini AL, Kraut RA. Cementum, pulp, periodontal ligament, and bone response after direct injury with orthodontic anchorage screws: a histomorphologic study in an animal model. *Journal of Oral and Maxillofacial Surgery*. 2009 Nov 30;67(11):2440-5.
 51. Kang YG, Kim JY, Lee YJ, Chung KR, Park YG. Stability of mini-screws invading the dental roots and their impact on the paradental tissues in beagles. *The Angle orthodontist*. 2009 Mar;79(2):248-55.
 52. Kuroda S, Yamada K, Deguchi T, Hashimoto T, Kyung HM, Yamamoto TT. Root proximity is a major factor for screw failure in orthodontic anchorage. *American Journal of Orthodontics and Dentofacial Orthopedics*. 2007 Apr 30;131(4):S68-73.
 53. Min K, Kim S, Kang S. Root proximity and cortical bone thickness effects on the success rate of orthodontic micro-implants using cone-beam computed tomography. *Angle Orthod* 2012; 82: 1014–1021.
 54. Wilmes B, Su YY, Sadigh L, Drescher D. Predrilling force and insertion torques during orthodontic miniimplant insertion in relation to root
 55. Kuroda S, Sugawara Y, Deguchi T, Kyung HM, Takano-Yamamoto T. Clinical use of miniscrew implants as orthodontic anchorage: success rates and postoperative discomfort. *Am J Orthod Dentofacial Orthop* 2007;131:9—15.
 56. Kawaguchi M, Miyazawa K, Tabuchi M, Fuyamada M, Goto S. Questionnaire survey on pain and discomfort after insertion of orthodontic buccal miniscrews, palatal miniscrews and, orthodontic miniplates. *Orthod Waves* 2014;73:1—7.
 57. Wehrbein H, Merz BR, Diedrich P, Glatzmaier J (1996) The use of palatal implants for orthodontic anchorage. Design and clinical application of the orthosystem. *Clin Oral Implants Res* 7, 410-416.
 58. Wehrbein H, Merz BR, Diedrich P (1999) Palatal bone support for orthodontic implant anchorage--a clinical and radiological study. *Eur J Orthod* 21, 65-70.
 59. Kyung SH, Hong SG, Park YC (2003) Distalization of maxillary molars with a midpalatal miniscrew. *J Clin Orthod* 37, 22-26.
 60. Henriksen B, Bavitz B, Kelly B, Harn SD (2003) Evaluation of bone thickness in the anterior hard

- palate relative to midsagittal orthodontic implants. *Int J Oral Maxillofac Implants* 18, 578-581.
61. Nienkemper M, Santel N, Hönscheid R, Drescher D (2016) Orthodontic mini-implant stability at different insertion depths: sensitivity of three stability measurement methods. *J Orofac Orthop* 77, 296-303.
 62. Kim YH, Yang SM, Kim S, Lee JY, Kim KE, Gianelly AA et al. (2010) Midpalatal miniscrews for orthodontic anchorage: factors affecting clinical success. *Am J Orthod Dentofacial Orthop* 137, 66-72.
 63. Poon YC, Chang HP, Tseng YC, Chou ST, Cheng JH, Liu PH, Pan CY. Palatal bone thickness and associated factors in adult miniscrew placements: A cone-beam computed tomography study. *The Kaohsiung journal of medical sciences*. 2015 May 1;31(5):265-70.
 64. Raghoobar GM, van Weissenbruch R, Vissink A. Rhino-sinusitis related to endosseous implants extending into the nasal cavity. A case report. *Int J Oral Maxillofac Surg*. 2004; 33, 312-314.
 65. Hsu CH, Wang HW. Quasineoplastic lesion in the nasal cavity caused by a dental implant. *J Med Sci*. 2009; 29, 33-34.
 66. Wehrbein H, Bauer W, Wessing G, Diedrich P. The effect of the maxillary sinus floor on orthodontic tooth movement. *Fortschr Kieferorthop*. 1990;51:345-51.
 67. Wehrbein H, Fuhrmann RA, Diedrich PR. Human histologic tissue response after long-term orthodontic tooth movement. *Am J Orthod Dentofacial Orthop*. 1995;107:360-71.
 68. Daimaruya T, Takahashi I, Nagasaka H, Umemori M, Sugawara J, Mitani H. Effects of maxillary molar intrusion on the nasal floor and tooth root using the skeletal anchorage system in dogs. *Angle Orthod*. 2003;73:158-66.
 69. Kuroda S, Wazen R, Moffatt P, Tanaka E, Nanci A. Mechanical stress induces bone formation in the maxillary sinus in a shortterm mouse model. *Clin Oral Invest*. 2013;17:1317.
 70. Cheng SJ, Tseng IY, Lee JJ, Kok SH. A prospective study of the risk factors associated with failure of mini-implants used for orthodontic anchorage. *Int J Oral Maxillofac Implants*. 2004;19:100–6.
 71. Parnia F, Fard EM, Marboub F. Tomographic volume evaluation of submandibular fossa in patients requiring dental implants. *Oral Surg Oral Med Oral Pathol Oral Radiol Endod*. 2010;109:32–6.
 72. Niamtu J 3rd. Near-fatal airway obstruction after routine implant placement. *Oral Surg Oral Med Oral Pathol Oral Radiol Endod*. 2001;92:597–600.
 73. Woo BM, Al-Bustani S, Ueeck BA. Floor of mouth haemorrhage and lifethreatening airway obstruction during immediate implant placement in the anterior mandible. *Int J Oral Maxillofac Surg*. 2006;35:961–4.
 74. Tarakji B, Nassani MZ. Factors associated with hematoma of the floor of the mouth after placement of dental implants. *Saudi Dent J*. 2012;24:11–5.
 75. Gynther GW, Köndell PÅ, Moberg LE, Heimdahl A. Dental implant installation without antibiotic prophylaxis. *Oral Surgery, Oral Medicine, Oral Pathology, Oral Radiology, and Endodontology*. 1998 May 1;85(5):509-11.
 76. Dao V, Renjen R, Prasad HS, Rohrer MD, Maganzini AL, Kraut RA. Cementum, pulp, periodontal ligament, and bone response after direct injury with orthodontic anchorage screws: a histomorphologic study in an animal model. *Journal of Oral and Maxillofacial Surgery*. 2009 Nov 1;67(11):2440-5.
 77. Margelos JT, Verdelis KG. Irreversible pulpal damage of teeth adjacent to recently placed osseointegrated implants. *J Endod*. 1995;21(9):479–82.
 78. Motoyoshi M, Hirabayashi M, Uemura M, Shimizu N. Recommended placement torque when tightening an orthodontic mini-implant. *Clin Oral Implants Res*. 2006;17:109-14.
 79. Meursing Reynders RA, Ronchi L, Ladu L, van Etten-Jamaludin F, Bipat S. Insertion torque and success of orthodontic miniimplants: a systematic review. *Am J Orthod Dentofacial Orthop*. 2012;142:596-614.
 80. Lee KJ, Joo E, Kim KD, Lee JS, Park YC, Yu HS. Computed tomographic analysis of tooth-bearing alveolar bone for orthodontic miniscrew placement. *Am J Orthod Dentofacial Orthop*. 2009;135:486-94.
 81. Kang S, Lee SJ, Ahn SJ, Heo MS, Kim TW. Bone thickness of the palate for orthodontic mini-implant anchorage in adults. *Am J Orthod Dentofacial Orthop*. 2007;131:S74-81.