

## Bladder Metastasis of Breast Cancer: A Case Report and Review

Lamia Aalaoui<sup>1\*</sup>, Anouar Mokhlis<sup>1</sup>, Mohamed Reda Khmamouche<sup>1</sup>, RachidTanz<sup>1</sup>, Hassan Errihani<sup>2</sup>, Mohamed Ichou<sup>1</sup>

<sup>1</sup>Medical Oncology Department, Military Hospital Mohammed V, Rabat, Morocco

<sup>2</sup>Medical Oncology Department, National Institute of Oncology Sidi Mohamed Ben Abdellah, Rabat, Morocco

DOI: [10.36347/sjmc.2022.v10i02.011](https://doi.org/10.36347/sjmc.2022.v10i02.011)

| Received: 29.12.2021 | Accepted: 09.02.2022 | Published: 13.02.2022

\*Corresponding author: Lamia Aalaoui

Medical Oncology Department, Military Hospital Mohammed V, Rabat, Morocco

### Abstract

### Case Report

Breast cancer is the most frequently diagnosed malignancy in women in Morocco. The most common sites for breast cancer metastasis includes lungs, liver, lymphatic nodes, bones, and brain and skin while other organs are less frequently involved. We describe a rare case of a patient with breast cancer who presented with urinary bladder metastasis as a late complication of her illness.

**Keywords:** Breast, cancer, bladder, metastasis.

Copyright © 2022 The Author(s): This is an open-access article distributed under the terms of the Creative Commons Attribution 4.0 International License (CC BY-NC 4.0) which permits unrestricted use, distribution, and reproduction in any medium for non-commercial use provided the original author and source are credited.

## INTRODUCTION

Breast cancer (BrC) is the most common and deadliest cancer in women. More than 2.2 million cases of breast cancer were reported in 2020 according to the World Health Organization (WHO). The highest mortality rate is observed in Africa and Polynesia. Its poor prognosis is related to its metastatic profile. Most often, metastases preferentially colonize the bones, but also the liver, the lungs and the brain as well as the lymph nodes and the skin. Urinary bladder and retroperitoneum involvement remains exceptional [1]. In most instances, bladder metastases from BrC are associated with other metastatic involvement of pelvic organ with a very poor survival [2, 3].

## CASE REPORT

We present a clinical case of a 61-year-old woman with a negative family history of BrC who has left breast cancer treated by radical mastectomy in February 2017. Pathology revealed a lobular carcinoma classified pT2N3M0, with estrogen receptor positive (ER=50%) and progesterone receptor positive (ER=40%), proliferative index (Ki67/MIB-1) was high (30%) and HER2/neu status was negative. The patient received six cycles of adjuvant chemotherapy, three courses of doxorubicin and cyclophosphamide supplemented by weekly paclitaxel for twelve weeks and locoregional radiotherapy. She also received hormonal treatment with inhibitor of aromatase.

She was treated with letrozole until July 2018, when she developed diffuse bone metastases without any visceral crisis. She received palbociclib, an inhibitor of CDK4/6 associated with fulvestrant and bisphosphonates. In June 2021, the abdominal scan revealed liver metastases. The patient received gemcitabine associated with oxaliplatin with good overall tolerance. When she had completed six cycles of therapy, she was switched to anastrozole-based hormonal therapy as maintenance treatment.

Our patient remained in good control until december 2021 when she presented hematuria with increasing creatinine in the blood test.

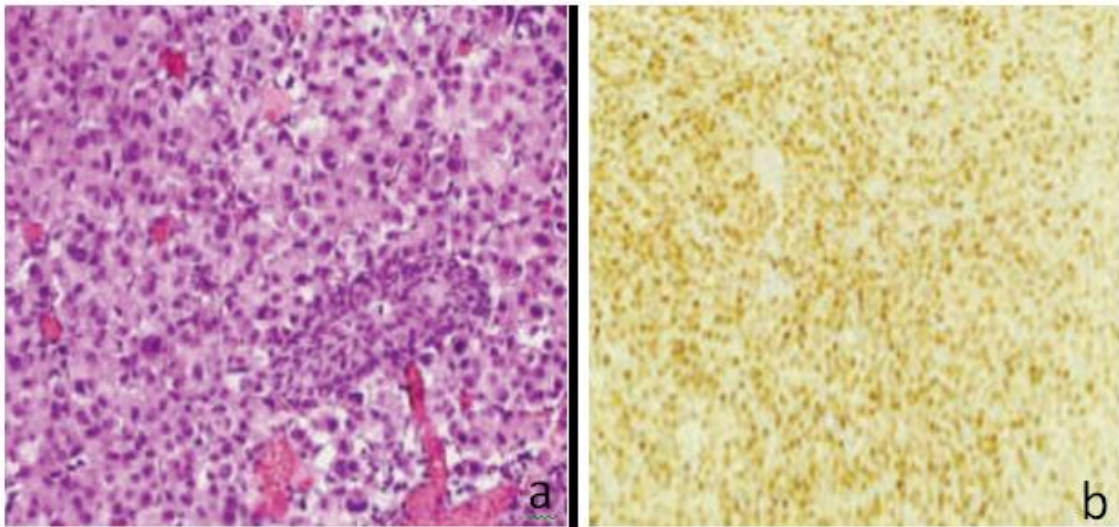
Abdominal CT scan displayed thickening of the posterior-left bladder wall with bilateral grade-I-II hydronephrosis. Cystoscopy showed inflammatory changes and suspicious bladder wall thickening.

The results of the biopsy confirmed the presence of a bladder metastasis from a lobular carcinoma of the breast with the same immunohistochemical profile (positive hormone receptors and negative HER 2 status) (Figure 1).

Our patient underwent bilateral JJ catheterization with improved renal function. A recent positron emission tomography scan revealed no additional sites of visceral metastasis. At the time of writing this manuscript, our patient is undergoing

metronomic navelbine chemotherapy with good overall

tolerance.



**Figure 1: a) Metastatic breast carcinoma cells infiltrating the urinary bladder (hematoxylin-eosin (200x); b) Immunohistochemical staining is positive for the estrogen receptor in neoplastic cells, however the transitional epithelium of the urinary bladder is completely negative. (30x)**

## DISCUSSION

Secondary bladder tumors are extremely rare, often due to direct extension of another pelvic neoplasm [4]. Exceptionally in relation to a lymphoma or a solid tumor such as lung cancer, breast cancer or melanoma.

Possible mechanisms are vascular and lymphatic dissemination or direct retroperitoneal invasion [5]. However, solitary bladder metastases have also been described [6, 7].

To date, fewer than 60 cases of BrC metastasis to the bladder have been reported in the literature [3], most often in a multi-metastatic setting.

It should be kept in mind that bladder metastases are late complications in the history of the primary disease [8].

Urinary symptomatology is correlated with the degree of bladder infiltration by the tumor. Massive infiltration is responsible for obstruction, gross hematuria, or signs of bladder irritation, which explains the low incidence of diagnosed bladder metastases [9].

As in our case, the most common histological subtype associated with bladder metastases is invasive lobular carcinoma [10].

Cystoscopy is essential for confirmation of the diagnosis. In majority of the case reports, it is revealed large tumor deposits as was found in our patient described above [11].

Histology and immunohistochemistry, including staining for ER and PR as well as HER2, are

indisputable in confirming to exclude a primary bladder cancer.

Discordance of hormone status between primary and metastatic sites has, however, been reported to be approximately 24 and 39% [12].

Chemotherapy and hormonal therapy are the mainstays of management, with radiation therapy used to control bleeding.

Ureteric stenting may also be indicated for those with hydronephrosis and renal dysfunction.

The prognosis for bladder-involved breast cancer is poor, with an average survival of 2 to 3 years [10].

## CONCLUSION

Bladder metastases of breast cancer are very rare, but their number has increased in recent years due to improved imaging and diagnostic techniques. They are manifested in most cases by hematuria and renal dysfunction, sometimes they can be asymptomatic.

They are more frequent in cases of invasive lobular carcinoma, and appear late, indicating an unfavorable evolution of the initial mammary pathology.

## Abbreviations

BrC: Breast cancer

ER: Estrogen receptor

PR: Progesterone receptor

HER 2: human epidermal growth factor receptor 2

### Conflict of Interests

The authors declare that there is no conflict of interests regarding the publication of this paper.

### REFERENCES

1. Shah, K. G., Modi, P. R., & Rizvi, J. (2011). Breast carcinoma metastasizing to the urinary bladder and retroperitoneum presenting as acute renal failure. *Indian journal of urology: IJU: journal of the Urological Society of India*, 27(1), 135-136.
2. Velcheti, V., & Govindan, R. (2007). Metastatic cancer involving bladder: a review. *Canadian Journal of Urology*, 14(1), 3443-3448.
3. Sanguedolce, F., Landriscina, M., Ambrosi, A., Tartaglia, N., Cianci, P., Di Millo, M., ... & Cormio, L. (2018). Bladder metastases from breast cancer: managing the unexpected. A systematic review. *Urologia Internationalis*, 101(2), 125-131.
4. Cormio, L., Sanguedolce, F., Di Fino, G., Massenio, P., Liuzzi, G., Ruocco, N., ... & Carrieri, G. (2014). Asymptomatic bladder metastasis from breast cancer. *Case Reports in Urology*, 2014, 672591.
5. Feldman, P. A., Madeb, R., Naroditsky, I., Halachmi, S., & Nativ, O. (2002). Metastatic breast cancer to the bladder: a diagnostic challenge and review of the literature. *Urology*, 59(1), 138.
6. Lin, W. C., & Chen, J. H. (2007). Urinary bladder metastasis from breast cancer with heterogeneous expression of estrogen and progesterone receptors. *Journal of Clinical Oncology*, 25(27), 4308-4310.
7. Mostofi, F. K., Thomson, R. V., & Dean, A. L. (1955). Mucous adenocarcinoma of the urinary bladder. *Cancer*, 8(4), 741-758.
8. Zagha, R. M., & Hamawy, K. J. (2007, May). Solitary breast cancer metastasis to the bladder: an unusual occurrence. In *Urologic Oncology: Seminars and Original Investigations* (Vol. 25, No. 3, pp. 236-239). Elsevier.
9. Ramsey, J., Beckman, E. N., & Winters, J. C. (2008). Breast cancer metastatic to the urinary bladder. *Ochsner Journal*, 8(4), 208-212.
10. Gennari, A., Conte, P., Rosso, R., Orlandini, C., & Bruzzi, P. (2005). Survival of metastatic breast carcinoma patients over a 20-year period: A retrospective analysis based on individual patient data from six consecutive studies. *Cancer*, 104(8), 1742-1750.
11. Wong, M. H., Yiu, M. K., & Ho, K. L. (2013). Metastatic carcinoma of breast in the urinary bladder. *Hong Kong Med J*, 19(5), 455-457.
12. Yoneyama, K., Nakagawa, M., & Hara, A. (2018). Bladder metastasis from primary breast cancer: a case report. *Surgical Case Reports*, 4(1), 1-3.