

## Hypertensive Workup Leading to the Discovery of Hepatic Sarcoidosis

A. Zbitou<sup>1\*</sup>, R. Zerhoudi<sup>1</sup>, Z. Chahbi<sup>2</sup>, A. Bouzerda<sup>1</sup>, A. Khatouri<sup>1</sup>

<sup>1</sup>Cardiology Department, Avicenne Military Hospital – Marrakech

<sup>2</sup>Internal Medicine Department, Avicenne Military Hospital – Marrakech

DOI: [10.36347/sjmcr.2022.v10i06.011](https://doi.org/10.36347/sjmcr.2022.v10i06.011)

| Received: 12.04.2022 | Accepted: 25.05.2022 | Published: 08.06.2022

\*Corresponding author: A. Zbitou

Cardiology Department, Avicenne Military Hospital – Marrakech

### Abstract

### Case Report

**Introduction:** Sarcoidosis is a systemic disease of unknown etiology that affects many organs, including the liver. It is usually asymptomatic and manifests as nonspecific biological disturbances. It is characterized by the presence of granulomatous, non-caseating lesions in the affected organs. Although it is most often revealed by mediastinal-thoracic involvement, such as pulmonary infiltrates or mediastinal adenopathies, or by skin and eye involvement, liver involvement is an infrequent site. **Objectif:** To report the case of a young man, presenting with high blood pressure figures, who consulted for etiological assessment of arterial hypertension which was at the origin of a rare form of sarcoidosis. **Case report:** The patient was 49 years old and had recently discovered hypertension as a cardiovascular risk factor, with no particular pathological history. On admission, the patient reported a 16 kg weight loss with anorexia. Biologically, hepatic cytolysis was noted with the presence of cholestasis with GGT and PAL at twice the normal level. The bilirubin level was normal. The rest of the workup, hydrolytic, protein, renal blood and urine, as well as the hemogram were without abnormality. The etiological workup of this cytolysis was negative for viral serology, and the immunological workup for chronic liver disease was negative. While the dosage of angiotensin converting enzyme was high at 93.8 units per liter. On the imaging plan, the abdominal ultrasound was normal, a complement by abdominal scanner found a slightly heterogeneous aspect of the right liver with a coelio-mesenteric ganglion of 27x13 mm, the abdominal MRI made objectified. In view of this, we indicated that a liver biopsy should be performed for etiological purposes and to evaluate the fibrosis. The anatomopathological examination was in favor of a gigantocellular epithelioid granuloma without caseous necrosis evoking sarcoidosis. **Discussion and conclusion:** Liver involvement in sarcoidosis is histologically frequent; however, it is usually clinically latent and biological disturbances are present in only 20% of cases. It should be investigated as a matter of principle in all cases of systemic sarcoidosis by clinical examination, routine liver function tests and imaging. Liver biopsy, which is not without complications, should only be performed in the presence of liver biology disturbances in order to demonstrate histological lesions suggestive of sarcoidosis and to indicate possible corticosteroid therapy. The severity of liver damage depends essentially on the occurrence of complications such as portal hypertension. Treatment is not systematic and is essentially based on corticosteroid therapy; its indication depends on the evolution of the hepatic involvement and the other locations of the disease, but its effectiveness on the evolutionary course of this location has not been clearly evaluated.

**Keywords:** High blood pressure, Sarcoidosis, Liver, Granuloma, Cholestasis, Treatment, Prognosis.

**Copyright © 2022 The Author(s):** This is an open-access article distributed under the terms of the Creative Commons Attribution 4.0 International License (CC BY-NC 4.0) which permits unrestricted use, distribution, and reproduction in any medium for non-commercial use provided the original author and source are credited.

## INTRODUCTION

Sarcoidosis is a systemic disease of unknown etiology that affects many organs, including the liver. It is usually asymptomatic and manifests as nonspecific biological disturbances [1].

It is characterized by the presence of granulomatous, non-caseating lesions in the affected organs. Although it is most often revealed by mediastinal-thoracic involvement, such as pulmonary

infiltrates or mediastinal adenopathies, or by skin and eye involvement, liver involvement is an infrequent site [2]. Whatever the clinical form, it is the histological examination and the discovery of the sarcoid granuloma that allow the diagnosis to be confirmed. In forms that do not threaten either organ function or vital prognosis, therapeutic abstention is the rule. Evidence based guidelines for treatment of liver sarcoidosis is lacking and the effect of corticosteroids may be inadequate [3].

**Citation:** A. Zbitou, R. Zerhoudi, Z. Chahbi, A. Bouzerda, A. Khatouri. Hypertensive Workup Leading to the Discovery of Hepatic Sarcoidosis. Sch J Med Case Rep, 2022 Jun 10(6): 542-546.

Our objectif is to report the case of a young man, presenting with high blood pressure figures, who consulted for etiological assessment of arterial hypertension which was at the origin of a rare form of sarcoidosis.

## CASE REPORT

The patient was 49 years old, Caucasian, with recent hypertension as a cardiovascular risk factor, and without any particular pathological history.

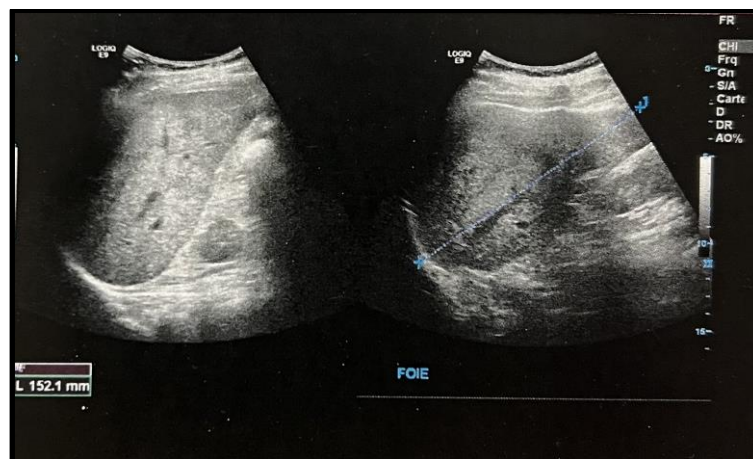
On admission, the patient had no functional cardiovascular or neurosensory signs. He reported a weight loss of 16 kg with anorexia.

Biologically, the renal and urinary hydroelectrolytic balance, the inflammatory balance, and the hemogram were without abnormality. In addition, the hepatic workup showed a hepatic cytolysis

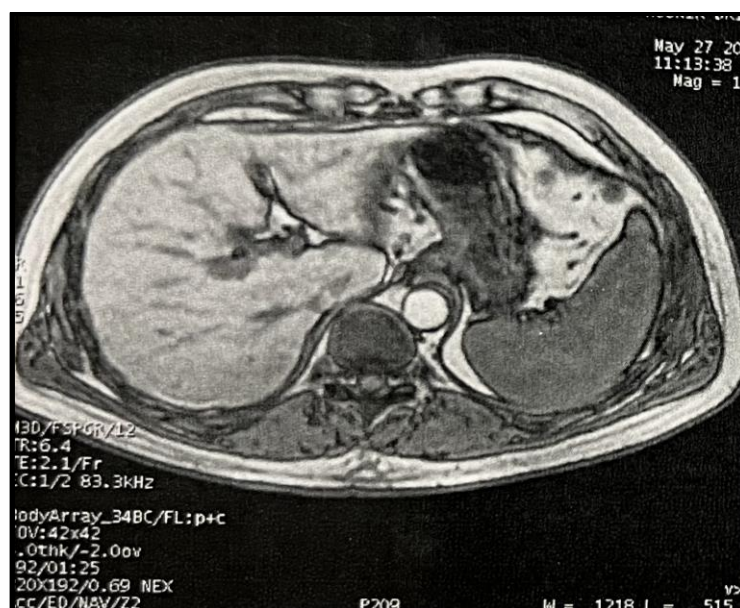
estimated at one and a half times normal for GOT and twice normal for GPT. Cholestasis was also present with GGT and PAL at two times normal. The bilirubin level was normal. The protein balance was without abnormality. Metabolically, the patient had hypertriglyceridemia.

The etiological work-up of this cytolysis revealed negative viral hepatitis B and C serologies, negative hepatitis D serology.

On imaging, abdominal ultrasound showed a chronic liver disease with adenopathy of the hepatic hilum without portal abnormality or suprahepatic veins (Figure 1). Complementary abdominal MRI revealed a slight hepatic dysmorphism without any detectable nodular or infiltrative formation, with a slightly heterogeneous appearance of the right liver with a coelio-mesenteric lymph node of 27x13 mm (Figure 2).



**Figure 1: Longitudinal section of the right liver showing a hepatomegaly (liver arrow at 15.21 cm) of heterogeneous appearance, with hyperechoic lesions**



**Figure 2: Hepatic MRI in T2 sequence, showing hepatic dysmorphism with irregular contours and hypertrophy of segment 1, and hypotrophy of segment 4**

The immunological work-up for chronic liver disease came back negative. The cupremia and cupruria were normal. While the dosage of angiotensin converting enzyme was high at 93.8 units per liter.

In front of this, we indicated the realization of the hepatic biopsy for etiological purpose and to evaluate the fibrosis. The anatomopathological examination was in favor of a gigantocellular epithelioid granuloma without caseous necrosis evoking sarcoidosis.

In this patient we retained the diagnosis of isolated hepatic sarcoidosis since the sarcoidosis mapping came back negative, namely a normal ophthalmological examination and thoracic CT scan. Regarding the cardiac extension, the patient had no rhythm or conduction disorders on ECG, and a transthoracic echocardiography came back normal. The PET scan was not performed because it was not available in our training. The physiological workup was negative. Arterial hypertension was considered essential.

Therapeutically we put the patient on ursodeoxycholic acid, a dose of 3 tablets per day.

The evolution was favorable both clinically and paraclinically, the patient reported an improvement in asthenia and a weight gain of 5 kg. Biologically, the hepatic balance was normalized after 3 months of treatment, the angiotensin converting enzyme remained high at 80 units per liter.

For his blood pressure problem, the patient was put on a calcium channel blocker 5 mg per day associated with hygienic and dietary measures for his dyslipidemia.

## DISCUSSION

Sarcoidosis or Besnier-Boeck-Shaumann disease (BBS) is a systemic disease of unknown etiology characterized by the presence of non-caseating granulomatous lesions in the affected organs. Liver involvement is an uncommon localization, found in 50% of liver biopsies in systemic sarcoidosis. It is usually asymptomatic and rarely reveals the disease [4].

Incidental discovery during abdominal surgery has already been reported by Devaney *et al.*, who, in their series of 100 patients, reported 11 cases of sarcoidosis diagnosed during surgical liver biopsies performed during surgery for biliary lithiasis or cholecystitis [5]. Liver involvement is more frequently diagnosed during the workup of known sarcoidosis; in the retrospective study by Chapelon *et al.*, of 416 patients with sarcoidosis who underwent 618 biopsies of various sites, including 90 liver biopsies, the sensitivity of liver biopsy was 69% [6].

Most often, liver involvement is asymptomatic. The prevalence of clinical signs is estimated at 12% of cases [7]. Abdominal pain was found in 15% of cases in the series of 100 patients by Devaney *et al.*, [5]. Fever is rare in sarcoidosis. The presence of jaundice is considered a poor prognostic factor [5].

Hepatomegaly is frequently found in hepatic sarcoidosis. The hepatic biological balance is disturbed in 20% of cases of sarcoidosis. It is frequently an anicteric cholestasis during which the presence of granulomas is objectified in 40 to 70% of cases [7]. The characteristic histological involvement of the liver in sarcoidosis is, as in other organs, epithelioid and gigantocellular granuloma, with caseous necrosis being absent. Exceptionally, granulomas may be centered by fibrinoid or caseous necrosis in some multivisceral febrile florid sarcoidosis [7].

Imaging is of great value in the diagnosis of hepatic sarcoidosis. Abdominal ultrasound data are not specific but are useful in detecting liver involvement in sarcoidosis. In combination with ultrasound, CT shows homogeneous hepatomegaly in 29% of cases, small hepatic and splenic nodules, rarely calcified (5-15% of cases), rather hypodense [8]. Abdominal MRI may find hepatomegaly, hepatic nodules, irregularities of the portal vein or branches of the suprahepatic veins, and sometimes areas with a somewhat heterogeneous signal. On MRI, the nodular lesions are T1 and T2 hyposignal and are less enhanced than the rest of the liver parenchyma. These images are best seen in T2 sequence with fat saturation and in T1 sequence on early phases after gadolinium injection [9].

Cardiac involvement occurs in 5% to 20% of patients, depending on the series, and even in more than 25% of patients in autopsy series.

In sarcoidosis, cardiac involvement is symptomatic in only 3% to 5% of cases [6], whereas systematic autopsy studies show progressive lesions in 20% to 50% of cases [10]. This discrepancy is related to the lack of anatomic-clinical relationship. Most cardiac lesions will remain subclinical, but a complication such as sudden death secondary to a rhythm or conduction disorder is found in 30-65% of sarcoidosis deaths [11].

In recent years, progress has been made in terms of improved diagnostic performance using MRI and 18FDG positron emission tomography, as well as the importance of rhythmic risk stratification, which should lead to consideration of defibrillator implantation.

Complications of hepatic sarcoidosis such as portal hypertension and cirrhosis are rare, and secondary hepatopulmonary syndrome remains exceptional [12].



The differential diagnosis of hepatic sarcoidosis requires the elimination of granulomatosis of other etiology, in particular drug-induced, autoimmune, and particularly infectious viral or especially tuberculosis because of the risks associated with unjustified corticosteroid therapy [13].

Histological involvement alone does not imply the initiation of corticosteroid treatment, as hepatic and splenic localizations discovered incidentally on imaging may have a spontaneously favorable evolution [14]. Disturbances in the liver balance and the presence of extrahepatic manifestations that require treatment are decisive. Corticosteroid therapy usually leads to clinical, biological and radiological remission. However, the problem of prolonged corticosteroid treatment arises.

Synthetic antimalarials in combination with ursodeoxycholic acid have been used successfully in patients with corticosteroid-resistant liver disease [15]. The importance of TNF in granuloma formation has led to the proposal of this cytokine as a therapeutic target in sarcoidosis. Infliximab has been proposed in cases of sarcoidosis with hepatic localization refractory to corticoids. It seems to be beneficial on the clinical manifestations and not on the hepatic biological disturbances [16].

Immunosuppressive drugs are sometimes an alternative in case of high-dose corticoid dependence, but their toxicity remains problematic. Recourse to liver transplantation is exceptional and reserved for advanced liver cirrhosis complicated by hepatocellular insufficiency [17].

## CONCLUSION

Liver involvement in sarcoidosis is histologically frequent; however, it is usually clinically latent and biological disturbances are present in only 20% of cases. It should be investigated as a matter of principle in all cases of systemic sarcoidosis by clinical examination, routine liver function tests and imaging.

Liver biopsy, which is not without complications, should only be performed in the presence of liver biology disturbances in order to demonstrate histological lesions suggestive of sarcoidosis and to indicate possible corticosteroid therapy.

The severity of liver damage depends essentially on the occurrence of complications such as portal hypertension. Treatment is not systematic and is essentially based on corticosteroid therapy; its indication depends on the evolution of the hepatic involvement and the other locations of the disease, but its effectiveness on the evolutionary course of this location has not been clearly evaluated.

## BIBLIOGRAPHY

1. Kahi, C. J., Saxena, R., Temkit, M., Canlas, K., Roberts, S., Knox, K., ... & Kwo, P. Y. (2006). Hepatobiliary disease in sarcoidosis. *Sarcoidosis, Vasculitis, and Diffuse Lung Diseases: Official Journal of WASOG*, 23(2), 117-123.
2. Tazi, A., & Battesti, J. P. (1994). Expression clinique et paraclinique de la sarcoïdose médiastino-pulmonaire: Sarcoïdose. *La Revue du praticien (Paris)*, 44(15), 2025-2032.
3. Bakker, G. J., Haan, Y. C. L., de Buy Wenniger, L. M., & Beuers, U. (2012). Sarcoidosis of the liver: to treat or not to treat?. *Neth J Med*, 70(8), 349-356.
4. Hoefnagels, M. A., Van Leusen, R., & De Vries, R. A. (2003). Three patients with weight loss as a result of sarcoidosis presenting as liver disease. *Nederlandsche Tijdschrift voor Geneeskunde*, 147(50), 2453-2457.
5. Devaney, K., Goodman, Z. D., Epstein, M. S., Zimmerman, H. J., & Ishak, K. G. (1993). Hepatic sarcoidosis. Clinicopathologic features in 100 patients. *The American journal of surgical pathology*, 17(12), 1272-1280.
6. Chapelon, C., Piette, J., Uzzan, B., Coche, E., Herson, S., Ziza, J. M., ... & de Médecine Interne, S. N. F. (1987). Rentabilité des prélèvements histologiques au cours de la sarcoïdose: Analyse rétrospective multicentrique de 618 biopsies pratiquées chez 416 malades. *La Revue de médecine interne*, 8(2), 181-185.
7. Ganne-Carrie, N., Guettier, C., Ziol, M., Beaugrand, M., & Trinchet, J. C. (2001). Sarcoïdose et foie. *Ann Med Interne*, 152, 103-107.
8. Dupas, B., Gournay, J., Frampas, E., Leaute, F., & Le Borgne, J. (2006). Une cholestase anictérique: l'apport de l'imagerie au diagnostic étiologique. *Journal de Radiologie*, 87(4), 441-457.
9. Warshauer, D. M., Semelka, R. C., & Ascher, S. M. (1994). Nodular sarcoidosis of the liver and spleen: appearance on MR images. *Journal of Magnetic resonance imaging*, 4(4), 553-557.
10. Silverman, K. J., Hutchins, G. M., & Bulkley, B. H. (1978). Cardiac sarcoid: a clinicopathologic study of 84 unselected patients with systemic sarcoidosis. *Circulation*, 58(6), 1204-1211.
11. Perry, A., & Vuitch, F. (1995). Causes of death in patients with sarcoïdosis. *Arch Pathol Lab Med*, 119, 167-172.
12. Gupta, S., Faughnan, M. E., Prud'homme, G. J., Hwang, D. M., Munoz, D. G., & Kopplin, P. (2008). Sarcoidosis complicated by cirrhosis and hepatopulmonary syndrome. *Canadian respiratory journal*, 15(3), 124-126.
13. Drebber, U., Kasper, H. U., Ratering, J., Wedemeyer, I., Schirmacher, P., Dienes, H. P., & Odenthal, M. (2008). Hepatic granulomas: histological and molecular pathological approach to differential diagnosis—a study of 442 cases. *Liver International*, 28(6), 828-834.

14. Margery, J., Bonnichon, A., Vaylet, F., Bredin, C., L'Her, P., & de Revel, T. (2007). Spontaneous regression of hepatic and splenic involvements during sarcoidosis. *Revue de Pneumologie Clinique*, 63(2), 109-110.
15. Ayyala, U. S., & Padilla, M. L. (2006). Diagnosis and treatment of hepatic sarcoidosis. *Current treatment options in gastroenterology*, 9(6), 475-483.
16. Doty, J. D., Mazur, J. E., & Judson, M. A. (2005). Treatment of sarcoidosis with infliximab. *Chest*, 127(3), 1064-1071.
17. Tombazzi, C., Waters, B., Ismail, M. K., Sylvestre, P. B., Martinez-Hernandez, A., & Riely, C. A. (2008). Sarcoidosis mimicking primary sclerosing cholangitis requiring liver transplantation. *Annals of Hepatology*, 7(1), 83-86.