

## Abdominal Wall Endometriosis: A Rare Case Report

Dr. Jasmine Kaur<sup>1\*</sup>, Dr. Manmeet Kaur<sup>2</sup>, Dr. Aradhna<sup>3</sup>, Dr. Sukhleen Kaur<sup>1</sup>

<sup>1</sup>Junior Resident, Pathology Department, Government Medical College, Patiala, India

<sup>2</sup>Assistant Professor, Pathology Department, Government Medical College, Amritsar, India

<sup>3</sup>Assistant Professor, Pathology Department, Government Medical College, Patiala, India

DOI: [10.36347/sjmcr.2023.v11i03.001](https://doi.org/10.36347/sjmcr.2023.v11i03.001)

| Received: 10.01.2023 | Accepted: 23.02.2023 | Published: 02.03.2023

\*Corresponding author: Dr. Jasmine Kaur

Junior Resident, Pathology Department, Government Medical College, Patiala, India

### Abstract

### Case Report

**Introduction:** Endometriosis is presence of functioning endometrium outside uterus [1]. It rarely occurs in the abdominal wall. The diagnosis is confirmed by histopathological examination. We report a rare case of abdominal wall endometriosis in a 32 year old female who was managed at tertiary care center of Rajindra Hospital, Patiala.

**Keywords:** Endometriosis, abdominal wall, diagnosis, histopathological examination.

Copyright © 2023 The Author(s): This is an open-access article distributed under the terms of the Creative Commons Attribution 4.0 International License (CC BY-NC 4.0) which permits unrestricted use, distribution, and reproduction in any medium for non-commercial use provided the original author and source are credited.

## INTRODUCTION

Endometriosis is defined as occurrence of endometrial tissue outside the uterus. It is a major cause of pelvic pain and subfertility [1]. Abdominal wall endometriosis (AWE) is endometriotic infiltration in any segment or depth of the abdominal wall [2]. The diagnosis of endometriosis remains challenging due to its variable presentation [5]. The clinical diagnosis of AWE is confused with abscess, hematoma, suture granuloma, desmoid tumor, sarcoma and metastatic malignancy [4]. Treatment include surgical and/or hormonal therapies. Wide surgical excision is still the treatment of choice [1-6].

We report a case of 32 year old G3P1L1A1 with 38 weeks period of gestation with anterior wall endometriosis.

## CASE REPORT

A 32 year old female G3P1L1A1 with 38 weeks period of gestation presented with anterior wall mass. Ultrasonography was inconclusive and diagnosis was made on MRI, which revealed anterior abdominal wall endometriosis measuring 5x5 cm located on left side between rectus sheath and muscle layer. Surgery was done and diagnosis confirmed on histopathological examination. On gross Examination, two brown colored soft tissue pieces measuring 2.5x4 cm and 3.5x1.5 cm received. On cut section white areas appreciated. On microscopic examination, multiple sections examined from different areas show skeletal muscle on one side along with adipose tissue. Beneath this is present

mainly decidual stroma consisting of round to oval large decidual cells making lobular pattern separated by thin elongated cystic spaces which are lined by thin cuboidal epithelium. In focal areas, residual compressed endometrial glands with little stroma can be seen. There are areas of old haemorrhage and haemosiderin laden macrophages in lobules of decidualized stroma.

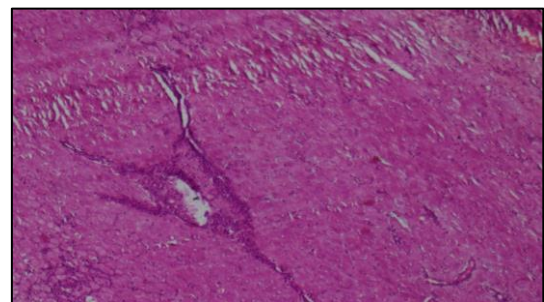


Figure 1: Shows 10 X view of the endometrial gland lying in decidualized stroma

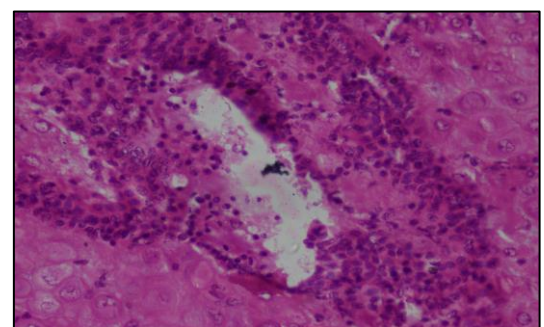
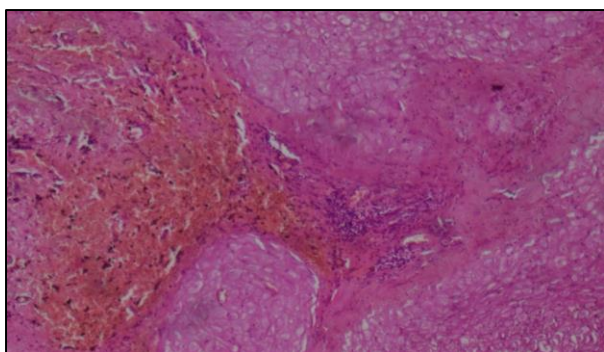


Figure 2: Shows 40 X view of the endometrial glands lying in decidualized stroma



**Figure 3: Shows 40 X view of areas of hemorrhage and hemosiderin laden macrophages lying in decidualized stroma**

## DISCUSSION

Endometriosis is defined as the presence of ectopic endometrial tissue outside the uterine cavity. It is classified as internal (within the uterine muscles) or external (in the pelvic organs and other parts of the body) according to the involvement of the uterine muscle layer [3]. Extrapelvic endometriosis is an uncommon disorder with a prevalence of 8.9–15%. It rarely involves bladder, kidney, omentum, bowel, lymph node, pleura, umbilicus, hernial sac and abdominal wall [5].

The precise etiology of endometriosis is unknown and various theories are linked to explain it including retrograde menstruation, coelomic metaplasia and embryogenic rest [4].

AWE is a very rare uncommon presentation. It is of two types spontaneous and secondary. Spontaneous AWE occurs in a scarless abdomen whereas Secondary AWE results from an obstetric or gynecological surgery, especially in caesarean sections. The reported incidence of AWE varies from 0.03 to 3.5%, and in caesarean scar is 0.03 to 0.45% [2].

As the clinical presentation is variable depending upon the site of endometriosis, the differential diagnosis should always be kept in mind if a reproductive age group women presents with scar site mass. USG, CT, MRI can aid the diagnosis but definite diagnosis is on postoperative histopathological

examination [6]. In cases of uncertainty on histopathological examination, CD10 immunohistochemical staining is used for definitive diagnosis [3]. Medical therapy including NSAIDs, oral contraceptives, gonadotropin releasing hormone analogues and aromatase inhibitors are used and show improvements in symptoms with no change in the lesion size. Thereby treatment of choice is wide local excision of the lesion with negative margins and treatment may sometimes require mesh placement [3]. Abdominal wall musculature involvement requires en bloc resection of the myofascial elements [5].

## CONCLUSION

We hereby report a rare case of anterior abdominal wall endometriosis in a 32 year old female who was managed at tertiary care centre of Rajendra Hospital Patiala.

## REFERENCES

- 1 Gilks, B. (2018). Uterus: Corpus. In: Goldblum, J. R., Lamps, L. W., eds. *Rosai and Akerman's Surgical Pathology*. 11th ed. USA : Elsevier, 1300-1303.
- 2 Benedetto, C., Cacoza, D., de Sousa Costa, D., Coloma Cruz, A., Tessmann Zomer, M., Cosma, S., ... & Kondo, W. (2022). Abdominal wall endometriosis: report of 83 cases. *International Journal of Gynecology & Obstetrics*, 159(2), 530-536.
- 3 Saliba, C., Jaafoury, H., El Hajj, M., Nicolas, G., & Ahmad, H. H. (2019). Abdominal wall endometriosis: a case report. *Cureus*, 11(2), e4061.
- 4 Agarwal, N., & Subramanian, A. (2010). Endometriosis-morphology, clinical presentations and molecular pathology. *Journal of laboratory physicians*, 2(01), 1-9.
- 5 Pathan, Z. A., Dinesh, U., & Rao, R. (2010). Scar endometriosis. *J Cytol*, 27(3), 106-108.
- 6 Carsote, M., Terzea, D. C., Valea, A., & Gheorghisan-Galateanu, A. A. (2020). Abdominal wall endometriosis (a narrative review). *International journal of medical sciences*, 17(4), 536-542.