

## Rectal Bleeding in a Child Revealing a Cavernous Hemangioma of the Sigmoid

Kenza El Hadri<sup>1\*</sup>, N. Yassine<sup>1</sup>, B. Zouita<sup>1</sup>, D. Basraoui<sup>1</sup>, H. Jalal<sup>1</sup><sup>1</sup>Department of Radiology, Mother and Child Hospital, CHU Mohammed VI of Marrakech, Faculty of Medicine and Pharmacy, Marrakech Cadi Ayad University, MoroccoDOI: [10.36347/sjmcr.2023.v11i03.015](https://doi.org/10.36347/sjmcr.2023.v11i03.015)

| Received: 11.01.2023 | Accepted: 20.02.2023 | Published: 13.03.2023

**\*Corresponding author:** Kenza El Hadri

Department of Radiology, Mother and Child Hospital, CHU Mohammed VI of Marrakech, Faculty of Medicine and Pharmacy, Marrakech Cadi Ayad University, Morocco

### Abstract

### Case Report

Hemangiomas are the most common benign vascular tumors in the pediatric age group. They originate from embryonic remnants of unipotent angioblastic cells. Although hemangiomas may occur anywhere within the abdomen, including the solid organs, hollow viscera, ligaments, and abdominal wall, the liver is the most common site. Cavernous hemangiomas of the sigmoid colon are uncommon vascular malformations usually found in young adults with a long history of episodic and painless rectal bleeding. Imaging plays an essential role in diagnosis and post-therapeutic follow-up. The diagnosis of certainty remains histological and the treatment is essentially surgical. We report a case of cavernous hemangioma of the sigmoid diagnosed in a 5-year-old boy admitted to our hospital for investigation of repeated episodes of rectal bleeding. The diagnosis was confirmed after a histological examination.

**Keywords:** Cavernous hemangioma, rectal bleeding, sigmoid, CT scan.**Copyright © 2023 The Author(s):** This is an open-access article distributed under the terms of the Creative Commons Attribution 4.0 International License (CC BY-NC 4.0) which permits unrestricted use, distribution, and reproduction in any medium for non-commercial use provided the original author and source are credited.

## INTRODUCTION

Hemangiomas are ubiquitous vascular neoplasms that may be found in virtually every human organ. They are benign tumors that arise from embryonic remnants of unipotent angioblastic cells [1]. Although hemangiomas may occur anywhere within the abdomen, including the solid organs, hollow viscera, ligaments, and abdominal wall, the liver is the most common site [2]. Colon and rectum hemangioma is a rare disease, and even more so when it presents as a cavernous subtype; few of these hemangiomas have been confirmed by pathology reports [3]. Typically, hemangiomas have a pathognomonic imaging appearance. However, unusual imaging features and atypical locations can present significant diagnostic dilemmas. The literature is replete with case reports of unusual and atypical hemangiomas that resulted in surgical excision, with the diagnosis established only at histopathology [2].

## CASE REPORT

We report the case of a 5-year-old male infant admitted to our hospital for investigation of recurrent episodes of rectal bleeding evolving for two months in

the context of apyrexia and conservation of general condition.

Abdominal examination revealed a huge painless abdominal mass in the hypogastric and left iliac regions.

Laboratory investigations showed hemoglobin of 7.6 g/dL, MCHC of 28.1 pg, CCMH of 34.4, and C reactive protein of 6.4 mg/L. Clotting times were normal with a TP of 99%. The rest of the parameters were within normal limits.

An abdominal ultrasound objectified a hypogastric mass measuring 60 x 50 mm seem to infiltrate the bowel wall, vascularized on color Doppler with multiple liver nodules.

To better characterize this mass and study its relationships, further exploration by abdominal CT scan with an injection of PDC was done and showed bowel-wall thickening with phleboliths seen at the sigmoid colon extending 68mm long with a maximum wall thickness of 59mm, spontaneously hypodense, heterogeneously enhanced after injection of PDC

(figure 1). The CT scan also showed well-defined hypodense nodules in the liver, which after contrast injection shows peripheral nodular enhancement with progressive centripetal homogeneous filling which can probably be related to hemangiomas (figure 2).

The patient was taken to surgery and the diagnosis of cavernous hemangioma of the sigmoid colon was confirmed in the pathology report.

CT scan of the abdomen and pelvis was performed during his follow-up and showed no evidence of local recurrence with a stable appearance of hepatic nodules (figure 3).

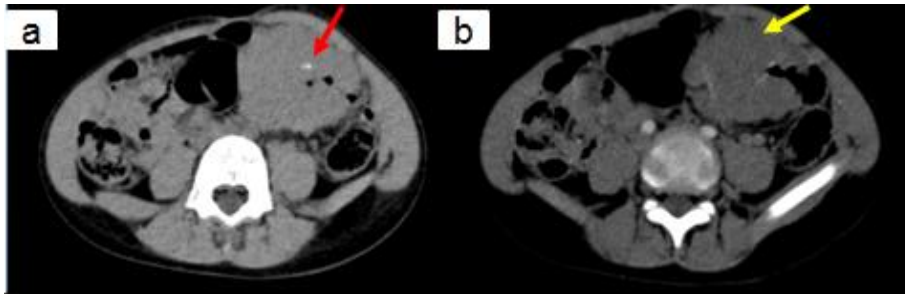


Figure 1: CT scan without (a) and with contrast (b) shows marked thickening of the sigmoid wall (yellow arrow) with phleboliths (red arrow)

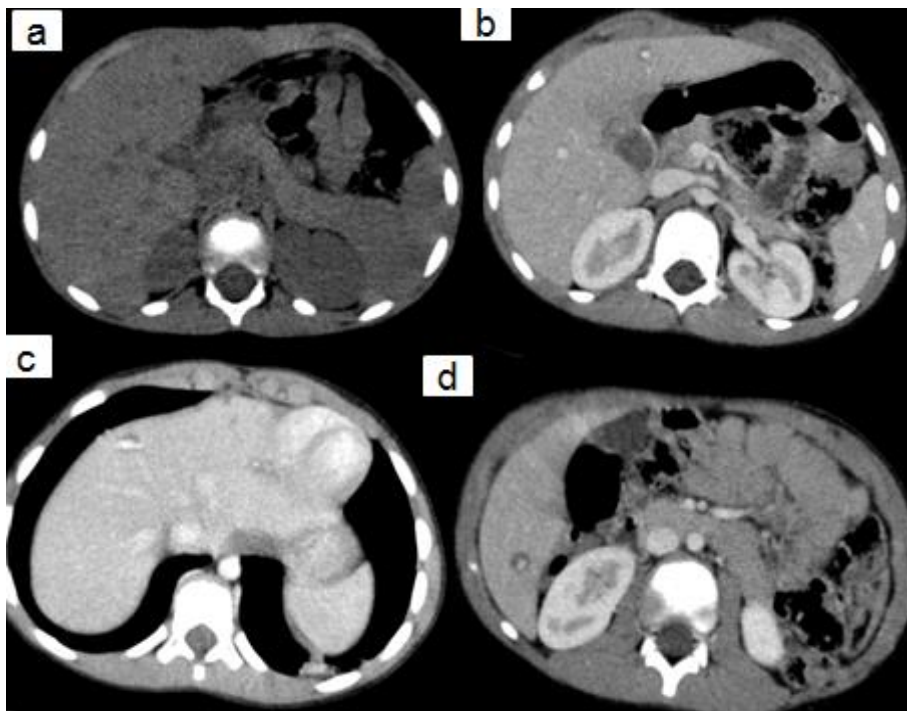


Figure 2: CT scan without (a) and with contrast (b,c and d) well-margined hypodense lesions with a peripheral nodular enhancement that matches the aorta at the arterial phase (c) and progressive centripetal filling on venous phase (b and d)

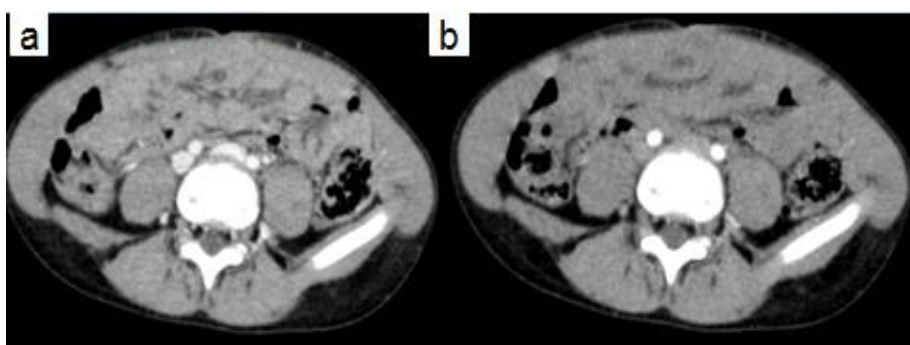


Figure 3: CT scan with contrast (a & b) after surgery showed no evidence of local recurrence

## DISCUSSION

Hemangiomas are ubiquitous benign vascular neoplasms that may be found in virtually every human organ [1, 4]. They are the most common benign vascular tumors of the pediatric age group; arise from embryonic remnants of unipotent angioblastic cells [4]. No sex predominance has been demonstrated [5].

Hemangiomas can appear in any organ, as single or multiple lesions and are characterized by rapid growth followed by involution in the first years of life. However, visceral hemangiomas occur most frequently in the liver [6]. Colon and rectum hemangioma is a rare disease, and even more so when it presents as the cavernous subtype [7].

There are three types of hemangiomas based on their predominant component: cavernous, capillary, and mixed hemangiomas. Cavernous hemangiomas are the most frequent [8, 9]. Thromboses frequently occur within the sinusoids resulting in subsequent calcification and then forming the so-called phleboliths, which are an important diagnostic feature [10, 11].

The main presentation of this disease is observed by transrectal painless bleeding with anemia [7]. Hemangiomas provide few exam findings. Distal lesions can be detected on digital examination, though these masses are not usually overt. These tumors are soft and compressible, with a nodular sensation. When large, a mass on abdominal examination can sometimes be palpated.

Colonoscopy is an invaluable tool, being both diagnostic and potentially therapeutic [12]. On CT-scan, the presence of phleboliths is pathognomonic [13]. Diffuse wall thickening, polypoidal intraluminal mass, exophytic mass, mucosal irregularities, and a mesenteric mass that involves adjacent bowel loops are findings seen on cross-sectional imaging. MRI shows a typical high signal on T2-weighted imaging and after gadolinium enhancement [13].

The differential diagnosis of colorectal hemangiomas includes benign and malignant masses, inflammatory and infectious disorders [13].

Treatments reported in the literature include surgical resection of the involved intestines, interventional embolization, and endoscopic treatment [14].

## CONCLUSION

Hemangiomas of the gastrointestinal tract are unusual benign tumors that most commonly present with bleeding. In the colon, they are more common in the rectosigmoid and may have the atypical appearance of a rigid annular lesion that mimics carcinoma. Most hemangiomas have typical nodular enhancement and

progressive filling. Therefore, dynamic imaging with either CT or MRI is immensely advantageous over single-phase imaging. Large hemangiomas may be associated with thrombosis, sclerosis, and calcification, and may be complicated by rupture. The interpreting radiologist should look for these findings and appropriately aid the referring clinician in the management of these patients.

## REFERENCES

1. Maestroni, U., Dinale, F., Frattini, A., & Cortellini, P. (2005). Ureteral hemangioma: a clinical case report. *Acta Bio-medica: Atenei Parmensis*, 76(2), 115-117.
2. Ojili, V., Tirumani, S. H., Gunabushanam, G., Nagar, A., Surabhi, V. R., Chintapalli, K. N., & Ryan, J. (2013). Abdominal hemangiomas: a pictorial review of unusual, atypical, and rare types. *Canadian Association of Radiologists Journal*, 64(1), 18-27. doi:10.1016/j.carj.2011.08.004
3. Varela, G., Cervera, J. A., Fernández, G., Rodríguez, N. A., Flores, J., & Robles, C. (2004). Hemangioma cavernoso del colon. Reporte de un caso y revisión de la literatura. *Rev Gastroenterol Mex*, 69(2), 95-99. PMID: 15757158.
4. Kumar, P., Khatri, A., Chowdhury, S., Mahajan, N., & Mathur, G. (2022). Incidental finding of intra-abdominal hemangioma in an infant presenting with intestinal obstruction: a case report. *World Journal of Pediatric Surgery*, 5(1), e000335. doi:10.1136/wjps-2021-000335.
5. Gómez R, D. M., Abello R, J. R., Cienfuegos R, A., Guzmán, G. A., Suárez C, J., León, F. A., ... & Varela M, M. J. (2018). A case report of cavernous Hemangioma as a cause of occult gastrointestinal Bleeding. *Revista colombiana de Gastroenterología*, 33(1), 68-73. <https://doi.org/10.22516/25007440.234>
6. Cura-Esquivel, I., Velasquez-Palacios, C., & Núñez-Ku, M. (2021). Gastrointestinal infantile hemangioma: A rare cause of digestive tract bleeding in children to consider. *Clinical Case Reports*, 9(9), e04722. <https://doi.org/10.1002/ccr3.4722>.
7. Varela, G., Cervera, J. A., Fernández, G., Rodríguez, N. A., Flores, J., & Robles, C. (2004). Hemangioma cavernoso del colon. Reporte de un caso y revisión de la literatura. *Rev Gastroenterol Mex*, 69(2), 95-99. PMID: 15757158.
8. Rodríguez Rodríguez, I., Borges Sandrino, R., Barroso Rosales, E., Santiesteban Pupo, W. E., Rodríguez Martínez, Y. G., & Casa de Valle Castro, M. (2014). Hemangioma cavernoso del mesosigmoide: informe de un caso y revisión de la bibliografía. *Revista Cubana de Cirugía*, 53(1), 90-98.
9. Zuniga, SR (1979). Colon hemangioma. *Rev Medica Hondur*, 47, 87-91.

10. O'Farril Anzures, R., Herrejón Camargo, J. M., Coyoli García, Ó., Martínez Cisneros, J. M., Toledo Caballero, C. R., & Jiménez González, A. (2012). Hemangioma cavernoso de rectosigmoides, enfermedad poco común y mal estudiada. *Cirujano general*, 34(1), 65-71.
11. Amati, A. L., Hecker, A., Schwandner, T., Ghanem, H., Holler, J., Reichert, M., & Padberg, W. (2014). A hemangioma of the sigmoid colon mesentery presenting as a retroperitonealtumor: a case report and review. *World journal of surgical oncology*, 12(1), 1-5. <https://doi.org/10.1186/1477-7819-12-79>
12. Mascarenhas, M., Morais, R., Teixeira, R., & Macedo, G. (2021). An unexpected colonic polyp: cavernous hemangioma. *Journal of the Korean Society of Coloproctology*. [Epub ahead of print] <https://doi.org/10.3393/ac.2020.00535.0076>
13. Levy, A. D., Abbott, R. M., Rohrmann Jr, C. A., Frazier, A. A., & Kende, A. (2001). Gastrointestinal hemangiomas: imaging findings with pathologic correlation in pediatric and adult patients. *American Journal of Roentgenology*, 177(5), 1073-1081.
14. Huang, Y., Xu, M., Xiao, X., Chen, G., Huang, Y., Dong, K., ... & Sun, S. (2021). An Investigation of Clinical Features and Exploration of Comprehensive Treatments for Colorectal Vascular Malformation in Children. DOI -10.21203/rs.3.rs-319610/v1