

Galen's Ampulla Aneurysm: A Case Report

Y. Bouktib^{1*}, L. Abdidine¹, D. Basraoui¹, H. Jalal¹

¹Radiology Department, Mother and Child Hospital Mohammed VI University Hospital, Faculty of Medicine and Pharmacy, Cadi Ayyad Marrakech University, Morocco

DOI: [10.36347/sjmcr.2023.v11i04.038](https://doi.org/10.36347/sjmcr.2023.v11i04.038)

| Received: 03.03.2023 | Accepted: 14.04.2023 | Published: 18.04.2023

*Corresponding author: Y. Bouktib

Radiology Department, Mother and Child Hospital Mohammed VI University Hospital, Faculty of Medicine and Pharmacy, Cadi Ayyad Marrakech University, Morocco

Abstract

Case Report

Introduction: Galen's vein aneurysm is a rare complex intracranial arteriovenous malformation, associating pseudo-aneurysmal dilation of Galen's ampulla with one or more arteriovenous fistulas. The prognosis is often poor, with high mortality and a risk of neurological sequelae. **Objective:** To support the role of imaging in the diagnosis, with illustration by two observations collected within our Radiopediatrics department of the CHU Mohammed VI of Marrakech, having benefited from a cerebral angio-scanner. **Case Report:** 1st case: is an 18-month-old infant with no particular history presenting macrocrania with generalized seizures. 2nd case: is also a 2-year-old infant, with the appearance of a vein in the suborbital groove for 6 months, with no other associated signs. 3rd patient is a 1-year-old infant with macrocrania with signs of HTIC. 4th case: 6-month-old boy, presents with HTIC syndrome. Objective cerebral CT in the first three patients: a rounded median mass, in the pineal region behind the 3rd ventricle, slightly hyperdense in spontaneous contrast; CT angiography proves the vascular nature of the lesion by showing intense and homogeneous enhancement after injection of PDC, associated with dilation of the venous sinuses, and moderate passive triventricular hydrocephalus by compression of the aqueduct of Sylvius. The fourth patient benefited from a transfontanellar ultrasound which objectified an anechoic interhemispheric fusiform structure presenting a vascular flow to the color Doppler. **Conclusion:** The aneurysmal malformation of the Vein of Galen (AVGM) is a rare vascular malformation, specific to children, discovered ante or post nately, in fact only corresponds to a venous dilation draining an arterio-venous malformation, whose system afferent arterial comes from the carotid system or the vertebro-basilar axis; it results from the absence of differentiation in the mature arterio-venous system, between 7 and 12 SA, of a primitive, median embryonic vein which drains the primitive choroid plexus.

Keywords: Galen's vein aneurysm, arteriovenous fistulas, Radiopediatrics, macrocrania, Sylvius.

Copyright © 2023 The Author(s): This is an open-access article distributed under the terms of the Creative Commons Attribution 4.0 International License (CC BY-NC 4.0) which permits unrestricted use, distribution, and reproduction in any medium for non-commercial use provided the original author and source are credited.

INTRODUCTION

Galen's vein aneurysm is a rare complex intracranial arteriovenous malformation, associating pseudo-aneurysmal dilation of Galen's ampulla with one or more arteriovenous fistulas. The prognosis is often poor, with high mortality and a risk of neurological sequelae.

OBJECTIVE

To support the role of imaging in the diagnosis, with illustration by two observations collected within our Radiopediatrics department of the CHU Mohammed VI of Marrakech, having benefited from a cerebral angio-scanner.

COMMENTS:

1. 1st case is an 18-month-old infant with no particular history presenting macrocrania with generalized seizures (Figure 1).
2. 2nd case is also a 2-year-old infant, with the appearance of a vein in the suborbital groove for 6 months, with no other associated signs (figure 2).
3. 3rd patient is a 1-year-old infant with macrocrania with signs of HTIC.
4. 4th case 6-month-old boy, presents with HTIC syndrome.

Objective cerebral CT in the first three patients: a rounded median mass, in the pineal region behind the 3rd ventricle, slightly hyperdense in spontaneous contrast; CT angiography proves the

vascular nature of the lesion by showing intense and homogeneous enhancement after injection of PDC, associated with dilation of the venous sinuses, and moderate passive triventricular hydrocephalus by compression of the aqueduct of Sylvius.

The fourth patient benefited from a transfontanellar ultrasound which objectified an anechoic interhemispheric fusiform structure presenting a vascular flow to the color Doppler (figure 3).

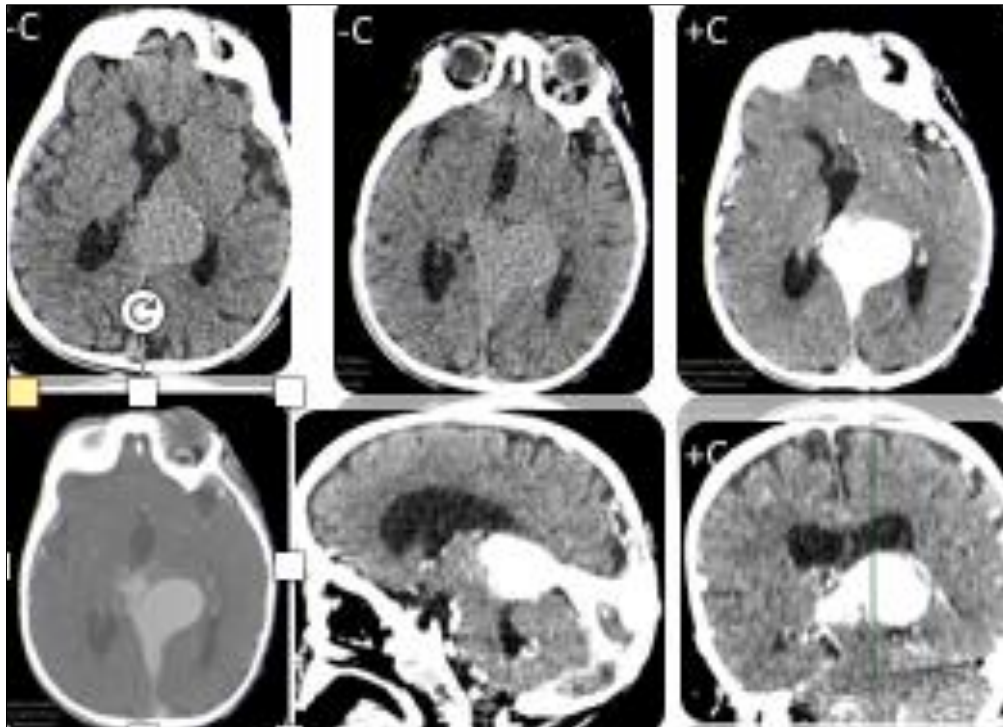


Figure 1: Brain CT in axial section and reconstructions Significant dilation of the vein of Galen spontaneously hyperdense, seat of fine peripheral calcifications, strongly enhancing after injection of PDC associated with multiple dilated vascular structures tortuous intraparenchymal cortical subcortical

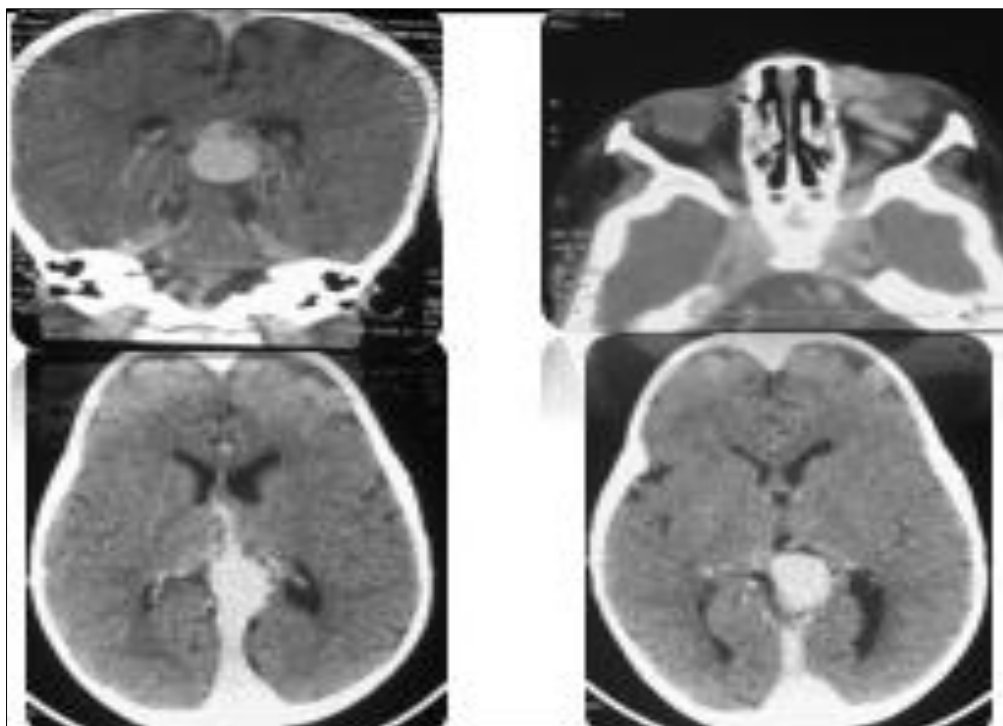


Figure 2: Brain CT in axial section and injected reconstructions. Cerebral vessel ectasia with aneurysm of Galen's vein

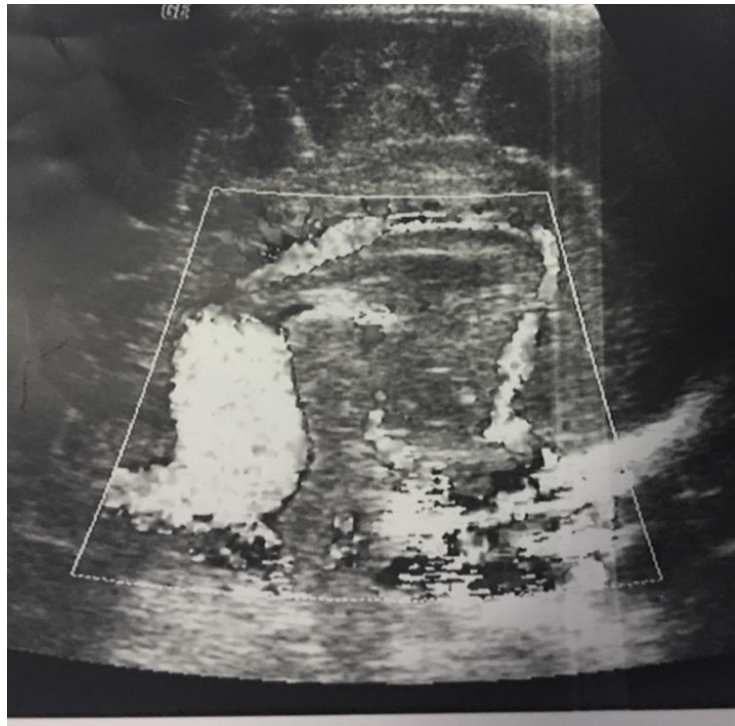


Figure 3: Transfontanellar ultrasound: objective an anechoic interhemispheric fusiform structure showing vascular flow on color Doppler

DISCUSSION/CONCLUSION

The aneurysmal malformation of the Vein of Galen (AVGM) is a rare vascular malformation, specific to children, discovered ante or post natally, in fact only corresponds to a venous dilation draining an arterio-venous malformation, whose system afferent arterial comes from the carotid system or the vertebro-basilar axis; it results from the absence of differentiation in the mature arterio-venous system, between 7 and 12 SA, of a primitive, median embryonic vein which drains the primitive choroid plexus.

This rare malformation induces hyper flow in the vein of Galen, responsible for hydrocephalus by reduction of CSF resorption or by compression of the aqueduct of sylvius.

Clinicment: revealing itself by:

- Right heart failure linked to the size of the shunt created by the fistula,
- A cranial murmur or macrocrania++,
- Rare generalized or focal convulsions: testifying to cerebral ischemia linked to cerebral venous congestion,
- Areas of focal brain cast are possible.

The radiological assessment initial consists in showing the lesion on the one hand, its possible effects on the parenchyma on the other hand type: defect of development, deformation, lesions anoxo ischemic, or hemorrhagic.

Ultrasound: Antenatal diagnosis (2nd to 3rd trimester) the aneurysmal dilation appears in the form of a pure anechoic formation, fusiform interhemispheric, subtentorial (above and behind the thalami), cross-sectional racket, color Doppler confirms the vascular nature

CT: Rounded mass of the pineal region behind V3, spontaneously hyper or isodense, intensely opacifies homogeneously after injection. It is associated with a dilation of the venous sinuses, and hydrocephalus most often, by compression of the aqueduct or the 3rd ventricle.

MRI: The highly dilated Vein of Galen empty of signal in the absence of thrombosis on all the sequences. Any parietal calcifications appear as signal-free areas (better individualized on CT). A possible spontaneous thrombosis or after treatment results in a disappearance of the vacuum of the signal which is replaced by a hypersignal in T1 and in T2 with a black ring of peripheral hemosiderin.

Angiography: Reserved for the therapeutic gesture.

Differential diagnosis: Pinealoma.

Treatment

- Symptomatic treatment, especially of heart failure.
- Endoscopic embolization.
- Surgical treatment.
- The occurrence of heart failure and dilation of the jugular veins is a very poor prognostic factor.

BIBLIOGRAPHY

- Antenatal diagnosis and management of an aneurysm of the vein of Galen, Review of the literature illustrated by a personal observation. *JGYN*, 34(6), 613-619.
- Galen's ampulla aneurysm (about 3 observations): thesis published in 2011 by dr mahdaoui omar, CHU ibn Rochd of Casablanca.
- Gaston, A., Ricolfi, F., & Houdart, E. Contribution of interventional neuroradiology in intracranial vascular pathology; neurosurgery campus.
- Hafsa, C., & Jerbi, S. (2005). Galen's ampulla aneurysm. About 2 observations. *Jrad*, 86(10), 1523.