

Spontaneous Catheter Fracture with Embolization: A rare complication of Totally Implantable Subclavian Venous Catheter

Y. El Badri^{1*}, A. L'kbir¹, B. Boutakioute¹, A. El Hajjami¹, M. Ouali¹, N. Cherif Idrissi Ganouni¹¹Radiology Department, ARRAZI Hospital, Mohamed VI University Hospital, Cadi Ayyad University, Marrakesh, MoroccoDOI: [10.36347/sjmcr.2023.v11i04.063](https://doi.org/10.36347/sjmcr.2023.v11i04.063)

| Received: 01.03.2023 | Accepted: 17.04.2023 | Published: 25.04.2023

*Corresponding author: Y. El Badri

Radiology Department, ARRAZI Hospital, Mohamed VI University Hospital, Cadi Ayyad University, Marrakesh, Morocco

Abstract

Case Report

Totally Implantable venous access insertion has become routinely involved in the treatment of patients in oncology, However, certain complications are associated with the use of these devices: catheter migration with embolization, pinch-off sign. We report a case of successful extraction of an embolized distal portion of the Catheter from left pulmonary artery.

Keywords: Catheter fracture, pulmonary embolization, percutaneous intervention.

Copyright © 2023 The Author(s): This is an open-access article distributed under the terms of the Creative Commons Attribution 4.0 International License (CC BY-NC 4.0) which permits unrestricted use, distribution, and reproduction in any medium for non-commercial use provided the original author and source are credited.

INTRODUCTION

Totally Implantable ports (PAC) is a system placed directly under the skin, allowing prolonged and repeated access to the central venous system (chemotherapy, multiple transfusions, prolonged antibiotic treatment, etc.), while protecting the peripheral venous system [1]. Before any use, the insertion of the catheter must be systematically checked by a Chest X-ray performed after the insertion. This X-ray allows to look for immediate, perioperative complications: catheter fracture, infection, pinch-off sign.

Pinch-off sign is a rare complication describing a compression of the catheter between clavicle and the first rib, particularly when using the subclavian venous which causes the catheter fracture. We report a case of successful extraction of an embolized distal portion of the Catheter from the left pulmonary artery.

CASE REPORT

We report a case of a 14 year old patient, followed for an acute T lymphoblastic leukemia under chemotherapy. He had benefited from the insertion of a

totally Implantable ports in the left subclavian vein. A chest X-ray after the insertion had not revealed any abnormality with good positioning of its distal tip.

Catheter fracture was discovered fortuitously during a casual chest X-ray, which showed the migration of the distal fragment towards the left pulmonary artery (Figure 1). The catheter was successfully removed via a percutaneous right femoral vein approach using a Lasso guide.

Procedure

The patient was referred to the interventional radiology department to percutaneously retrieve the embolized catheter part. The procedure was started with the insertion of a 8-French (F) femoral sheath into the right femoral vein, then introduced a JR4 6F into the left pulmonary artery using 0.025" hydrophilic guide wire. The JR4 6F was changed to 6-F pigtail catheter which was advanced to the pulmonary artery. The embolized material was captured at midportion, and pulled back by a Lasso guide. The fractured catheter was successfully removed without complication. Local hemostasis was easily achieved by manual compression (Figure 2 & 3).

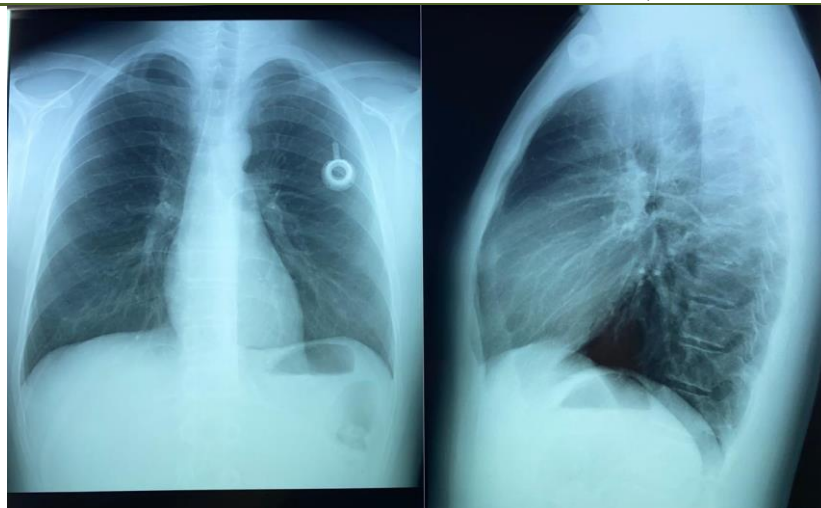


Figure 1: Chest X-ray showing the catheter fractured and embolized to the left Pulmonary Artery

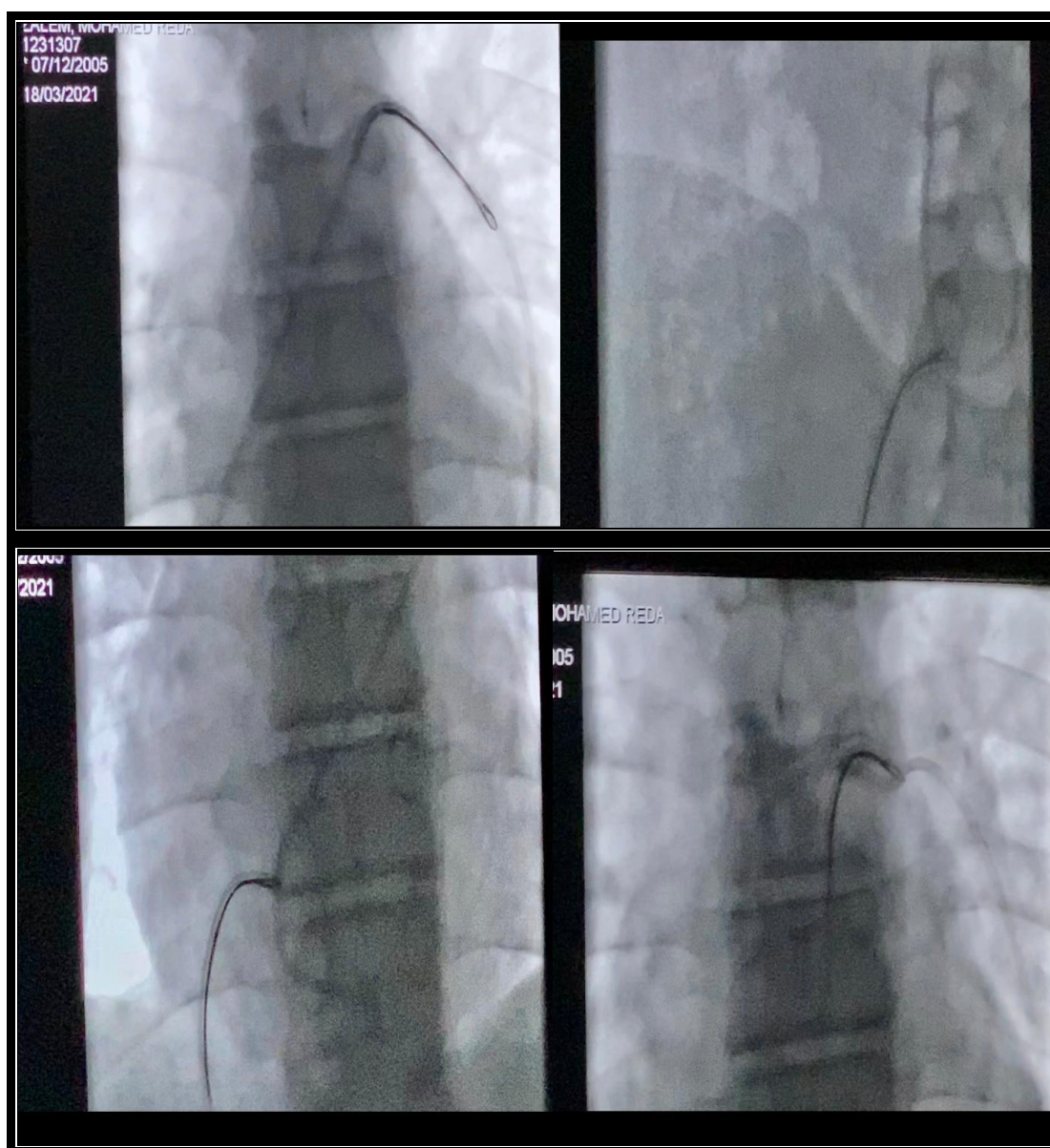


Figure 2: The different steps of the fishing for lines. Sequence of fluoroscopic images of the chest showing the retrieval of embolized tip of the fractured catheter at the level of the left pulmonary artery

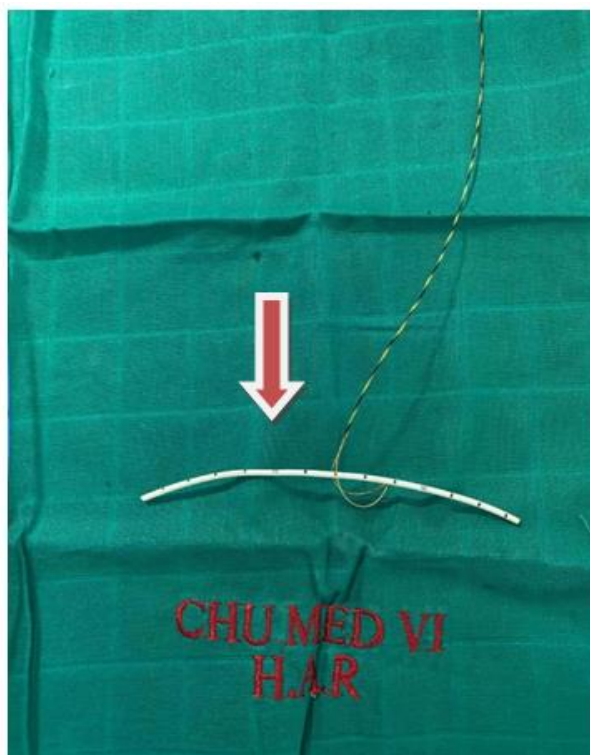


Figure 3: Images of the embolized catheter (arrow)

DISCUSSION

Catheter fracture is a relatively rare complication but it can be avoided, its incidence is 0.9 to 1.7%. It is often revealed by a thoracic discomfort, palpitations, or even by a pulmonary embolism. A sign in asymptomatic patients that can be alarming is the resistance during the injection of the drug. Certain factors contribute to the occurrence of a fracture, notably the use of inappropriate material, traumatic sectioning during insertion or extraction of the catheter, alteration of the mechanical properties of the catheter, and also the pinch off syndrome [2].

The catheter can become detached and migrate with three types of migration: proximal fracture of the catheter towards the right ventricle, migration of the distal tip into the pulmonary parenchyma. The distal tip may also migrate into the pulmonary arteries, exposing it to pulmonary embolism due to its thrombogenic nature. Cheng *et al.* noted that catheter fragments that embolize more distally to the pulmonary arteries are shorter than those that migrate to the central veins or to the cardiac chambers [3].

Imaging plays a crucial role in the diagnosis and management of this complication. Plain radiography can make the diagnosis and be revealing in asymptomatic patients by showing a malposition of the PAC. CT pulmonary angiogram gives a better semiological characterization by specifying the site of the migrated tip, by analysing the permeability of the

arterial branches and by evaluating the impact on the pulmonary parenchyma [1, 2].

Several techniques for percutaneous catheter retrieval are described in the literature. The extraction of the embolized fragment using endovascular catheterization techniques is often successful [4, 5], in our case we used the lasso guides. Most teams insist on referring these patients to an interventional radiology or cardiology unit since the success rate of percutaneous removal of the embolized fragment is well over 90% [6, 7]. Nevertheless, in some cases, we can recall a more conservative attitude by leaving the sectioned fragment in place [8]. Moreover, two cases reported in the literature were able to tolerate the presence of the distal tip of the catheter in the pulmonary arteries for more than ten years without any complications [9].

CONCLUSION

Totally Implantable ports plays an important role in the management of cancer patients by providing them with long-term venous access. However, the insertion of these devices is not without risk, making it essential for the operator to be very experienced and to handle the sites properly. Catheter fracture is a rare complication that can be well managed by percutaneous removal with a high success rate.

REFERENCES

1. Cassidy Jr, F. P., Zajko, A. B., Bron, K. M., Reilly Jr, J. J., Peitzman, A. B., & Steed, D. L. (1987).

- Noninfectious complications of long-term central venous catheters: radiologic evaluation and management. *American Journal of Roentgenology*, 149(4), 671-675.
2. Biffi, R., Corrado, F., De Braud, F., De Lucia, F., Scarpa, D., Testori, A., ... & Andreoni, B. (1997). Long-term, totally implantable central venous access ports connected to a Groshong catheter for chemotherapy of solid tumours: Experience from 178 cases using a single type of device. *European Journal of Cancer*, 33(8), 1190-1194.
 3. Cheng, C. C., Tsai, T. N., Yang, C. C., & Han, C. L. (2009). Percutaneous retrieval of dislodged totally implantable central venous access system in 92 cases: experience in a single hospital. *European journal of radiology*, 69(2), 346-350.
 4. Gallieni, M., Pittiruti, M., & Biffi, R. (2008). Vascular access in oncology patients. *CA: a cancer journal for clinicians*, 58(6), 323-346.
 5. Faraj, W., Zaghal, A., El-Beyrouthy, O., & Kutoubi, A. (2010). Complete catheter disconnection and migration of an implantable venous access device: the disconnected cap sign. *Annals of Vascular Surgery*, 24(5), 692-e11.
 6. Onal, A. H. M. E. T., Coskun, B., Karabulut, R., Ilgit, E. R. H. A. N., Türkyılmaz, Z., & Sönmez, K. (2012). Interventional radiological retrieval of embolized vascular access device fragments. *Diagnostic and Interventional Radiology*, 18(1), 87-91.
 7. Wang, P. C., Liang, H. L., Wu, T. H., Huang, J. S., Lin, Y. H., Huang, Y. L., ... & Pan, H. B. (2009). Percutaneous retrieval of dislodged central venous port catheter: experience of 25 patients in a single institute. *Acta Radiologica*, 50(1), 15-20.
 8. Hayari, L., Yalonetsky, S., & Lorber, A. (2006). Treatment strategy in the fracture of an implanted central venous catheter. *Journal of Pediatric Hematology/Oncology*, 28(3), 160-162.
 9. Reynen, K. (1993). 14-year follow-up of central embolization by a guide wire. *New England Journal of Medicine*, 329(13), 970-971.