

Uterine Rhabdomyosarcoma: A Case Report and Literature Review

Ouassima EL Kadiri^{1*}, Samiha Sabri¹, Raja Ousalm¹, Salma Chabli¹, Ibtissam Zrara Touiti², Mouna Darfaoui¹, Abdelhamid El Omrani¹, Mouna Khouchani¹

¹Radiation Oncology Department, Mohammed VI Teaching Hospital, Marrakesh, Morocco

²Al Fadle Laboratory of Pathological Anatomy and Cytology, Marrakesh, Morocco

DOI: [10.36347/sjmcr.2023.v11i06.035](https://doi.org/10.36347/sjmcr.2023.v11i06.035)

Received: 02.04.2023 | Accepted: 11.05.2023 | Published: 14.06.2023

*Corresponding author: Ouassima El Kadiri

Radiation Oncology Department, Mohammed VI Teaching Hospital, Marrakesh, Morocco

Abstract

Case Report

Rhabdomyosarcoma (RMS) is a malignant neoplasm that originates from undifferentiated myogenic progenitor cells. It is predominantly a pediatric disease, and its occurrence in adults is exceedingly rare. Adult primary RMS of gynecologic origin is an uncommon phenomenon, and the cervix is the most frequently involved site. The incidence of adult primary uterine RMS is extremely scarce. Herein, we present the case of primary uterine RMS in a 59-year-old Moroccan postmenopausal woman who presented to clinic attention with a two-month history of metrorrhagia. The patient received a multimodal therapy comprising a combination of surgery, chemotherapy and radiotherapy with a good clinical and radiological evolution.

Keywords: Rhabdomyosarcoma, metrorrhagia, malignancy, corpus uteri, radiotherapy.

Copyright © 2023 The Author(s): This is an open-access article distributed under the terms of the Creative Commons Attribution 4.0 International License (CC BY-NC 4.0) which permits unrestricted use, distribution, and reproduction in any medium for non-commercial use provided the original author and source are credited.

INTRODUCTION

Rhabdomyosarcoma (RMS) is a high-grade, malignant tumor of mesenchymal origin in which cancer cells have a propensity for myogenic differentiation. It is included in the group of small blue, round cell tumors of childhood along with neuroblastoma, lymphoma, and primitive neuroectodermal tumors (PNET) [1,2]. Primary RMS of the uterus in adults is rare. Historically, the first case to arise in a postmenopausal woman was documented by Anderson and Ödmansson in 1869 [3].

To date, data on clinicopathological features of this malignancy are limited in the literature compared to most other gynecological tumors. In this study, we present an observation of a uterine carcinosarcoma in a post-menopausal woman, where the RMS represent its heterologous component, through which we specify its epidemiological, clinical and radiological characteristics as well as its therapeutic management.

CASE PRESENTATION

We present here a case of a 59-year-old female patient, nulliparous, menopausal, with a history of thyroidectomy on levothyroxine 6 years ago, who was admitted to the gynecology department owing to metrorrhagia for more than 2 months without other associated signs. The patient was referred to us after

total hysterectomy, bilateral salpingo-oophorectomy, and lymphadenectomy. The study of the surgical specimen was in favour of a double component malignant tumour proliferation whose morphological aspect reminds firstly a carcinosarcoma, infiltrating less than 50% of the myometrial wall, without neoplastic vascular emboli. On immunohistochemical study, the epithelial cells were positive for keratin. The mesenchymal cells were positive for vimentin, mycogenin, desmin, CD10. In total, the appearance was of a uterine carcinosarcoma with a rhabdomyosarcomatous differentiation. The lymph node dissection was negative on both sides.

The radiological assessment hasn't revealed any distant metastases. The tumor was classified as stage IA according to the FIGO classification. Postoperative MRI showed no tumor residue. The patient then received 4 adjuvant cycles of chemotherapy. The regimen used was paclitaxel at a dose of 175 mg/m² and carboplatin AUC 5. The patient had 4 episodes of grade 2 neutropenia between the cycles, which had led to delay subsequent chemotherapy doses. The total duration of chemotherapy was 3.5 months. The evaluation CT TAP was without abnormalities. The patient then underwent pelvic radiotherapy with 25 fractions of 1.8 Gy. Due to the unavailability of brachytherapy, an additional complement by external radiotherapy was performed on

the vagina with 8 fractions of 2 Gy. The evolution was favorable with a follow-up of 1.5 years.

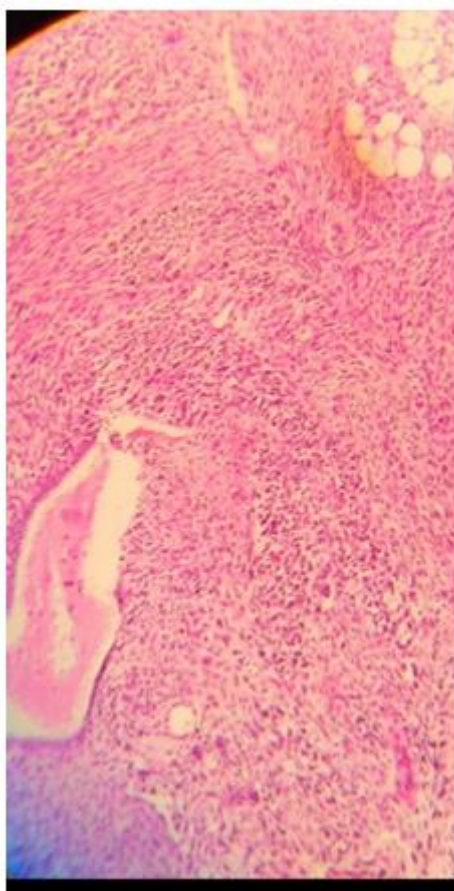


Figure 1: carcinosarcoma with rhabdomyosarcomatous differentiation HEx40TMMM

DISCUSSION

RMS is an aggressive mesenchymal tumor whose phenotype recapitulates striated skeletal muscle. It is most commonly diagnosed in the pediatric population, occurring predominantly in patients younger than 10 years old, and tends to originate in the head, neck, limbs and urinary tract [3]. Uncommon in older patients, RMS accounts for less than 4% of all adult soft tissue sarcomas, and when occurring in this patient population most often develops in the deep soft tissue of the limbs [4,5].

Primary RMS of the uterus in adults is exceedingly rare. It occurs most commonly in the cervix, followed by the corpus uteri, where it may appear as a “pure” tumor or more commonly as a constituent of uterine carcinosarcoma (rhabdomyosarcomatous component of the mesenchymal element) [3,6].

The WHO classifies rhabdomyosarcomas into four subtypes: embryonal, alveolar, pleomorphic and spindle cell/sclerosing. The polypoidal subtype of

embryonal RMS, known as botryoid RMS, occurs beneath the mucosa of internal organs, typically involving the urinary bladder [7]. The most common histologic variant of RMS of gynecologic origin previously reported in the adult and pediatric literature is embryonal, with the majority being botryoid [4,8,9].

It falls into the category of small round blue cell tumors for containing relatively uniform, round or slightly spindled cells with dark nuclei and inconspicuous nucleoli. Rhabdomyoblasts (elongated or globular cells with eosinophilic cytoplasm) are found occasionally [10].

Biopsies, frozen sections, and immunohistochemistry are important workups for definitive diagnosis of RMS given the difficult nature of this condition [11]. However, physicians should be aware that biopsies from the superficial tumor may not be able to capture the extent of the tumor due to the extensive necrosis and inflammation usually present. Instead, it is important to consider larger excisional biopsies to capture the tumor, which may need to be performed under general anesthesia. Commonly used muscle antigen markers for diagnosis of RMS include myogenin, MyoD1, desmin, and sarcomeric actin [12].

We consider that immunohistochemical support is necessary for a definitive diagnosis of rhabdomyosarcoma. The neoplasm we describe was positive with desmin. This is a marker of muscle and does not help distinguish between a rhabdomyosarcoma and a leiomyosarcoma. However, smooth muscle actin (a marker of smooth muscle differentiation) was negative while sarcomeric actin, myogenin, desmin and myoD1 (all skeletal muscle markers) were positive. This provides unequivocal evidence that the neoplasm in this report exhibit skeletal muscle differentiation.

There are no symptoms that are pathognomonic for RMS, so it is not possible to distinguish it clinically on its own. In the female genital tract, RMS most commonly presents with a polypoid mass protruding from the vagina and/or cervix accompanied by vaginal bleeding [13]. In the case reported here, the clinical symptomatology was isolated postmenopausal metrorrhagia

Imaging, particularly MRI, has a developing role in the assessment of the malignancy, being useful in the evaluation of the pelvic mass at presentation, adequate staging (assessment of invasion depth, spread to adjacent organs and lymph nodes), and also providing differentiation from the more common endometrial carcinoma. The CT TAP completes the remote extension assessment. The PET-scan has no indication in first intention [14,15].

The RMS's treatment is similar to carcinoma's if it is diagnosed in the context of carcinosarcoma.

Indeed, uterine carcinosarcoma is staged according to the FIGO and the Tumor-Nodes-Metastasis (TNM) staging systems for endometrial cancer and is generally treated along a gynecological carcinoma rather than a sarcoma paradigm [16].

Surgical debulking has gradually become the primary approach for both accurate staging and treatment of stage I-III malignancies, whereas more conservative surgical approaches can be offered to patients with advanced disease for symptom palliation. However, outcomes after primary surgery treatment alone have been poor with a high recurrence and death rate even in early-stage disease. Adjuvant therapy, including systemic chemotherapy, radiation therapy, or both, has been significant consideration in the management of the uterine carcinosarcoma after primary surgical treatment [17]. According to 2023 NCCN guidelines, combined chemotherapy is recommended for uterine carcinosarcoma even in the early stage. The first choice is carboplatin and paclitaxel combined chemotherapy. RT should be considered if both high-grade epithelial components and sarcoma are dominant (>50% of sarcoma component in uterine tumor).

RT is directed at sites of known or suspected tumor involvement and may include EBRT and/or brachytherapy. Imaging is required to assess locoregional extent and to rule out distant metastases before administration of RT. In general, EBRT is directed to the pelvis with or without the para-aortic region. External-beam doses for microscopic disease should be 45–50 Gy. For gross nodal disease, boost should be considered to 60–65 Gy while respecting normal tissue constraints. Concerning brachytherapy, the dose depends on the use of EBRT. 7 Gy x 3 fractions prescribed at a depth of 0.5 cm from the vaginal surface is a regimen used by many,

The outcome of uterine RMS is very poor with most patients presenting with widespread disease at time of diagnosis. A study by Gerber *et al* investigated 148 adult patients with RMS of various sites over a 10-year period. They found a five-year overall survival of 45% for non-metastatic patients and 26% for metastatic patients, and treatment failure correlated with a poor prognosis [18].

CONCLUSION

Although our understanding of this disease is improving, more research is needed to better delineate prognostic and predictive biomarkers for this tumor type in order to help guide treatment approaches. Although clinical trials are sorely needed in order to most effectively compare therapies, prospective studies are difficult due to the rare nature of this tumor type. Future research will likely require multi-institutional and collaborative approaches to better understand this important gynecologic malignancy.

REFERENCES

1. Dasgupta, R., Fuchs, J., & Rodeberg, D. (2016). Rhabdomyosarcoma. *Seminars in Pediatric Surgery*, 25(5), 276–283.
2. Skapek SX, Ferrari A, Gupta AA, Lupo PJ, Butler E, Shipley J, Barr FG, Hawkins DS. (2019). Rhabdomyosarcoma. *Nature Reviews Disease Primers*, 5(1)
3. Pinto, A., Kahn, R. M., Rosenberg, A. E., Slomovitz, B., Quick, C. M., Whisman, M. K., & Huang, M. (2018). Uterine rhabdomyosarcoma in adults. *Human Pathology*, 74, 122–128.
4. Hawkins WG, Hoos A, Antonescu CR., Urist, M. R., Leung, D. H. Y., Gold, J. S., Woodruff, J. M., Lewis, J. J., Brennan, M. F. (2001). Clinicopathologic analysis of patients with adult rhabdomyosarcoma. *Cancer*, 91(4), 794–803.
5. Toro J. R., Travis L. B., Wu, H., Zhu, K., Fletcher, C. D., Devesa, S. S. (2006). Incidence patterns of soft tissue sarcomas, regardless of primary site, in the surveillance, epidemiology and end results program, 1978-2001: An analysis of 26,758 cases. *International Journal of Cancer* 119(12), 2922-2930.
6. Ferguson, S.E., Gerald, W. L., Barakat, R. R., Chi, D. S., Soslow, R. A. (2007). Clinicopathologic Features of Rhabdomyosarcoma of Gynecologic Origin in Adults. *The American Journal of Surgical Pathology*, 31(3), 382-389.
7. World Health Organization, WHO., Fletcher, C. (Ed.), Bridge, JA. (Ed.), Hogendoorn, PCW. (Ed.), & Mertens, F. (Ed.) (2013). *WHO Classification of Tumours of Soft Tissue and Bone: WHO Classification of Tumours, vol. 5.* (4th ed.) World Health Organization.
8. Arndt, C. A., Donaldson, S. S., Anderson, J. R., Andrassy, R. J., Laurie, F., Link, M. P., Raney, R. B., Maurer, H. M., & Crist, W. M. (2001). What constitutes optimal therapy for patients with rhabdomyosarcoma of the female genital tract?. *Cancer*, 91(12), 2454–2468.
9. La Quaglia, M. P., Heller, G., Ghavimi, F., Casper, E. S., Vlamis, V., Hajdu, S., & Brennan, M. F. (1994). The effect of age at diagnosis on outcome in rhabdomyosarcoma. *Cancer*, 73(1), 109–117.
10. Li, R. F., Gupta, M., McCluggage, W. G., & Ronnett, B. M. (2013). Embryonal rhabdomyosarcoma (botryoid type) of the uterine corpus and cervix in adult women: report of a case series and review of the literature. *The American journal of surgical pathology*, 37(3), 344–355.
11. Li, K., Davis, G., Wittenberg, C., & Abidi, A. (2022). Rhabdomyosarcoma-Induced Uterine Inversion. *Case reports in obstetrics and gynecology*, 2022, 1361803.
12. da Silva, B. B., Dos Santos, A. R., Bosco Parentes-Vieira, J., Lopes-Costa, P. V., & Pires, C. G. (2008). Embryonal rhabdomyosarcoma of the uterus associated with uterine inversion in an adolescent: a case report and published work

- review. *The journal of obstetrics and gynaecology research*, 34(4 Pt 2), 735–738.
13. Dural, O., Kebudi, R., Yavuz, E., Yilmaz, I., Buyukkapu Bay, S., Schultz, K. A. P., & Hill, D. A. (2020). DICER1-Related Embryonal Rhabdomyosarcoma of the Uterine Corpus in a Prepubertal Girl. *Journal of pediatric and adolescent gynecology*, 33(2), 173–176.
 14. Guy, J., Trone, J., Casteillo, F., Forest, F., Pacaut, C., Moncharmont, C., Espenel, S., Vallard, A., Escure, J. L., Collard, O., Peoc'h, M., & Magné, N. (2014). Carcinosarcomes gynécologiques: revue générale et principes de prise en charge. *Bulletin Du Cancer*, 101(7-8), 760–764.
 15. Santos, P., & Cunha, T. M. (2015). Uterine sarcomas: clinical presentation and MRI features. *Diagnostic and interventional radiology (Ankara, Turkey)*, 21(1), 4–9.
 16. Amin, M. B., Greene, F. L., Edge, S. B., Compton, C. C., Gershenwald, J. E., Brookland, R. K., Meyer, L., Gress, D. M., Byrd, D. R., & Winchester, D. P. (2017). The Eighth Edition AJCC Cancer Staging Manual: Continuing to build a bridge from a population-based to a more "personalized" approach to cancer staging. *CA: a cancer journal for clinicians*, 67(2), 93–99.
 17. Zhao, F., Tan, P., Wang, C., Ji, X., & Chen, A. (2021). Effect of adjuvant therapy on the prognosis in stage I/II uterine carcinosarcoma: A meta-analysis. *The journal of obstetrics and gynaecology research*, 47(7), 2473–2480.
 18. Gerber, N. K., Wexler, L. H., Singer, S., Alektiar, K. M., Keohan, M. L., Shi, W., Zhang, Z., & Wolden, S. (2013). Adult rhabdomyosarcoma survival improved with treatment on multimodality protocols. *International journal of radiation oncology, biology, physics*, 86(1), 58–63.